

Successful autologous stem cell collection with filgrastim and plerixafor after long-term lenalidomide therapy for multiple myeloma

Rishi Agarwal,¹ Muneer H. Abidi^{2,3}

¹UT Houston MD Anderson Cancer Center, Houston, TX; ²Karmanos Cancer Institute, Detroit, MI; ³Wayne State University, Detroit, MI, USA

Abstract

Novel agents such as lenalidomide have demonstrated responses similar to high-dose melphalan and autologous stem cell transplant in multiple myeloma. For patients who are started on lenalidomide, it is advisable to collect stem cells early if future transplant is contemplated. We are reporting a patient who underwent successful stem cell mobilization after 68 cycles of lenalidomide. A 60-year old male presented with back pain. He was diagnosed with stage IIA, IgA multiple myeloma. He was enrolled in a clinical trial and was randomized to receive lenalidomide plus dexamethasone. He received a total of 68 cycles of lenalidomide before progressing. He underwent mobilization of stem cells using filgrastim and plerixafor. He underwent successful stem cell transplant. Longer duration of lenalidomide adversely affects stem cell mobilization. To the best of our knowledge, there has been no other case reported in which stem cell mobilization was feasible after such a long (68 months) duration of uninterrupted lenalidomide therapy.

Introduction

Initial therapy for multiple myeloma (MM) patients using novel agents like thalidomide, lenalidomide and bortezomib have demonstrated responses similar to high-dose melphalan (HDM) and autologous stem cell transplant (ASCT). This has led to some skepticism about the utility of HDM with ASCT as first-line treatment for multiple myeloma.¹⁻³ Recently reported clinical trials using novel drug combinations as induction therapy have suggested that HDM further augments the response seen with initial treatment.⁴ HDM with ASCT is currently considered the standard first-line treatment for transplant eligible patients.^{4,5} For patients who are started on lenalidomide, it is advisable to collect stem cells early if ASCT is contemplated

in the near future.⁶ With the role of salvage ASCT being defined as an important therapeutic option for relapse/refractory MM, it is advisable to cryopreserve backup stem cells so these patients can receive more than one ASCT.⁷

The immunomodulatory drug lenalidomide is a thalidomide derivative that was approved by the US Food and Drug Administration for use in combination with dexamethasone for previously treated multiple myeloma. Lenalidomide in combination with dexamethasone has shown superiority over dexamethasone alone as a first-line therapy in newly diagnosed multiple myeloma.^{8,9} Myelosuppression is one of the most common side effects of lenalidomide therapy. Based on retrospective reviews, it was observed that lenalidomide could adversely affect the stem cell mobilization resulting in lower dose of CD 34⁺ cell collection for ASCT.¹⁰⁻¹³ Various studies have shown that the negative effect of lenalidomide on stem cell collection is probably related to the cumulative dose of lenalidomide, and risk of failure of stem cell mobilization increases with the duration of lenalidomide exposure.^{10,11}

We report a patient who underwent successful stem cell mobilization after 68 cycles of lenalidomide therapy. To the best of our knowledge, there has been no other case reported in which stem cell mobilization was feasible after such a long duration of uninterrupted lenalidomide therapy.

Case Report

A 60-year old male with a past medical history of hypertension presented with a 2-month history of new onset upper back pain. Initial work up showed quantitative IgA level of 7,850 mg/dL. After a complete work up, he was diagnosed with Durie-Salmon stage IIA, IgA multiple myeloma and was started on lenalidomide plus dexamethasone as part of a double blind, randomized clinical trial evaluating lenalidomide plus dexamethasone compared to placebo plus dexamethasone for newly diagnosed multiple myeloma. After 3 cycles of dexamethasone (40 mg/day on Days 1-4, 9-12 and 17-20) plus lenalidomide (25 mg/day for 28 days), he was moved onto maintenance therapy with dexamethasone (40 mg/day on Days 1-4 and 15-18) plus lenalidomide (25 mg/day for 21 days).

The patient was compliant with both lenalidomide and dexamethasone. Dexamethasone, originally given at 40 mg for four days every two weeks, was changed to 20 mg for four days every two weeks after approximately one year of starting therapy. This dose was further decreased to 20 mg/week after the unblinding of the protocol at 18 months of therapy. Dexamethasone was

Correspondence: Rishi Agarwal, Investigational Cancer Therapeutics, UT Houston MD Anderson Cancer Center, Houston, Texas, 77030, USA. Tel. +1.713.794.1834 - Fax: +1.713.792.3535. E-mail: ragarwal1@mdanderson.org

Key words: ASCT, lenalidomide, filgrastim, plerixafor.

Contributions: RA carried out the literature search, reviewed the chart and wrote the manuscript; MA is the treating physician and supervised RA through the entire process.

Conflict of interests: MA has received a research grant and has collaborated as part of the Speakers' Bureau of Millennium Pharmaceuticals. RA has no conflicts of interest to declare.

Received for publication: 19 September 2012.

Revision received: 25 October 2012.

Accepted for publication: 8 November 2012.

This work is licensed under a Creative Commons Attribution NonCommercial 3.0 License (CC BY-NC 3.0).

©Copyright R. Agarwal and M.H. Abidi, 2012

Licensee PAGEPress, Italy

Hematology Reports 2012; 4:e26

doi:10.4081/hr.2012.e26

later discontinued after 50 months and 24 days of therapy due to mood changes and insomnia. During this entire therapy period, adverse events included grade 1 diarrhea and neuropathy; these were treated symptomatically.

The patient was closely monitored throughout this therapy and his multiple myeloma stayed biochemically stable until he had received a total 68 cycles of lenalidomide (68 months). At 68 months of therapy, he demonstrated signs of progression; quantitative IgA increased to 529 mg/dL, SPEP/immunofixation showed IgA kappa of 0.42 g/dL (Figure 1), kappa to lambda ratio was 3.06, and bone marrow biopsy showed 67.8% plasma cells. Lenalidomide was discontinued and he was evaluated for HDM with ASCT.

He underwent mobilization of stem cells using filgrastim 16 mcg/kg/day for four days and plerixafor 0.24 mg/kg administered on Day 4 (no peripheral CD34 count checked on Day 4). The peripheral CD 34 cell count was 44.94/ μ L on Day 5. Total CD 34 cells collected were 6.37 million per kg of actual body weight. The stem cells were collected in one day. The total volume of blood processed was 28,674 milliliters. Subsequently, he underwent stem cell transplant with melphalan 140 mg/m² because of his low GFR (55 mL/min/1.73 m²). His neutrophils and platelets successfully engrafted post ASCT.

Discussion and Conclusions

Lenalidomide with dexamethasone has shown promising activity in refractory multiple myeloma as well as in newly diagnosed multiple myeloma.⁸⁻¹⁰ The ease of oral administration and the impressive overall response is leading to widespread use of this combination. Multiple studies have shown that lenalidomide has a myelosuppressive effect that could adversely affect the stem cell mobilization and collection. Failure of stem cell mobilization has been observed with prolonged exposure and when single agent G-CSF is used as the mobilizing agent. On the other hand, use of non-G-CSF mobilization factors has been shown to overcome the myelosuppressive effect of lenalidomide. Longer duration of lenalidomide therapy has been shown to worsen the adverse effect of lenalidomide on stem cell mobilization.^{10,11,13,14}

Due to the lack of evidence from randomized trials, International Myeloma Working Group (IMWG) expert consensus recommends early stem cell mobilization in patients treated with lenalidomide induction therapy when future ASCT is being contemplated. In patients who had received less than 4 cycles and are under 65 years of age, G-CSF alone could be used as a mobilizing agent, while in patients who have received more than 4 cycles, use of cyclophosphamide in combination with G-CSF could be considered.⁶ mSMART guidelines suggest that the impact of lenalidomide on stem cell collection could be overcome by early collection of stem cells (after 4 cycles), or by using mobilizing agents, such as chemotherapy and granulocyte colony stimulating factors or newer agents like plerixafor which is a reversible antagonist of the CXCR4 receptor.⁴ Use of low dose-cyclophosphamide (1.5 g/m²) has been more frequently associated with mobilization failure and intermediate-dose cyclophosphamide (3-4 g/m²) has been shown to provide more robust mobilization compared to low-dose cyclophosphamide (1.5 g/m²).¹⁵ Plerixafor in combination with granulocyte colony stimulating factors has been shown to improve stem cell yield in patients previously treated with lenalidomide.^{16,17} Use of plerixafor/G-CSF and cyclophosphamide/G-CSF has shown similar clinical outcomes but it is easier to predict collection outcome with plerixafor/G-CSF and this combination also has the advantage of reducing the risk of unscheduled hospital admissions.¹⁸ We decided to use plerixafor/G-CSF for our patient because of its greater predictability, the reduced risk of neutropenia, and to avoid the prolonged use of neupogen that is usually associated with cyclophosphamide.

Prolonged use of lenalidomide adversely affects stem cell collection, but this can be overcome by using mobilization agents, as

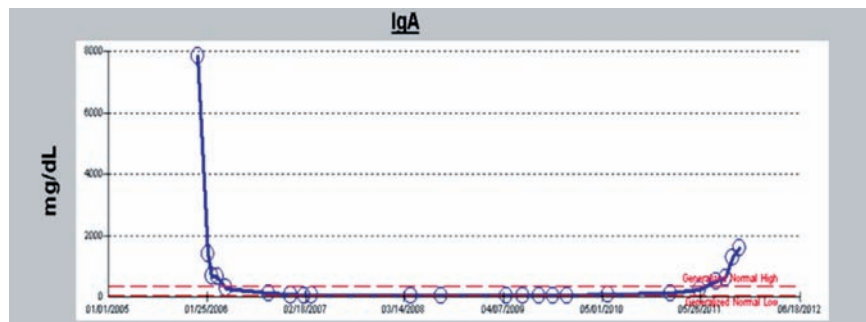


Figure 1. Trend of Immunoglobulin A (IgA) monoclonal protein during treatment.

seen with our patient. To the best of our knowledge, our patient had the longest exposure (68 months) to lenalidomide before a successful stem cell collection on the first attempt using filgrastim and plerixafor. The role of plerixafor in the mobilization of stem cells in patients heavily pre-treated with lenalidomide needs to be explored in clinical trials.

References

1. Kumar SK, Rajkumar SV, Dispenzieri A, et al. Improved survival in multiple myeloma and the impact of novel therapies. *Blood* 2008;111:2516-20.
2. Lacy MQ, Gertz MA, Dispenzieri A, et al. Long-term results of response to therapy, time to progression, and survival with lenalidomide plus dexamethasone in newly diagnosed myeloma. *Mayo Clin Proc* 2007;82:1179-84.
3. Rajkumar SV, Rosinol L, Hussein M, et al. Multicenter, randomized, double-blind, placebo-controlled study of thalidomide plus dexamethasone compared with dexamethasone as initial therapy for newly diagnosed multiple myeloma. *J Clin Oncol* 2008;26:2171-7.
4. Kumar SK, Mikhael JR, Buadi FK, et al. Management of newly diagnosed symptomatic multiple myeloma: updated Mayo Stratification of Myeloma and Risk-Adapted Therapy (mSMART) consensus guidelines. *Mayo Clin Proc* 2009;84:1095-110.
5. Attal M, Harousseau JL, Stoppa AM, et al. A prospective, randomized trial of autologous bone marrow transplantation and chemotherapy in multiple myeloma. Intergroupe Francais du Myelome. *The New England journal of medicine* 1996;335:91-7.
6. Kumar S, Giralt S, Stadtmauer EA, et al. Mobilization in myeloma revisited: IMWG consensus perspectives on stem cell collection following initial therapy with thalidomide-, lenalidomide-, or bortezomib-containing regimens. *Blood* 2009;114:1729-35.
7. Attal M, Harousseau JL, Facon T, et al. Single versus double autologous stem-cell transplantation for multiple myeloma. *New Engl J Med* 2003;349:2495-502.
8. Rajkumar SV, Hayman SR, Lacy MQ, et al. Combination therapy with lenalidomide plus dexamethasone (Rev/Dex) for newly diagnosed myeloma. *Blood* 2005;106:4050-3.
9. Zonder JA, Crowley J, Hussein MA, et al. Superiority of Lenalidomide (Len) Plus High-Dose Dexamethasone (HD) Compared to HD Alone as Treatment of Newly-Diagnosed Multiple Myeloma (NDMM): Results of the Randomized, Double-Blinded, Placebo-Controlled SWOG Trial S0232. *ASH Annual Meeting Abstracts* 2007;110:Abstract 77.
10. Kumar S, Dispenzieri A, Lacy MQ, et al. Impact of lenalidomide therapy on stem cell mobilization and engraftment post-peripheral blood stem cell transplantation in patients with newly diagnosed myeloma. *Leukemia* 2007;21:2035-42.
11. Paripati H, Stewart AK, Cabou S, et al. Compromised stem cell mobilization following induction therapy with lenalidomide in myeloma. *Leukemia* 2008;22:1282-4.
12. Mazumder A, Kaufman J, Niesvizky R, et al. Effect of lenalidomide therapy on mobilization of peripheral blood stem cells in previously untreated multiple myeloma patients. *Leukemia* 2008;22:1280-1.
13. Popat U, Saliba R, Thandi R, et al. Impairment of filgrastim-induced stem cell mobilization after prior lenalidomide in patients with multiple myeloma. *Biology of Blood and Marrow Transplantation* 2009;15:718-23.
14. Nazha A, Cook R, Vogl DT, et al. Stem cell collection in patients with multiple myeloma: impact of induction therapy and mobilization regimen. *Bone Marrow Transpl* 2011;46:59-63.
15. Hamadani M, Kochuparambil ST, Osman S, et al. Intermediate-dose versus low-dose

- cyclophosphamide and granulocyte colony-stimulating factor for peripheral blood stem cell mobilization in patients with multiple myeloma treated with novel induction therapies. *Biology of Blood and Marrow Transplantation* 2012;18:1128-35.
16. Malard F, Kroger N, Gabriel IH, et al. Plerixafor for autologous peripheral blood stem cell mobilization in patients previously treated with fludarabine or lenalidomide. *Biology of Blood and Marrow Transplantation* 2012;18:314-7.
17. Micallef IN, Ho AD, Klein LM, et al. Plerixafor (Mozobil) for stem cell mobilization in patients with multiple myeloma previously treated with lenalidomide. *Bone Marrow Transpl* 2011;46:350-5.
18. Shaughnessy P, Islas-Ohlmayer M, Murphy J, et al. Cost and clinical analysis of autologous hematopoietic stem cell mobilization with G-CSF and plerixafor compared to G-CSF and cyclophosphamide. *Biology of Blood and Marrow Transplantation* 2011;17:729-36.

Non-commercial use only