

Optimal position of a long-term central venous catheter tip in a pediatric patient with congenital diseases

Marco Caruselli,¹ Dario Galante,²
Anna Ficcadenti,³ Laura Carboni,⁴ Federica
Franco,⁵ Benedetta Fabrizzi,⁶ Lucia Amici,⁷
Roberto Giretti,¹
Giovanni Rocchi,¹ Giampaolo Rinaldelli¹

¹Anesthesia and Intensive Care Unit, Salesi
Children's Hospital, Ancona, Italy;

²Anesthesia and Intensive Care Unit,
University Hospital, Foggia, Italy;

³Pediatric Clinic Institute, Rares Diseases
Center, Politecnico University of Marche,
Ancona, Italy; ⁴Anesthesia and Intensive
Care Unit, Burlo Garofolo Children's
Hospital, Trieste, Italy; ⁵Anesthetics
Department, University College Hospital,
London, UK; ⁶Pediatric Clinic Institute,
Oncohaematological Unit, Politecnico
University of Marche, Ancona, Italy;
⁷Pediatric Radiology Unit, Salesi Children's
Hospital, Ancona, Italy

Abstract

Progress in medical and scientific research has increased the chances of survival for young patients with congenital diseases, children who, in the past, would not have had any chance of survival. Nowadays, congenital diseases can be treated with appropriate replacement therapies. These treatments can be difficult to administer in young patients because of the high frequency of administration (sometimes more than a dose per week), the use of intravenous infusion and the long-term or life-term requirement.

Introduction

Intravenous infusion (IV) treatment is often a traumatic experience for pediatric patients, particularly if multiple doses are required or treatment continues for long periods of time. For this reason, Port catheters are often inserted in patients affected by congenital diseases who require frequent IV treatments.¹ A Port catheter is totally subcutaneous. Therefore, in those patients who need intravenous therapies for many years or for life, it offers more advantages compared to Groshong and Broviac catheters, which are only partially tunnelled.² The Port catheter is less subject to bacterial colonizations, it is completely subcutaneous so there is less disturbance to daily life (*i.e.* patients can have

showers or practice sports with no risk of catheter damage or infection), and it can last for many years without problems (the reservoir can receive up to 2000 needlesticks). There has been much discussion about where is the best place to position the tip of a Port catheter.³⁻⁴ International guidelines recommend positioning the tip at the atriocaval junction or just above it in the superior vena cava (SVC) or upper part of the right atrium.⁵⁻¹¹ If the tip is too far above the junction, there is a higher risk of thrombus formation; if the tip is below the junction, particularly in the lower third right atrium, the risk of arrhythmias is high. In particular, American guidelines recommend that the catheter tip should not remain in the right atrium.¹²⁻¹⁹ Therefore, where should we position the tip of a Port catheter in a pediatric patient who will grow older and taller? If we position the tip of a catheter according to the guidelines, we will probably need to then change the catheter because the tip will migrate higher in the SVC as the patient grows. In our department, we routinely position long-term catheters (Broviac, Groshong, Hickman, Port) for pediatric onco-hematologic patients. We prefer the Port catheters for those patients affected by rare congenital diseases. We analyzed 4 patients with rare congenital diseases who had long-term catheters inserted. Given that these patients will grow older and taller, we inserted the tip of the catheter in the middle right atrium corresponding in chest X-rays to the middle arc of the cardiac silhouette. We analyzed 4 patients with congenital or onco-hematologic diseases who had had a Port catheter inserted more than two years earlier. Using chest X-rays, we checked where the tip of the catheter was at the time of our study compared to the position at the time of its insertion.

Case Report #1

The first patient was affected by type II mucopolysaccharidosis (MPS) disease and required IV therapy twice a week. A 6 French Port catheter had been positioned in 2005 when the patient was six years old. The catheter was positioned through the left subclavian vein with the tip of the catheter lying in the middle right atrium (Figure 1). The reservoir (height 10 mm, diameter 24.8 mm) was positioned on the lateral margin of the left pectoralis major muscle. We chose the left side because a ventricle-peritoneal drainage was positioned on the right side. The patient has never had any problems relating to the Port catheter. The chest X-rays performed in 2011, in a supine position as before (Figure 2), showed the tip of the catheter lying in the atriocaval junction. In six years, the patient had grown 36 cm taller (from 117 to 153 cm) and body weight had increased by 27.7 kg (from 22 to 49.7 kg).

Correspondence: Marco Caruselli, Anesthesia and Intensive Care Unit, Salesi Children's Hospital, Ancona, Italy.
Tel. +39.071.5962315
E-mail: camr@libero.it

Key words: child, central venous catheter tip, congenital disease.

Conflict of interests: the authors report no potential conflict of interests.

Received for publication: 30 April 2012.

Revision received: 28 August 2012.

Accepted for publication: 7 September 2012.

This work is licensed under a Creative Commons Attribution NonCommercial 3.0 License (CC BY-NC 3.0).

©Copyright M. Caruselli et al., 2012
Licensee PAGEPress, Italy
Pediatric Reports 2012; 4:e32
doi:10.4081/pr.2012.e32

Case Report #2

The second patient was also affected by type II MPS and also required IV therapy twice a week. A 6 French Port catheter had been positioned in 2005 when the patient was two years old. The Port (Figure 3) was positioned through the right subclavian vein with the tip of the catheter lying in the middle right atrium. The reservoir (height 10 mm, diameter 24.8 mm) was positioned on the lateral margin of the right pectoralis major muscle. Like the previous patient, this patient had also never had any problems relating to the Port catheter. The chest X-ray performed in 2011, in a supine position as before (Figure 4), showed the tip of the catheter lying in the atriocaval junction. In six years, the patient had grown 46 cm taller (from 95 to 141 cm) and body weight had increased by 18.6 kg (from 13.1 to 31.7 kg).

Case Report #3

The third patient was affected by type I spinal muscular atrophy and had very poor peripheral veins. The patient required occasional IV antibiotic therapy. A 3.9 French Port catheter had been inserted in 2006 through the right internal jugular vein when the patient was 11 months old. An X-ray in 2006 (Figure 5) in a supine position shows the tip of the catheter lying in the middle right atrium. The reservoir (height 8 mm, diameter 22.7 mm) was positioned on the lateral margin of the right pectoralis major muscle. Like the

previous 2 patients, this patient has never had any problems relating to the Port catheter. The X-ray performed in 2011 in the same position (Figure 6) shows the tip of the catheter lying in the right jugular vein, and subsequently the catheter was removed. The patient had grown 47 cm taller (from 60 to 107 cm) and body weight had increased by 11.5 kg (from 5 to 16.5 kg).

Case Report #4

The fourth patient was affected by a congenital shoulder fibrosarcoma requiring long-term chemotherapy. A 3.9 French Port catheter had been inserted in 2010 through the right internal jugular vein when the patient was 50 days old. An X-ray performed in a supine position after the insertion of the catheter (Figure 7) shows the tip of the catheter lying in the middle right atrium. The reservoir (height 8 mm, diameter 22.7 mm) was positioned on the lateral margin of the right pectoralis major muscle. The X-ray performed in 2012 in the same position (Figure 8) shows the tip of the catheter lying in the SVC. The patient had grown 50 cm (from 52 to 102 cm) and body weight had increased by 10.09 kg (from 2.91 kg to 13 kg).

Discussion

All the pediatric patients discussed here required long-term IV treatments for congenital diseases and during the treatment period they were expected to grow taller.

International guidelines recommend positioning the tip in the SVC or at the atricaval junction or upper part of the right atrium. The American guidelines recommend that the catheter tip should not remain in the right atrium given the increased risk of atrial perforation. According to international guidelines, positioning the tip above the SVC increases the risk of thrombosis while positioning it at the lower third of the right atrium can cause severe arrhythmias if the tip touches the valve leaflets. These guidelines are for both short- and long-term CVC. In our opinion, the guidelines should pay more attention to the fact that there are few young patients requiring frequent and long-term treatments for congenital diseases and that these patients will have the catheter for many years. Catheter re-insertion in children can be very stressful.

In an adult patient, who will not grow any taller, the tip of the catheter will be in the same position in the SVC even after five or six years. In a pediatric patient, however, we always need to consider the fact that they will inevitably grow older and taller. We should also consider avoiding catheter re-insertions in these children. We, therefore, need to find a compromise between

the correct position of the tip of the catheter and the longest possible time the catheter can stay in place. In a child, if we position the catheter according to the international guidelines (in the SVC or upper part of the right atrium) we will then need to remove the catheter after a short period of time, causing further distress to the patient. In this paper we have discussed a small number of patients affected by rare diseases. These patients needed intravenous therapies for many years in a period in which both height and body weight increase. In most patients who need tunnelled central venous catheters (particularly onco-hematologic patients) a period of hospitalization of over 12-18 months is rare. In these cases, we more often use the semi-tunneled catheter (Broviac or Groshong) and we prefer to

position the catheter tip in the SVC or atrio-caval junction. The Port catheter is used for older children (usually over ten years old). In patients who need tunnelled central venous catheters for the treatment of congenital diseases, we use Port catheters. In these particular cases, we prefer to position the catheter tip in middle right atrium to avoid the need for an early re-insertion. In pediatric patients, we often position the reservoir on the lateral margin of the pectoralis major muscle. There are three reasons for this: i) esthetic reasons, particularly in female patients; ii) to avoid the accidental traumatic damage while the child plays with friends; iii) the increased presence in some children of subcutaneous tissue.

A limited presence of subcutaneous tissue can cause skin decubitus.

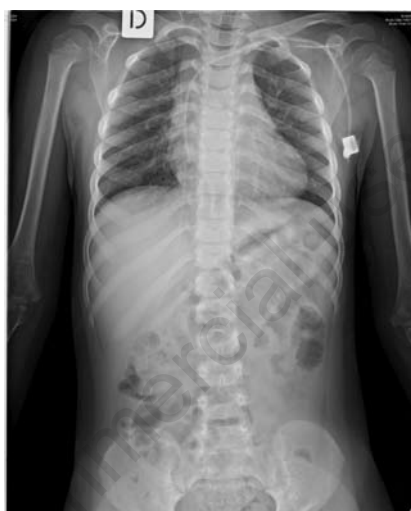

Figure 1. Case #1. Initial tip position.

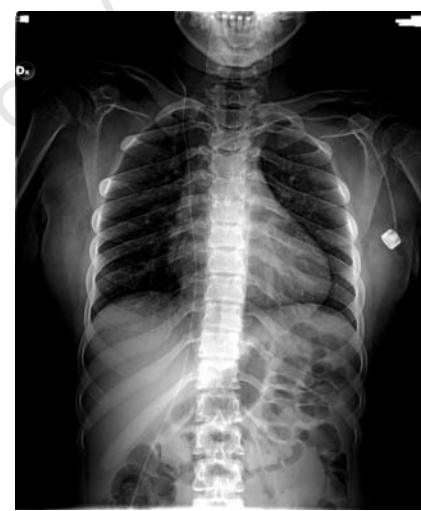

Figure 2. Case #1. Tip position after 6 years.

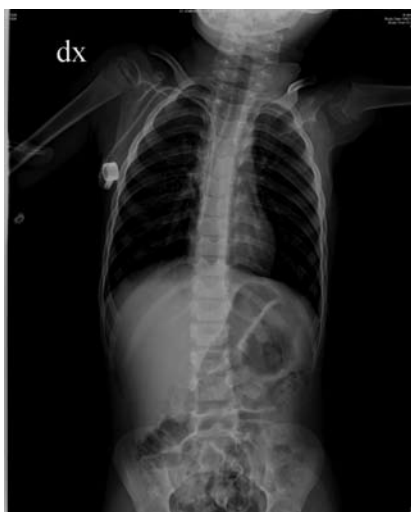

Figure 3. Case #2. Initial tip position.

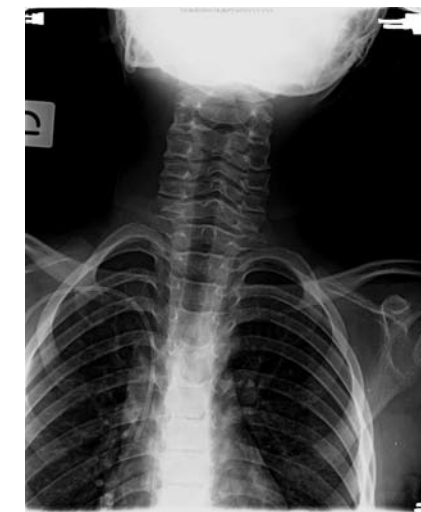

Figure 4. Case #2. Tip position after 6 years.

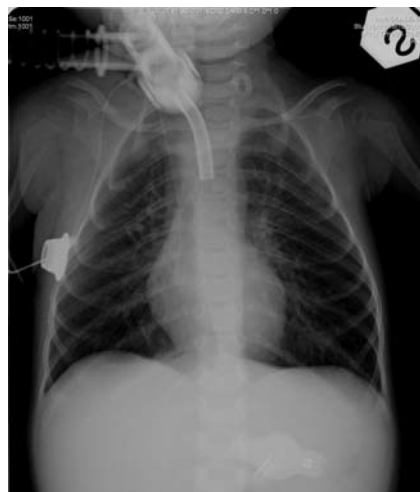

Figure 5. Case #3. Initial tip position.

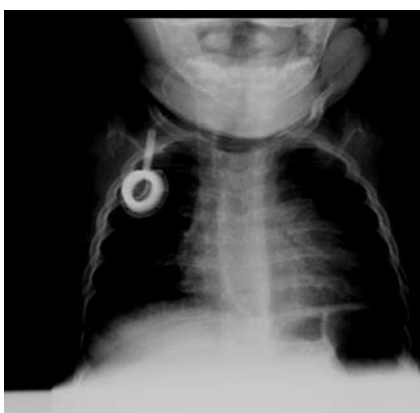


Figure 7. Case #4. Initial tip position.

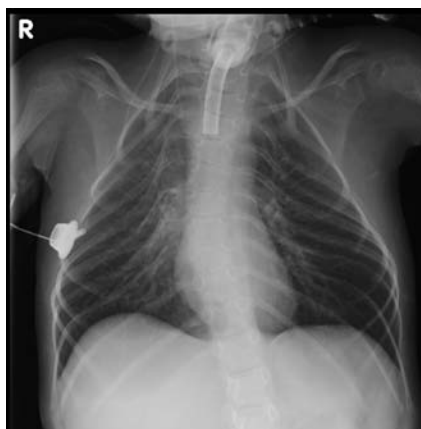


Figure 6. Case #3. Tip position after 5 years.

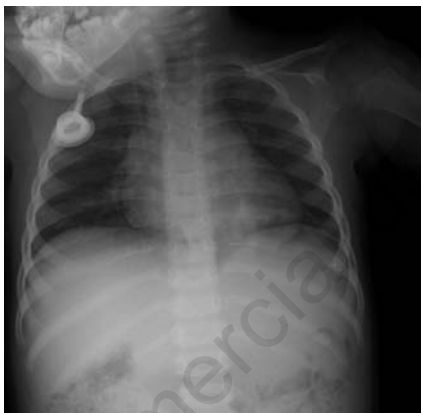

Figure 8. Case #3. Tip position after 2 years.

Conclusions

Our preliminary conclusions are that, in positioning a long-term catheter in pediatric patients with rare congenital diseases, we always need to consider the fact that the patients will grow older and taller, and the tip of the catheter will, therefore, migrate. For that reason, to avoid the further stress to the patients of having to re-insert the catheter, we would recommend assessing the possibility of positioning the tip of the catheter in the middle right atrium, even though international guidelines indicate that it should be positioned in the atriocaval junction above the upper right atrium.

References

1. Caruselli M, Zannini R, Giretti R, et al. The

- pinch off syndrome in a pediatric patient. *Pediatr Anaesth* 2009;19:179-81.
2. Caruselli M, Carboni L, Franco F, et al. Central venous catheters in neonates: from simple monolumen to Port catheter. *J Vasc Access* 2011;12:4-8.
3. Fricke BL, Racadio JM, Duckworth T, et al. Placement of peripherally inserted central catheters without fluoroscopy in children: initial tip position. *Radiology* 2005; 234:887-92.
4. Vesely TM. Central venous catheter tip position: a continuing controversy. *J Vasc Interv Radiol* 2003;14:527-34.
5. Kim JH, Kim CS, Bahk JH, et al. The optimal depth of central venous catheter for infants less than 5 kg. *Anesth Analg* 2005;101:1301-3.
6. Debourdeau P, Chahmi DK, Le Gal G, et al. 2008 SOR guidelines for the prevention and treatment of thrombosis associated with central venous catheters in patient with can-

cer: report from the working group. *Ann Oncol* 2009;20:1459-71.

7. SINPE. Guidelines for artificial feeding hospital. *RINPE*. 2002;20suppl21:29-33.
8. Bishop L, Dougherty L, Bodenham A, et al. British committee for standards in haematology: guidelines on the insertion and management of central venous access devices in adults. *Int J Lab Haem* 2007; 29:261-78.
9. Farge D, Durant C, Villiers S, et al. Lessons from French national guidelines on the treatment of venous thrombosis and central venous catheters thrombosis in cancer patients. *Thromb Res* 2010;125:S108-16.
10. Pittiruti M, Hamilton M, Biffi R, et al. ESPEN guidelines on parenteral nutrition: central venous catheters (access, care, diagnosis and treatment of complications). *Clin Nutr* 2009;28:365-77.
11. Dariushnia SR, Wallace MJ, Siddiqui NH, et al. Quality improvement guidelines for central venous access. *J Vasc Interv Radiol* 2010; 21:976-81.
12. Cadman A, Lawrance JAL, Fitzsimmons L, et al. To clot or not to clot? That is the question in central venous catheters. *Clin Radiol* 2004;59:349-55.
13. Petersen J, Delaney JH, Brakstad MT, et al. Silicone venous access devices positioned with their tips high in the superior vena cava to malfunction likely are blackberries. *Am J Surg* 1999;178:38-41.
14. Caers J, Fontaine C, Vinh-Hung V. Catheter tip position as a risk factor for thrombosis associated with the use of subcutaneous infusion ports. *Support Care Cancer* 2005; 13:325-31.
15. Puel V, Caudry M, Le Metayer P. Superior vena cava thrombosis related to catheter malposition in cancer chemotherapy given through implanted ports. *Cancer* 1993; 72:2248-52.
16. Luciani A, Clement O, Halimi P. Catheter-related upper extremity deep venous thrombosis in cancer patients: a prospective study based on doppler. *US Radiology* 2001;220: 655-60.
17. Gallieni M, Pittiruti M, Biffi R. Vascular access on oncology patients. *CA Cancer J Clin* 2008;58:323-46.
18. Campisi C, Biffi R, Pittiruti M. Central venous catheter related thrombosis: the development of a nationwide consensus paper in Italy. *JAVA* 2007;12:38-46.
19. Rash K, Manimala R, Mrinal M. How correct is the correct length for central venous catheter insertion. *Indian J Crit Care Med* 2009;13:159-62.