

Pityriasis rosea, Gianotti-Crosti syndrome, asymmetric periflexural exanthem, papular-purpuric gloves and socks syndrome, eruptive pseudoangiomatosis, and eruptive hypomelanosis: do their epidemiological data substantiate infectious etiologies?

Antonio Chuh,¹ Vijay Zawar,²
Gabriel F. Sciallis,³ Werner Kempf,⁴
Albert Lee¹

¹JC School of Public Health and Primary Care, The Chinese University of Hong Kong and Prince of Wales Hospital, Shatin, Hong Kong; ²Department of Dermatology, Godavari Foundation Medical College and Research Center, DUPMCJ, India; ³Department of Dermatology, Mayo Clinic College of Medicine, Rochester, MN, USA; ⁴Department of Dermatology, University Hospital Zürich, Zürich, Switzerland

Abstract

Many clinical and laboratory-based studies have been reported for skin rashes which may be due to viral infections, namely pityriasis rosea (PR), Gianotti-Crosti syndrome (GCS), asymmetric periflexural exanthem/unilateral laterothoracic exanthem (APE/ULE), papular-purpuric gloves and socks syndrome (PPGSS), and eruptive pseudo-angiomatosis (EP). Eruptive hypomelanosis (EH) is a newly discovered paraviral rash. Novel tools are now available to investigate the epidemiology of these rashes. To retrieve epidemiological data of these exanthema and analyze whether such substantiates or refutes infectious etiologies. We searched for articles published over the last 60 years and indexed by PubMed database. We then analyzed them for universality, demography, concurrent patients, temporal and spatial-temporal clustering, mini-epidemics, epidemics, and other clinical and geographical associations. Based on our criteria, we selected 55, 60, 29, 36, 20, and 4 articles for PR, GCS, APE/ULE, PPGSS, EP, and EH respectively. Universality or multiple-continental reports are found for all exanthema except EH. The ages of patients are compatible with infectious causes for PR, GCS, APE/ULE, and EH. Concurrent patients are reported for all. Significant patient clustering is demonstrated

for PR and GCS. Mini-epidemics and epidemics have been reported for GCS, EP, and EH. The current epidemiological data supports, to a moderate extent, that PR, GCS, and APE could be caused by infectious agents. Support for PPGSS is marginal. Epidemiological evidences for infectious origins for EP and EH are inadequate. There might be growing epidemiological evidence to substantiate or to refute our findings in the future.

Introduction

The etiologies of several exanthema including pityriasis rosea (PR), Gianotti-Crosti syndrome (GCS), asymmetric periflexural exanthem/unilateral laterothoracic exanthem (APE/ULE), papular-purpuric gloves and socks syndrome (PPGSS), eruptive pseudoangiomatosis (EP), and eruptive hypomelanosis (EH) are incompletely understood.

There are four ways to investigate such exanthema: clinical studies, laboratory-based studies, epidemiology studies, and, relatively indirect, clinical trials.

For clinical studies, a diagnostic criteria and a set of classification were postulated and validated.¹ For laboratory-based studies, we progressed from Koch's postulates (which did not take viral infections into account)² to Rivers' criteria (modified from Koch's postulates to cater for viral infections),³ and then to other criteria such as those postulated by Fredericks and Relman⁴ (which take DNA and mRNA sequence-detection procedures into account).³ Virological tools such as real-time PCR, virus load, reverse-transcriptase PCR, and antibody avidities are much advanced today.

For clinical trials, studies on the use of macrolides and anti-viral medications in PR are escalating in number and in the qualities of the methodologies.⁵⁻⁷ Patient-assessed parameters such as quality of care are being incorporated as outcome measures in the more recent studies,^{6,7} in line with studies for other skin diseases.

Tools in epidemiology are now much advanced. Patient clustering and epidemics can now be detected by various analyses.^{8,9} Softwares are available for systematic reviews and meta-analyses.¹⁰ Various plots facilitate meta-analyses¹¹ and the estimation of publication bias.¹² We have postulated a protocol to establish and validate diagnostic criteria of skin diseases so that high homogeneities would be achieved in meta-analyses.¹ Platforms for dermato-epidemiology enable conjoint efforts to apply epidemiology methodologies to investigate patients and communities with skin diseases.¹³

For epidemiological evidence for environmental causes, Hill's criteria (strength, consis-

Correspondence: Antonio Chuh, Shops 5 and 6, The Imperial Terrace, 356 Queen's Road West, G/F, Hong Kong.
Tel.: +852.25590420 - Fax: +852.22394009.
E-mail: antonio.chuh@yahoo.com.hk

Key words: papular acrodermatitis of childhood; paraviral exanthema; regression analyses with bootstrapped simulations; temporal clustering; unilateral medi thoracic exanthema.

Contributions: AC, original conceptualization of the systematic review, devising the methodology, data collection, data interpretation, drafting the first version, writing the final version; VZ, systematic literature search, data interpretation, inputs on clinical aspects, drafting the first version, writing the final version, as corresponding author liaising with co-authors and the journal; GS, drafting the first version, data interpretation, responsible to respond to reviewers' comments, checking the English language, finalizing the article for submission; WK, data interpretation, inputs in virological aspects, drafting the first version, critical review, finalizing the article for submission; AL, data interpretation, inputs in epidemiological aspects, drafting the first version, critical review, finalizing the article for submission.

Conflict of interest: the authors declare no potential conflict of interest.

Received for publication: 18 January 2016.
Revision received: 24 February 2016.
Accepted for publication: 24 February 2016.

This work is licensed under a Creative Commons Attribution-NonCommercial 4.0 International License (CC BY-NC 4.0).

©Copyright A. Chuh et al., 2016
Licensee PAGEPress, Italy
Infectious Disease Reports 2016; 8:6418
doi:10.4081/idr.2016.6418

tency, specificity, temporality, biological gradient, plausibility, coherence, experimental evidence, and analogy)¹⁴ is still applicable to some extent. For evaluating the evidence of efficacies of various treatment modalities, we have conducted a systematic review¹⁵ and a Cochrane review¹⁶ for PR, but not for other exanthema.

However, we lack a yardstick for the adequacies of epidemiological evidence in substantiating infectious etiologies. We therefore believe that a systemic and qualitative evaluation of the epidemiological evidence for infectious etiology of these exanthema is timely and necessitated.

Aim

Our aim was to conduct a systematic review on the epidemiology of PR, GCS, APE/ULE,

PPGSS, EP, and EH, and to investigate whether the epidemiological findings substantiate infectious etiologies.

Materials and Methods

Literature search

We searched for all articles published over the last 60 years and indexed in PubMed, placing more emphasis on epidemiology reports.

Analyses

We analyzed the following epidemiological parameters: i) history and universality, ii) genetic makeup, iii) incidence and prevalence, iv) demography, v) concurrent patients, vi) patient clustering, vii) mini-epidemics and epidemics, and viii) other associations.

Some of these parameters are more important than others. History and universality by themselves are weak as evidence for an infectious etiology. Genetic makeup, unless widely reported with the genotypes identified and proven to be of close association with the phenotype, namely the skin rash, is also relatively weak evidence. Incidence and prevalence provide moderate levels of support.

Demography is important mainly due to the age of patients. If most patients are infants or children, it might be compatible with the hypothesis of lack of specific immunity upon

the first exposure to the virus concerned. The absence or near-absence of relapse is highly characteristic of some viral infections. The demonstration of epidemics is a very strong substantiating factor for an infectious etiology, followed by the discovery of mini-epidemics, the reports of significant patient clustering, and then the depiction of concurrent patients.

As mentioned above, there is no threshold for the adequacy of epidemiology data in supporting infectious etiologies. We shall adopt a qualitative approach in our analyses.

Results

For PR, we selected 55 articles;¹⁷⁻⁷¹ 19 are epidemiology studies (summarized in Table 1).¹⁸⁻³⁶ One paper was not specific for PR.²⁹ We contacted the chief investigator (Nanda A, personal communication), and the data specific for PR became available. For GCS, APE/ULE, PPGSS, EP, and EH, we retrieved 60,⁷²⁻¹³¹ 29,¹³²⁻¹⁶⁰ 36,¹⁶¹⁻¹⁹⁵ 20,¹⁹⁷⁻²¹⁶ and four²¹⁷⁻²²⁰ articles respectively. The results of our analyses are summarized in Table 2.

Pityriasis rosea

PR is the commonest paraviral exanthema. After a prodromal coryzal phase, a herald patch

(Figure 1) develops in around 30-50% of all patients. The generalized secondary eruption appear one to three weeks later, most commonly affecting the trunk and proximal aspects of limbs. Peripheral collarette scaling is seen in the herald patch and the larger lesions. The oval-shaped lesions might orient along lines of skin cleavage. Spontaneous remission is then seen in four to eight weeks for most patients.

History and universality

PR was initially described by Camille Melchoir Gibert in 1860 in France.¹⁷ The annular configuration was first described by Pierre-Antoine-Ernest Bazin in 1862, and the herald patch was first described in 1887.¹⁷

Rashes with infectious etiologies would appear in various countries and regions, unless specific factors, like herd immunity, limit the susceptibility.

PR is universal.¹⁷⁻³⁶ The universality of PR shows that genetic predisposition is unlikely to be important. External factors are necessary. These factors are unlikely to be environmental, as people around the globe do not share similar environmental factors. A factor being an infectious microbe could explain the universality. We therefore believe that the universality of PR offers some support for an infectious etiology.

Genetic makeup

Brazilian black people with the alleles

Table 1. Summary of epidemiological studies on pityriasis rosea.

Author, year	Location	N. patients	Male: female	Seasonal variation	Incidence
Abercrombie, 1962 ¹⁸	UK	138	1: 1.49	Reported no seasonal variation	Not reported
Vollum, 1973 ¹⁹	Uganda	221	1: 1.22	Reported no seasonal variation	2.33 per 100 dermatological patients
Jacyk, 1980 ²⁰	Nigeria	138	1: 1.12	Reported no seasonal variation	2.42 per 100 dermatological patients
Messenger <i>et al</i> , 1982 ²¹	England	126	1: 1.80	Higher incidence in winter months	Not reported
Chuang <i>et al</i> , 1982 ²²	USA	939	1: 1.76	Significantly higher in colder months	172.2 per 100,000 person-years
de Souza Sittart <i>et al</i> , 1984 ²³	Brazil	682	1: 3.01	Higher incidence in June, October and November	0.39 per 100 dermatological patients
Ahmed, 1986 ²⁴	Sudan	81	1: 1.53	Peaked in cold and dry season (January to March)	1.09 per 100 dermatological patients
Olumide, 1987 ²⁵	Lagos	152	1: 1.20	Peaked during early part of rainy season (March to July)	4.80 per 100 dermatological patients
Cheong and Wong, 1989 ²⁷	Singapore	214	1.85: 1	Higher incidence in March, April and November	Not reported
Harman <i>et al</i> , 1998 ²⁸	Turkey	399	1: 1.21	Peaked during spring, autumn and winter	0.75 per 100 dermatological patients
Nanda <i>et al</i> , 1999 ²⁹	Kuwait	117	1: 1.38	Not reported	1.17 per 100 dermatological patients
Tay and Goh, 1999 ³⁰	Singapore	368	1.19: 1	Reported no seasonal variation	0.65 per 100 dermatological patients
Traore <i>et al</i> , 2001 ³¹	Burkina Faso	36	01:01	Not reported	0.6 per 100 secondary school pupils (prevalence in a cross sectional survey)
Sharma and Srivastava, 2008 ³³	India	200	1.99:1	Maximum during September to December, minimum from March to June	0.25 per 100 dermatological patients
Ayanlowo <i>et al</i> , 2010 ³⁴	Nigeria	427	1: 1.55	Maximum in October, minimum from January to February	3.7 per 100 dermatological patients
Ganguly, 2013 ³⁵	South India	73	1.35: 1	Seasonal variation not evident; few cases in the rainy season	Not reported
Özyürek <i>et al</i> , 2014 ³⁶	Turkey	52	1: 1.08	Maximum in February to April, minimum from July to August	Not reported

DQB1*04 are more susceptible to develop PR (RR: 4.00; 95%CI: 1.2-13.28).³⁷ However, PR occurs in ethnicities without this alleles. Genetic makeup is thus unlikely to be important.

Incidence

We performed quantitative analyses on the data of 2,888 patients with PR out of 454,254 dermatological patients in ten studies.^{19,20,23-26,28,30,32,33} The overall incidence is 0.64 per 100 dermatological patients. On its own, incidence offers little substantiation for an infectious etiology.

Correlation with economic status

We evaluated the correlation between the incidence and gross domestic product per capita for six countries (Uganda,¹⁹ Nigeria,²⁰ Brazil,²³ Sudan,²⁴ Kuwait,²⁹ and India³³) with incidences of PR being accessible. Spearman rank-order correlation coefficient (γ_s) was -0.0857 (insignificant). Economical status is thus not associated with the occurrence of PR.

Age

PR occurs in all ages from infants³⁹ to the elderly,⁴¹ with most patients between ten to 35 years of age.⁴⁰ We postulate that some patients with PR are due to primary viral infections, while others being related to endogenous reactivation.

From results of our previous PCR and serology studies,⁴¹⁻⁴⁴ we did find virological profiles compatible with primary infection in the younger patients, and profiles indicating endogenous reactivation of viruses in older patients. However, the distribution was statistically insignificant.

We thus believe that age offers some support for PR being related to infectious causes.

Sex

We analyzed 3809 patients with PR from 18 studies.¹⁸⁻¹²⁵ 1931 were males and 2630 were females (male: female ratio being 1:1.39). The female predominance may be related to altered immunomodulations during stress, such as pregnancy⁴⁵ or females seeking medical help more frequently.⁴⁶ Sex distribution offers no substantiation for an infectious etiology.

Low rate of relapse

The rate of relapse of PR is 1.8-3.7%.^{22,47,48} The herald patch was always absent in relapses.⁴⁸ A low rate of relapse is an epidemiological hallmark of viral infections.

Concurrent patients

Reports of concurrent patients in close contact offer some support for an infectious etiology.⁴⁹⁻⁵³

Table 2. Summary of epidemiological evidence supporting infectious aetiologies in six paraviral exanthema.

	Universality	Age	Concurrent patients	Temporal and spatial-temporal clustering	Mini-epidemic/epidemic	Other associations
Pityriasis rosea	Yes ¹⁸⁻³⁶	Most between the ages of 10-35 years; ^{38,40} compatible with an infectious etiology	Numerous reports ⁴⁵⁻⁴⁹	Temporal clustering demonstrated ^{21,50,51}	Mini-epidemics ^{53,55}	Associated with primary infection or endogenous reactivations of human herpesvirus-7 and 6, ^{54,59} Associated with respiratory tract infections suspected ⁵² conflicting findings for seasonal variations; ^{18,25,27,28,30,33,38} not associated with weather changes. ⁵⁰
Gianotti-Crosti syndrome	Yes ^{72,73,55,56,117}	Most below three to four years of age ^{77,78}	Yes ^{72,75}	Spatial-temporal clustering demonstrated ⁴⁸³	Yes ^{84,88}	Associated with hepatitis B virus, ^{84,88} Epstein Barr virus, ^{71,75} Coxsackie viruses, ^{95,98} cytomegalovirus, ^{97,99,102} enteroviruses, ¹⁰³ hepatitis A virus, ^{104,105} herpes simplex virus type 1, ¹⁰⁶ human herpesvirus 6, ^{100,107} HIV, ^{108,109} influenza virus, ¹¹⁰ mumps virus, ¹¹¹ parainfluenza virus, ¹¹² parvovirus B19, ^{113,114} poxviruses, ^{114,115} respiratory syncytial virus, ¹⁰⁵ and rotavirus ^{116,117} infections
Asymmetric perilesional exanthem	Yes ¹³⁵⁻¹⁶⁰	Most in infancy to young childhood ^{132,134,139,145,151}	Yes ^{137,138}	-	-	Associated with respiratory tract infections, ^{140,142} and immunodeficiencies, ^{140,157} parvovirus B19, ^{141,147,154,155} parainfluenza virus types 2, ¹⁴⁷ and 3, ¹⁴⁷ adenovirus ¹⁴² virus infections. Predilection to occur in spring and summer months. ^{159,157,158,147}
Papular-purpuric gloves and socks syndrome	Yes ⁶³⁻⁸³	Mostly adults ^{71,184,189} and young adults ¹⁹⁰⁻¹⁹³	Yes ^{164,195,196}	-	-	-
Eruptive pseudoangiomatosis	Yes ¹⁹⁷⁻²¹⁶	All ages, mostly adults ^{200-202,204,205,209-214}	Yes ^{202,203,213}	-	Yes ^{204,209}	Associated with insect bites, ^{202,211,213} immunodeficiency, ^{201,205,215} and hospitalization for treating malignancies or asthma ^{201,208}
Eruptive hypomelanosis	-	Mostly children below the age of six years ²¹⁷⁻²²⁰	Yes ²²⁰	-	Yes ²²⁰	-

Patient clustering

Significant spatial-temporal clustering was reported for female patients.²⁷ However, the *moving window test* employed in that study was not a validated tool, and controls were unavailable.¹⁶⁰

We have applied a validated regression analysis with bootstrapped simulations, and reported a multi-center epidemiology study in primary care settings in Hong Kong ($P=0.031$).⁶⁰ We then applied the regression analysis to the epidemiology data of 1379 patients with PR in Kuwait, Turkey, and US.⁶¹ Significant temporal clustering was found in all three patient series, while not found in control series of patients consulting for psoriasis).

Epidemics

Mini-epidemics have been reported for PR.^{53,55} Patient clustering and mini-epidemics thus support an infectious etiology. The strength of this support might be surpassed by the report of one major epidemic in the future, which would still be further surpassed by the report of multiple epidemics of similar natures.

Association with respiratory tract infections

PR is associated with respiratory tract infections,⁵⁶ suggesting a droplet-spread micro-organism being the cause.

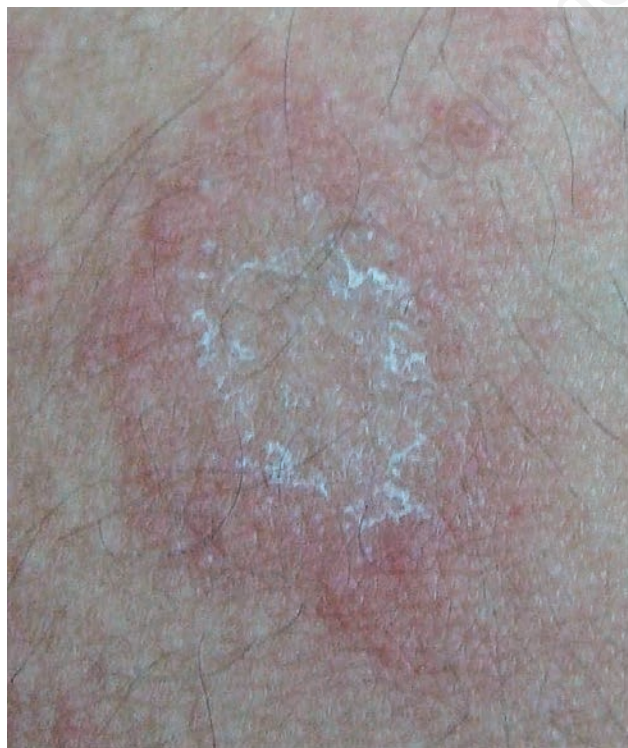

Figure 1. A herald patch demonstrating peripheral collarette scaling in a patient with pityriasis rosea

Seasonal variation, weather and climate changes

Studies on seasonal variation^{18-25,27,28,30,33-36} reported conflicting results (Table 1). Moreover, seasonal variation occurs in non-infectious diseases.⁵⁷

We have reported that PR is insignificantly associated with monthly mean air temperature ($\gamma_s=-0.41$; $P=0.19$), monthly mean total rainfall ($\gamma_s=-0.34$; $P=0.27$), and monthly mean relative humidity ($\gamma_s=-0.038$; $P=0.91$).⁵⁴ Seasonal variations, weather and climate changes therefore do not support infectious etiologies.

Seroprevalence

Many studies substantiate the association of primary infection and endogenous reactivation of human herpes virus (HHV)-7 and -6 and PR.⁵⁸⁻⁶³ For reasons yet unknown, negative findings were reported by us^{41,42} and by several other investigators.⁶⁴⁻⁶⁷ We have excluded the roles of three other herpes viruses [HHV-8,⁴³ cytomegalovirus (CMV),⁴⁴ and Epstein-Barr virus (EBV)⁴⁴] and parvovirus B19 (B19V)⁴⁴ in

PR. Virological, immunohistochemical, and serological findings are not the realms in this review, but seroprevalence is. Previously, the gold criteria for primary infection of herpes viruses was seroconversion.⁶⁸ High virus load in the plasma or peripheral blood mononuclear cells together with IgG negativity would be contenders.^{68,69} However, the background seroprevalences against different herpes viruses are different across the world.

Moreover, HHV-6 demonstrates chromosomal integration,⁷⁰ rendering interpretation of epidemiology data difficult. Seroprevalence might thus be a confounding independent variable in epidemiological analyses.⁷¹

Analyses

PR exhibits virtually absolute universality. The predominant age being 10-35 years might be due to viral primary infection for some patients and endogenous reactivation for others. Concurrent patients and patient clustering are well proven. We thus believe that the epidemiological evidence strongly substantiates PR being caused by infectious agents.

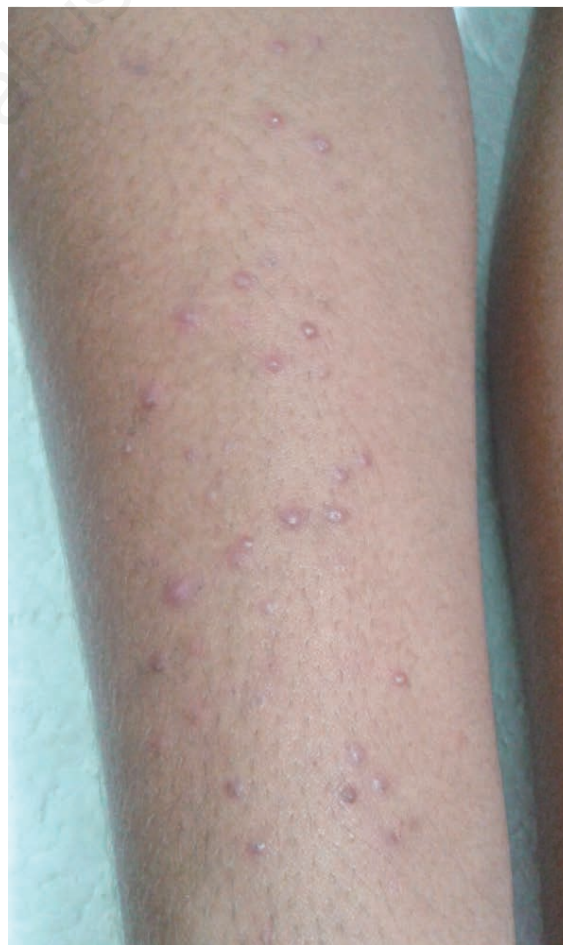

Figure 2. Monomorphic papules on the forearm of a patient with Gianotti-Crosti syndrome, also known as papular acrodermatitis of childhood.

Gianotti-Crosti syndrome

History and the initial clusters of children

In 1952, Gianotti discovered groups of children in Milan with a monomorphous papular eruption mainly affecting extensor aspects of the extremities.⁷²⁻⁷⁵ Fever, lymphadenitis, and hepatomegaly were sometimes seen. Gianotti suspected an infectious etiology owing to *monocytoid cells* and *Türk's cells* in the peripheral blood.

Age

Most patients with GCS are below the age of four,⁷⁶⁻⁷⁸ compatible with primary infections of viruses. Adult patients are uncommon but not rare (Figure 2).

Sex

There was no sexual preponderance.⁷⁶⁻⁷⁸ This is compatible with infectious disease, as sexual imbalance is seen in some genetic or congenital diseases.⁷¹ However, for adults with GCS, a marginal predominance of females is seen,^{71,76} the reason of which being yet unknown.

Initial laboratory evidence

Hepatitis B virus (HBV) surface antigen was found in the sera of children with GCS in 1970,^{80,81} and HBV infection was assumed to be the sole culprit.

Patient clustering

Employing regression analyses with bootstrapped simulations, we have previously reported on the detection of spatial-temporal clustering for children with GCS ($P=0.044$).⁸² We traced and found a 15-month-old boy with GCS eruption five days before attending a wedding party. Five other children attended the party, with three developing GCS five, eight and nine days after the party.

Epidemics

Five epidemics have been reported, the first three in Japan (1976 in Matsuyama,^{83,84} 1981 in Iwakuni City,⁸⁵ 1988 in Saga City⁸⁶) and the fourth in Italy.⁸⁷ The fifth was our reported mini-epidemic⁸¹ (the close proximity of *three* patients is conventionally considered to be a mini-epidemic in the literature).^{88,89} Clustering and epidemics thus substantiate an infectious cause.

Geographical correlation

The early children and children in the first three epidemics were related to HBV infection. Such correlates with the high prevalence of chronic HBV infection in the 1970s-80s in Japan.^{90,91} Geographic correlation thus supports an infectious etiology.

Subsequent laboratory evidence and universality

By the mid-1980s, the role of HBV infection in GCS declined,^{84,93} to be replaced by EBV infection.⁸⁷ GCS was subsequently reported in association with Coxsackie viruses,⁹⁵⁻⁹⁷ CMV,⁹⁸⁻¹⁰¹ the

enteroviruses,¹⁰² hepatitis A virus,^{103,104} herpes simplex virus type 1,¹⁰⁵ HHV-6B,^{106,107} HIV,^{108,109} type A influenza virus,¹¹⁰ mumps virus,¹¹¹ parainfluenza virus,¹¹² B19V,^{113,114} poxviruses,^{114,115} respiratory syncytial virus,¹⁰³ and rotavirus infections.^{116,117}

GCS was also associated with the following vaccines: diphtheria-pertussis-tetanus,¹¹⁸⁻¹²² hepatitis A,¹²¹⁻¹²³ HBV,^{124,125} influenza,¹²⁶⁻¹²⁸ Japanese encephalitis,¹²⁹ measles,¹²⁴ measles-mumps-rubella,^{118,130} and poliomyelitis (oral vaccine, US¹⁰³ and Turkey).^{103,111} However, temporal relationships do not necessarily imply causal relationships.

Analyses

GCS is almost universal, with most patients being young children. Concurrent patients and spatial-temporal clustering are seen. Five epidemics are reported. The epidemiological evidence strongly supports GCS being due to infection.

Asymmetric periflexural exanthem/unilateral laterothoracic exanthem

History: the three independent discoveries

In 1962, Brunner *et al.* reported 75 young children with a new skin rash in US.¹³² The rash erupted unilaterally near the axilla, then extended to the trunk and the arm (Figure 3A).

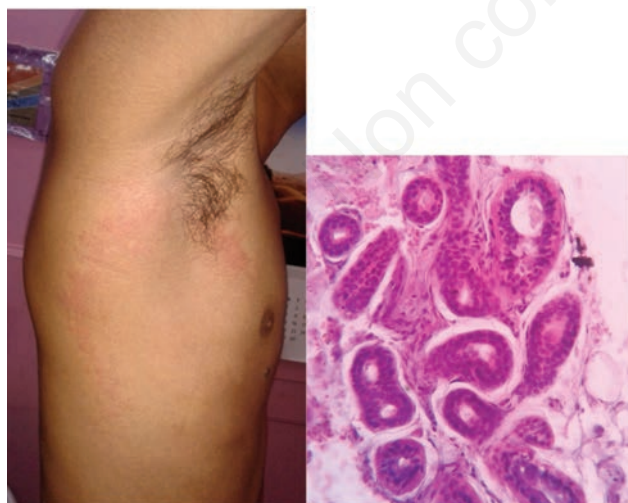


Figure 3. A) The rash in symmetrical periflexural exanthem, also known as unilateral laterothoracic exanthem, commences on the lateral aspect of the trunk near to the axilla. B) The presence of perisudoral lymphocytic infiltrates has been reported as a fairly specific histopathological feature in asymmetric periflexural exanthem/unilateral laterothoracic exanthem/unilateral mediothoracic exanthem (haematoxylin and eosin stain, 100x when the microphotograph was taken).

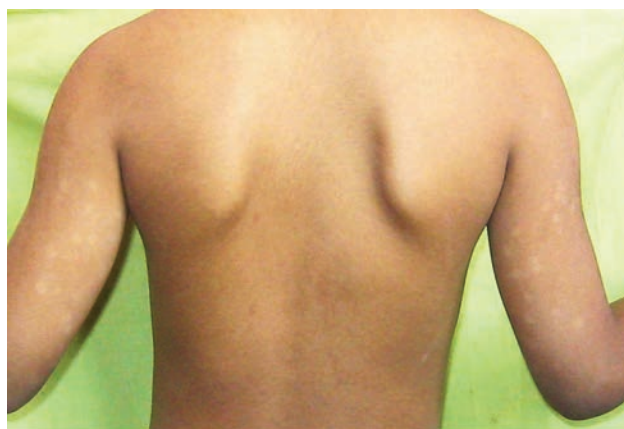

Figure 4. Eruptive hypomelanosis is a recently reported paraviral exanthem with round or oval hypopigmented patch seen after a prodromal phase. The commonest sites are extensor surfaces of the limbs, as seen in this child with lesions at extensor aspects of bilateral arms.

30 years later, Bodemer and de Prost reported a similar rash in France which they termed *unilateral laterothoracic exanthem of childhood*.¹³³ Brunner wrote to Bodemer regarding his finding. Both agreed that these are the same or very similar rashes (Bodemer, personal communication). Taïeb *et al.* subsequently reported 21 patients with a very similar eruption in France, which they termed *unilateral laterothoracic exanthem*.¹³⁴ They believe that ULE is related to viral infections (Taïeb, personal communication).

These independent discoveries lend authenticity to each other, supporting APE/ULE being caused by an infectious agent.

The diagnosis of APE/ULE is clinical. Lesional histopathological changes are largely unspecific, although perisudoral lymphocytic infiltrates (Figure 3B) have been reported to be a fairly specific feature for APE/ULE/UME.

Subsequent multi-continental patient reports and laboratory evidence

More than 300 patients with APE/ULE have been reported globally.¹³⁵⁻¹⁶⁰ In most reported patients, no viral cause was identified.^{135,137,138,140,147} Associated viruses include B19V,^{141,147,154,155} parainfluenza virus 2,¹⁴⁷ parainfluenza 3,¹⁴⁷ and adenovirus.¹⁴² However, many reports fall short of having applied sufficient investigations.¹⁶¹

Age

APE/ULE mostly occurs in infancy to young childhood under four years of age,^{132-135,140,153} with the youngest being four months of age.¹⁵⁸ Only 11 adults were diagnosed as having APE/ULE or its variants.^{139,143,144,146,148,149,151-154,160} Two relatively young adults (aged 20 and 33 years) and one child (aged four years and nine months) have been reported to have a variant which we termed *unilateral mediathoracic exanthem* (UME).^{144,149} Overall, the age distribution is compatible with primary viral infections.

Sex

The female-to-male ratio is around 2:1.^{125,127,137,148} The reason for this uneven distribution is unknown.

Seasonal variation

APE/ULE has a predilection to occur in the spring and summer months.^{134,137,138,144,149} All three patients with UME occurred in early spring.^{144,149} Such as evidence is indirect only, as non-infectious diseases might also exhibit seasonal variations.⁵⁷

Association with respiratory tract infections

APE/ULS was reported to be associated with

upper respiratory tract infections.^{140,142} A viral-like prodrome also supports a viral etiology.^{137,159}

Association with immunodeficiencies

APE/ULS was reported to be associated with immunodeficiencies such as during chemotherapy for leukaemia.^{141,157}

Analyses

APE/ULE is almost universally seen. The age of patients and concurrent patients support infectious etiologies. Statistically significant patient clustering has not been reported. We consider that the epidemiological evidence is adequate to substantiate an infectious etiology.

Papular-purpuric gloves and socks syndrome

History

PPGSS was first reported by Harms *et al.* for five young adults with swollen and pruritic hands and feet in 1990 in Switzerland.¹⁶² The borders of affected and normal skin were distinct.¹⁶³ The initial papules turned purpuric one or two weeks later, followed by spontaneous remission.

Subsequent laboratory findings and multi-continental patient reports

Three patients with PPGSS and B19V infection as substantiated by seroconversion were reported in Israel.¹⁶³ This association was subsequently confirmed in Saudi Arabia,¹⁶⁴ Serbia,¹⁶⁵ Greece,¹⁶⁶ Italy,¹⁶⁷⁻¹⁶⁹ Spain,¹⁷⁰ and Switzerland.¹⁷¹

PPGSS has then been reported to be associated with CMV,^{172,173} Coxsackie virus B6,¹⁷⁴ EBV,¹⁷³ HBV,^{175,176} HHV-6,¹⁷⁷ HIV,¹⁷⁸ measles virus,¹⁷⁹ and rubella virus¹⁸⁰ infections. Coinfections of HHV-6 and B19V,¹⁸¹ HHV-7 and B19V^{182,183} were also reported in patients with PPGSS. PPGSS co-existed Henoch-Schönlein purpura in a teenager in the US.¹⁸⁴ Such multi-continental distribution supports an infectious etiology.

Age and sex

A significant proportion of patients with PPGSS are adults^{171,185-190} or young adults.¹⁹¹⁻¹⁹³ Sexual preponderance is not seen. Age and sex offer little weight in sizing PPGSS as a viral exanthema.

Infectivity upon rash eruption

Patients with PPGSS related to B19V infec-

tion incur high infectivity by air-borne droplets. An epidemiological concern is that while *erythema infectiosum* is not infectious by the time the rash erupts, PPGSS as caused by B19V is still infectious when the rash erupts.¹⁹⁴

Concurrent patients

Reports of concurrent patients over some support for an infectious aetiology for this exanthema.^{164,186,187}

Patient-clustering and epidemics

Statistically significant patient-clustering and epidemics have not been reported for PPGSS. Such may be related to a low incidence of this exanthema.

Analyses

PPGSS is almost universal. Concurrent patients are reported. However, most patients are adults or young adults, and no clustering or epidemics has been reported. The epidemiological evidence is marginally adequate for an infectious cause only.

Eruptive pseudoangiomatosis

History and universality

EP was first described by Cherry *et al.* in 1969 in the US.¹⁹⁷ Based on its clinical course with spontaneous remission, the investigators suspected infectious etiologies. Prose *et al.* subsequently described three children with angioma-like or telangiectatic papules during viral illnesses in 1993.¹⁹⁸ The papules are blanchable, with the appearance being akin to cherry angiomas. However, lesional histopathological examinations revealed no blood vessel proliferation. This eruption was thus termed *pseudoangiomatosis*.

Subsequent multi-continental patient reports

The initial patients with EP were believed to be caused by echovirus infection.¹⁹⁷ Subsequent laboratory findings were equivocal. A single microbiological cause has not been found.

Patients with EP were then reported in Argentina,¹⁹⁹ France,²⁰⁰⁻²⁰⁴ Greece,²⁰⁵ Italy,²⁰⁶⁻²¹⁰ Japan,²¹¹ Korea,^{203,212} Spain,^{214,215} and the US.²¹⁶

Age and sex

EP has been reported for all ages, from neonates,²⁰³ infants,²⁰³ children,^{197-199,206,208,216} adults,^{199-202,204,209-214} to the elderlies.^{211,213,214} This wide range of age argues against a single virological cause. Sexual preponderance has not been reported for EP.

Subsequent laboratory results

Some patients with EP were reported to be associated with echovirus¹⁹⁷ and CMV²¹⁵ infections. However, most patients with EP had no infectious etiology confirmed.

Insect bites and other associating factors

EP was reported to be associated with insect bites^{210,211,213} and with immunocompromising states, such as post-renal transplant on immunosuppressive agents,²⁰¹ pemphigus vulgaris on systemic corticosteroids,²⁰⁵ and chemotherapy for Hodgkin lymphoma.²¹⁵ These reports suggest that EP might be the final common pathway by multiple factors which are remotely related to each other otherwise.²⁰⁷

Other reported associations include recent hospitalization for treating malignancies or asthma.^{200,203} The significance for these associations are yet to be established.

Seasonal variation

Seasonal variation for EP was reported in one study only, for which all seven patients developed EP during spring and summer.²¹⁴

Familial and concurrent patients

There are reports on members in the same family with concomitant EP.^{202,203,213}

Epidemics

Outbreaks of EP have been reported in France²⁰⁴ and Italy.²⁰⁹

Analyses

EP is multi-continental, with concurrent patients and epidemics reported. However, most patients are adults, for whom no reason is found. It is associated with insect bites, immunodeficiencies, and hospitalization for the treatment of cancer or asthma. We therefore believe that the current epidemiological evidence is inadequate to substantiate or refute an infectious cause. Although the monomorphous and blanchable lesions are highly characteristic, EP might be the final common pathway for multiple unrelated origins, with subsequent very similar immunopathological, histopathological, and clinical features.

Eruptive hypomelanosis

History

EH is a novel paraviral exanthema.²¹⁷⁻²²⁰ Most reported patients are young children below the age of six. After a stage of prodromal symptoms, monomorphous hypopigmented papules of around 3-5 mm appear mainly on

the extensor surfaces of the limbs (Figure 4). Systemic involvements including pharyngitis and lymphadenitis are common.²¹⁷

Age and sex

For the 14 patients which have been reported,²¹⁷⁻²²⁰ the youngest is a male child aged one year and six months. The oldest is a male aged nine years. The mean age was 4.57 years (standard deviation: 2.25 years). Ten were males and four were females. This distribution is not statistically significant (RR: 0.57; 95%CI: 0.21-1.52).

Clinical evidence

EH was suspected to be caused by a virus owing to prodromal symptoms, eruption of crops of monomorphous cutaneous lesions, concomitant systemic symptoms, and spontaneous rash remission.²¹⁷

Familial and concurrent patients, mini-epidemic

Concomitant eruption of the EH in three siblings in the same family has been reported.²²⁰ This is a *mini-epidemic* according to the conventional use of the term.^{88,89} Other clinical, laboratory, and epidemiological evidences await accumulation of more knowledge for this exanthema.

Analyses

Most patients with EH are young children. We have reported a mini-epidemic which is also interfamilial. Children with EH are seen in India and in Hong Kong only in the time being. To our best knowledge, several other investigators are attempting to report children with EH. The total number of diagnosed patients is only around 20 by the time this article is being written. We therefore judge that the epidemiological data is insufficient to support an infectious etiology. It is imminent to investigate these children virologically.

Discussion

As mentioned above, we lack a yardstick to judge the adequacies of epidemiology data to support infectious etiologies, unlike virological evidences which could be more quantitative. We therefore adopted a qualitative approach, analyzing epidemiological data as reported in the literature.

However, most of such data were reported in specialist settings, which could be biased in favor of patients with more severe symptoms, more extensive rashes, longer rash durations, systemic involvements, and complications.

These exanthema are community diseases, with spontaneous remission and low risk of

complications. The best proxy measure might therefore be data from primary care practices. To get such data, we might train a group of primary care clinicians to diagnose and report on these rashes. We believe that with the advancement of information technology, it is feasible to study these rashes in community as well as in specialist settings.

EH is not yet discovered and reported beyond Asia. We still incorporated such in this article owing to historical accounts of other paraviral exanthema. For PR, the first description of this exanthema was in 1860, while the herald patch was discovered in 1887, which was 27 years later.¹⁷ APE/ULE was initially reported by Brunner *et al.* in 1962.¹³² It took 30 years for Bodemer and de Prost to re-discover this rash in 1992,¹³³ and 31 years for Taïeb *et al.* to report this rash independently in 1993.¹³⁴

Therefore, there lies every possibility that we have reported EH now in several publications, followed by no further patients with EH reported for years and decades, then EH to be re-discovered by other investigators, as we learned from histories of discovery for other paraviral exanthema.

Limitations

A major limitation in this review is that owing to restraints in our resources, we limited our search to PubMed only. We did not search other databases such as EMBASE or LILACS for journals not indexed in PubMed, nor did we hand-search conference proceedings and unpublished reports by investigators whom we knew and who have special interests in the paraviral exanthema. We did not search the referenced lists of our retrieved articles. As most parameters are qualitative, forest plots are inapplicable for meta-analyses. Funnel plots to evaluate the extents of publication bias are also inapplicable in our analyses.

Another major limitation in our report is the lack of control conditions. For example, we could have chosen six infectious skin diseases, six non-infectious skin diseases, six infectious diseases of other body systems, and six non-infectious diseases of other body systems, and to have the epidemiology data of these diseases compared to the epidemiology data of the paraviral exanthema.

Moreover, in this article relates to the inherent nature of the epidemiological approaches. Virological properties including latent infection, endogenous reactivation, chromosomal integration (for HHV-6), multiple viral infections, and virus-virus interactions could render epidemiological methods to be futile pursuits in confirming or refuting etiologies for some or all of these exanthema.

Conclusions

The current epidemiological data supports,

to a moderate extent, that PR, GCS, and APE could be caused by infectious. The epidemiological evidence of PPGSS is marginally adequate to support an infectious cause. For EP, the epidemiological evidence is scattered to unrelated factors, only some of which being microbial infections. The epidemiological evidence of EH is inadequate to substantiate or to refute an infectious etiology. We hope that growing evidence in the future would further substantiate or refute the results of our analyses.

References

- Drago F, Vecchio F, Rebora A. Use of high-dose acyclovir in pityriasis rosea. *J Am Acad Dermatol* 2006;54:82-5.
- Das A, Sil A, Das NK, et al. Acyclovir in pityriasis rosea: an observer-blind, randomized controlled trial of effectiveness, safety and tolerability. *Indian Dermatol Online J* 2015;6:181-4.
- Pandhi D, Singal A, Verma P, Sharma R. The efficacy of azithromycin in pityriasis rosea: a randomized, double-blind, placebo-controlled trial. *Indian J Dermatol Venereol Leprol* 2014;80:36-40.
- Molinari N, Bonaldi C, Daurès JP. Multiple temporal cluster detection. *Biometrics* 2001;57:577-83.
- Smieszek T, Fiebig L, Scholz RW. Models of epidemics: when contact repetition and clustering should be included. *Theor Biol Med Model* 2009;6:11.
- Cochrane Informatics and Knowledge Management Department. RevMan. Available from: <http://tech.cochrane.org/revman>. Accessed on 15 January 2016.
- Sedgwick P, Marston L. How to read a funnel plot in a meta-analysis. *BMJ* 2015;351:h4718.
- Shah N, Andrade C. A simple rearrangement can improve visual understanding of a Forest plot. *Indian J Psychiatry* 2015;57:313-4.
- Chuh A, Zawar V, Sciallis G, Lee A. The diagnostic criteria of pityriasis rosea and Gianotti-Crosti syndrome – a protocol to establish diagnostic criteria of skin diseases *J R Coll Physicians Edinb* 2015;45:218-25.
- Steering Committee. European Dermato-Epidemiological Network – EDEN. Available from: <http://eden.dermis.net/>. Accessed on 15 January 2016.
- Rivers TM. Viruses and Koch's postulates. *J Bacteriol* 1937;33:1-12.
- Chuh AA, Chan HH, Zawar V. Is human herpesvirus 7 the causative agent of pityriasis rosea? – a critical review. *Int J Dermatol* 2004;43:870-5.
- Fredericks DN, Relman DA. Sequence-based identification of microbial pathogens: a reconsideration of Koch's postulates. *Clin Microbiol Rev* 1996;9:18-33.
- Hill AB. The environment and disease: association or causation? *Proc Royal Soc Med* 1965;58:295-300.
- Chuh AA, Au TS. Pityriasis rosea – a review of the specific treatments. *Proc R Coll Physicians Edinb* 2001;31:203-7.
- Chuh AA, Dofitas BL, Comisel GG, et al. Interventions for pityriasis rosea. *Cochrane Database Syst Rev* 2007;CD005068.
- Chuh A, Lee A, Zawar V, et al. A qualitative study on the historical aspects of pityriasis rosea – revelations on future directions of research. *Hong Kong J Dermatol Venereol* 2005;13:200-8.
- Abercrombie GF. Pityriasis rosea. *Proc R Soc Med* 1962;55:556-7.
- Vollum DI. Pityriasis rosea in the African. *Trans St Johns Hosp Dermatol Soc* 1973;059:269-71.
- Jacyk WK. Pityriasis rosea in Nigerians. *Int J Dermatol* 1980;19:397-9.
- Messenger AG, Knox EG, Summerly R, et al. Case clustering in pityriasis rosea: support for role of an infective agent. *Br Med J (Clin Res Ed)* 1982;284:371-3.
- Chuang TY, Ilstrup DM, Perry HO, et al. Pityriasis rosea in Rochester, Minnesota, 1969 to 1978. *J Am Acad Dermatol* 1982;7:80-9.
- de Souza Sittart JA, Tayah M, Soares Z. Incidence pityriasis rosea of Gibert in the Dermatology Service of the Hospital do Servidor Publico in the state of Sao Paulo. *Med Cutan Ibero Lat Am* 1984;12:336-8.
- Ahmed MA. Pityriasis rosea in the Sudan. *Int J Dermatol* 1986;25:184-5.
- Olumide Y. Pityriasis rosea in Lagos. *Int J Dermatol* 1987;26:234-6.
- Giam YC. Skin diseases in children in Singapore. *Ann Acad Med Singapore* 1988;17:569-72.
- Cheong WK, Wong KS. An epidemiological study of pityriasis rosea in Middle Road Hospital. *Singapore Med J* 1989;30:60-2.
- Harman M, Aytekin S, Akdeniz S, et al. An epidemiological study of pityriasis rosea in the Eastern Anatolia. *Eur J Epidemiol* 1998;14:495-7.
- Nanda A, Al-Hasawi F, Alsaleh QA. A prospective survey of pediatric dermatology clinic patients in Kuwait: an analysis of 10,000 cases. *Pediatr Dermatol* 1999;16:6-11.
- Tay YK, Goh CL. One-year review of pityriasis rosea at the National Skin Centre, Singapore. *Ann Acad Med Singapore* 1999;28:829-31.
- Traore A, Korsaga-Some N, Niamba P, et al. Pityriasis rosea in secondary schools in Ouagadougou, Burkina Faso. *Ann Dermatol Venereol* 2001;128:605-9.
- Kyriakis KP, Palamaras I, Terzoudi S, et al. Epidemiologic characteristics of pityriasis rosea in Athens Greece. *Dermatol Online J* 2006;12:24.
- Sharma L, Srivastava K. Clinicoepidemiological study of pityriasis rosea. *Indian J Dermatol Venereol Leprol* 2008;74:647-9.
- Ayanlowo O, Akinkugbe A, Olumide Y. The pityriasis rosea calendar: a 7 year review of seasonal variation, age and sex distribution. *Nig Q J Hosp Med* 2010;20:29-31.
- Ganguly S. A clinicoepidemiological study of pityriasis rosea in South India. *Skinmed* 2013;11:141-6.
- Özyürek GD, Alan S, Cenesiz lu E. Evaluation of clinico-epidemiological and histopathological features of pityriasis rosea. *Postepy Dermatol Alergol* 2014;31:216-21.
- Miranda SM, Porto LC, Pontes LF, et al. Correlation between HLA and pityriasis rosea susceptibility in Brazilian blacks. *J Eur Acad Dermatol Venereol* 2006;20:21-6.
- Wikipedia. List of countries by GDP (nominal) per capita. Available from: [en.wikipedia.org/wiki/List_of_countries_by_GDP_\(nominal\)_per_capita](http://en.wikipedia.org/wiki/List_of_countries_by_GDP_(nominal)_per_capita). Accessed on 6 May 2015.
- Hendricks AA, Lohr JA. Pityriasis rosea in infancy. *Arch Dermatol* 1979;115:896-7.
- Truhan AP. Pityriasis rosea. *Am Fam Physician* 1984;29:193-6.
- Chuh AA, Peiris JS. Lack of evidence of active human herpesvirus 7 (HHV-7) infection in three cases of pityriasis rosea in children. *Pediatr Dermatol* 2001;18:381-3.
- Chuh AA, Chiu SS, Peiris JS. Human herpesvirus 6 and 7 DNA in peripheral blood leucocytes and plasma in patients with pityriasis rosea by polymerase chain reaction: a prospective case control study. *Acta Derm Venereol* 2001;81:289-90.
- Chuh AA, Chan PK, Lee A. The detection of human herpesvirus-8 DNA in plasma and peripheral blood mononuclear cells in adult patients with pityriasis rosea by polymerase chain reaction. *J Eur Acad Dermatol Venereol* 2006;20:667-71.
- Chuh AA. The association of pityriasis rosea with cytomegalovirus, Epstein-Barr virus and parvovirus B19 infections - a prospective case control study by polymerase chain reaction and serology. *Eur J Dermatol* 2002;12:170-3.
- Drago F, Broccolo F, Javor S, et al. Evidence of human herpesvirus-6 and -7 reactivation in miscarrying women with pityriasis rosea. *J Am Acad Dermatol* 2014;71:198-9.
- Stoverinck MJ, Lagro-Janssen AL, Weel CV. Sex differences in health problems, diag-

- nostic testing, and referral in primary care. *J Fam Pract* 1996;43:567-76.
47. Björnberg A, Hellgren L. Pityriasis rosea. A statistical, clinical and laboratory investigation of 826 patients and matched healthy controls. *Acta Derm Venereol* 1962;42:1-50.
 48. Drago F, Ciccarese G, Rebora A, et al. Relapsing pityriasis rosea. *Dermatology* 2014;229:316-8.
 49. Miller TH. Pityriasis rosea: report of three cases in one family with clinical variations in two of them. *Arch Dermatol Syph* 1941;44:66-8.
 50. Lemster N, Neumark M, Ariei I. Pityriasis rosea in a woman and her husband - case report and review of the literature. *Case Rep Dermatol* 2010;2:135-9.
 51. White W. Pityriasis rosea in sisters. *Br Med J* 1973;2:245.
 52. Davies SWV. Case clustering in pityriasis rosea: support for role of an infective agent. *Br Med J (Clin Res Ed)* 1982;284:1478.
 53. Bosc F. Is pityriasis rosea infectious? *Lancet* 1981;1:662.
 54. Chuh A, Lee A, Molinari N. Case clustering in pityriasis rosea – a multi-center epidemiologic study in primary care settings in Hong Kong. *Arch Dermatol* 2003;139:489-93.
 55. Chuh A, Molinari N, Sciallis G, et al. Temporal case clustering in pityriasis rosea – a regression analysis on 1,379 patients in Minnesota, Kuwait and Diyarbakır, Turkey. *Arch Dermatol* 2005;141:767-71.
 56. Chuang TY, Perry HO, Ilstrup DM, et al. Recent upper respiratory tract infection and pityriasis rosea: a case-control study of 249 matched pairs. *Br J Dermatol* 1983;108:587-91.
 57. Hannan MA, Rahman MM, Haque A, Ahmed HU. Stroke: seasonal variation and association with hypertension. *Bangladesh Med Res Counc Bull* 2001;27:69-78.
 58. Drago F, Ranieri E, Malaguti F, et al. Human herpesvirus 7 in pityriasis rosea. *Lancet* 1997;349:1367-8.
 59. Drago F, Malaguti F, Ranieri E, et al. Human herpes virus-like particles in pityriasis rosea lesions: an electron microscopy study. *J Cutan Pathol* 2002;29:359-61.
 60. Broccolo F, Drago F, Careddu AM, et al. Additional evidence that pityriasis rosea is associated with reactivation of human herpesvirus-6 and -7. *J Invest Dermatol* 2005;124:1234-40.
 61. Drago F, Broccolo F, Javor S, et al. Evidence of human herpesvirus-6 and -7 reactivation in miscarrying women with pityriasis rosea. *J Am Acad Dermatol* 2014;71:198-9.
 62. Drago F, Broccolo F, Ciccarese G, et al. Persistent pityriasis rosea: an unusual form of pityriasis rosea with persistent active HHV-6 and HHV-7 infection. *Dermatology* 2015;230:23-6.
 63. Watanabe T, Kawamura T, Jacob SE, et al. Pityriasis rosea is associated with systemic active infection with both human herpesvirus-7 and human herpesvirus-6. *J Invest Dermatol* 2002;119:793-7.
 64. Kempf W, Adams V, Kleinhans M, et al. Pityriasis rosea is not associated with human herpesvirus 7. *Arch Dermatol* 1999;135:1070-2.
 65. Yoshida M. Detection of human herpesvirus 7 in patients with pityriasis rosea and healthy individuals. *Dermatology* 1999;199:197-8.
 66. Karabulut AA, Koçak M, Yilmaz N, Eksioğlu M. Detection of human herpesvirus 7 in pityriasis rosea by nested PCR. *Int J Dermatol* 2002;41:563-7.
 67. Yildirim M, Aridogan BC, Baysal V, Inaloz HS. The role of human herpes virus 6 and 7 in the pathogenesis of pityriasis rosea. *Int J Clin Pract* 2004;58:119-21.
 68. Chuh A, Chan H, Zawar V. Pityriasis rosea – evidence for and against an infectious aetiology. *Epidemiol Infect* 2004;132:381-90.
 69. Kempf W. Human herpesvirus 7 in dermatology: what role does it play? *Am J Clin Dermatol* 2002;3:309-15.
 70. Kaufer BB, Flamand L. Chromosomally integrated HHV-6: impact on virus, cell and organismal biology. *Curr Opin Virol* 2014;9:111-8.
 71. Chuh A, Zawar V, Law M, Sciallis G. Gianotti-Crosti syndrome, pityriasis rosea, asymmetrical perilesional exanthem, unilateral mediastinal exanthem, eruptive pseudoangiomatosis, and papular-purpuric gloves and socks syndrome: a brief review and arguments for diagnostic criteria. *Infect Dis Rep* 2012;4:e12.
 72. Gianotti F. Rilievi di una particolare casistica tossinfettiva caratterizzata da eruzione eritemato-infiltrativa desquamativa a focolai lenticolari, a sede elettiva acroesposta. *Giornale italiano di dermatologia e sifilologia. G Ital Dermatol* 1955;96:678-97.
 73. Crosti A, Gianotti F. Dermatosis infantile eruttiva acroesposta di probabile origine virale. *Minerva Dermatol* 1956;31:483.
 74. Crosti A, Gianotti F. Dermatose eruttive acro-située d'origine probable virale. *Acta Derm Venereol* 1957;2:146-9.
 75. Crosti A, Gianotti F. Eruptive dermatosis of probable viral origin situated on the acra. *Dermatologica* 1957;115:671-7.
 76. Brandt O, Abeck D, Gianotti R, et al. Gianotti-Crosti syndrome. *J Am Acad Dermatol* 2006;54:136-45.
 77. Chuh AA. Diagnostic criteria for Gianotti-Crosti syndrome: a prospective case-control study for validity assessment. *Cutis* 2001;68:207-13.
 78. Chuh A, Lee A, Zawar V. The diagnostic criteria of Gianotti-Crosti syndrome: are they applicable to children in India? *Pediatr Dermatol* 2004;21:542-7.
 79. Chuh A. Gianotti-Crosti syndrome associated with endogenous reactivation of Epstein-Barr virus. *Dermatology* 2004;208:363.
 80. Gianotti F. L'acrodermatite papulosa infantile malattia. *Gazz Sanit* 1970;41:271-4.
 81. De Gaspari G, Bardare M, Costantino D. An antigen in Crosti-Gianotti acrodermatitis. *Lancet* 1970;1:1116-7.
 82. Demattei C, Zawar V, Lee A, et al. Spatial-temporal case clustering in children with Gianotti-Crosti syndrome. Systematic analysis led to the identification of a mini-epidemic. *Eur J Pediatr Dermatol* 2006;16:159-64.
 83. Ishimaru Y, Ishimaru H, Toda G, et al. An epidemic of infantile papular acrodermatitis (Gianotti's disease) in Japan associated with hepatitis-B surface antigen subtype ayw. *Lancet* 1976;1:707-9.
 84. Toda G, Ishimaru Y, Mayumi M, et al. Infantile papular acrodermatitis (Gianotti's disease) and intrafamilial occurrence of acute hepatitis B with jaundice: age dependency of clinical manifestations of hepatitis B virus infection. *J Infect Dis* 1978;138:211-6.
 85. Kanzaki S, Kanda S, Terada K, et al. Detection of hepatitis B surface antigen subtype adr in an epidemic of papular acrodermatitis of childhood (Gianotti's disease). *Acta Med Okayama* 1981;35:407-10.
 86. Ono E. Natural history of infantile papular acrodermatitis (Gianotti's disease) with HBsAg subtype adw. *Kurume Med J* 1988;35:147-57.
 87. Baldari U, Monti A, Righini MG. An epidemic of infantile papular acrodermatitis (Gianotti-Crosti syndrome) due to Epstein-Barr virus. *Dermatology* 1994;188:203-4.
 88. Segal RL, Fiedler R, Jacobs DR, Antrobus J. Case report. Mini-epidemic of thyrotoxicosis occurring in physicians. *Am J Med Sci* 1976;271:55-7.
 89. Tomb RR, Fousseau J, Sell Y. Mini-epidemic of contact dermatitis from ginkgo tree fruit (*Ginkgo biloba* L.). *Contact Dermatitis* 1988;19:281-3.
 90. Eto T, Shiraki K. National project on the prevention of mother-to-infant infection by hepatitis B virus in Japan. *Acta Paediatr Jpn* 1989;31:681-4.
 91. Hayashi J, Kashiwagi S, Nomura H, et al. Hepatitis B virus transmission in nursery

- schools. *Am J Epidemiol* 1987;125:492-8.
92. Spear KL, Winkelman RK. Gianotti-Crosti syndrome. A review of ten cases not associated with hepatitis B. *Arch Dermatol* 1984;120:891-6.
 93. Ehringhaus C, Happle R, Dominick HC, et al. Gianotti-Crosti syndrome. HBsAg-negative papular acrodermatitis, an infantile papulovesicular acrolocalized syndrome. *Monatsschr Kinderheilkd* 1985;133:111-3.
 94. Eiloart M. The Gianotti-Crosti syndrome. *Br J Dermatol* 1966;78:488-92.
 95. Taïeb A, Plantin P, Du Pasquier P, et al. Gianotti-Crosti syndrome: a study of 26 cases. *Br J Dermatol* 1986;115:49-59.
 96. Ruiz de Erenchun F, Román J, Villaizán C, et al. Syndrome of Gianotti-Crosti associated with hepatitis caused by the Coxsackie B4 virus]. *Med Clin (Barc)* 1992;99:195.
 97. James WD, Odom RB, Hatch MH. Gianotti-Crosti-like eruption associated with coxsackievirus A-16 infection. *J Am Acad Dermatol* 1982;6:862-6.
 98. Berant M, Naveh Y, Weissman I. Papular acrodermatitis with cytomegalovirus hepatitis. *Arch Dis Child* 1983;58:1024-5.
 99. Tzeng GH, Hsu CY, Chen HC. Gianotti-Crosti syndrome associated with cytomegalovirus infection: report of one case. *Zhonghua Min Guo Xiao Er Ke Yi Xue Hui Za Zhi* 1995;36:139-41.
 100. Haki M, Tsuchida M, Kotsuji M, et al. Gianotti-Crosti syndrome associated with cytomegalovirus antigenemia after bone marrow transplantation. *Bone Marrow Transplant* 1997;20:691-3.
 101. Baleviciene G, Maciuleviciene R, Schwartz RA. Papular acrodermatitis of childhood: the Gianotti-Crosti syndrome. *Cutis* 2001;67:291-4.
 102. Draeos ZK, Hansen RC, James WD. Gianotti-Crosti syndrome associated with infections other than hepatitis B. *JAMA* 1986;256:2386-8.
 103. Pouillaude JM, Moulin G, Morlat C, et al. Gianotti-Crosti's infantile papular acrodermatitis. Nosological relationship with viral hepatitis. A fatal outcome. *Pediatr* 1975;30:351-60.
 104. Sagi EF, Linder N, Shouval D. Papular acrodermatitis of childhood associated with hepatitis A virus infection. *Pediatr Dermatol* 1985;3:31-3.
 105. Dauendorffer JN, Dupuy A. Gianotti-Crosti syndrome associated with herpes simplex virus type 1 gingivostomatitis. *J Am Acad Dermatol* 2011;64:450-1.
 106. Chuh AA, Chan HH, Chiu SS, et al. A prospective case control study of the association of Gianotti-Crosti syndrome with human herpesvirus 6 and human herpesvirus 7 infections. *Pediatr Dermatol* 2002;19:492-7.
 107. Yasumoto S, Tsujita J, Imayama S, et al. Case report: Gianotti-Crosti syndrome associated with human herpesvirus-6 infection. *J Dermatol* 1996;23:499-501.
 108. Blauvelt A, Turner ML. Gianotti-Crosti syndrome and human immunodeficiency virus infection. *Arch Dermatol* 1994;130:481-3.
 109. Stratte EG, Esterly NB. Human immunodeficiency virus and the Gianotti-Crosti syndrome. *Arch Dermatol* 1995;131:108-9.
 110. May J, Pollack R. Gianotti-Crosti syndrome associated with type A influenza. *Pediatr Dermatol* 2011;28:733-5.
 111. Hergueta Lendínez R, Pozo García L, Alejo García A, et al. Gianotti-Crosti syndrome due to a mixed infection produced by the mumps virus and the parainfluenza virus type 2. *An Esp Pediatr* 1996;44:65-6.
 112. Boeck K, Mempel M, Schmidt T, et al. Gianotti-Crosti syndrome: clinical, serologic, and therapeutic data from nine children. *Cutis* 1998;62:271-4.
 113. Léger F, Callens A, Machet MC. Parvovirus B19 primo-infection and cold agglutinins. *Ann Dermatol Venereol* 1997;124:257-9.
 114. Carrascosa JM, Just M, Ribera M, et al. Papular acrodermatitis of childhood related to poxvirus and parvovirus B19 infection. *Cutis* 1998;61:265-7.
 115. de la Torre C. Gianotti-Crosti syndrome following milkers' nodules. *Cutis* 2004;74:316-8.
 116. Di Lernia V. Gianotti-Crosti syndrome related to rotavirus infection. *Pediatr Dermatol* 1998;15:485-6.
 117. Di Lernia V, Mansouri Y. Epstein-Barr virus and skin manifestations in childhood. *Int J Dermatol* 2013;52:1177-84.
 118. Atanasovski M, Dele-Michael A, Dasgeb B, et al. A case report of Gianotti-Crosti post vaccination with MMR and dTaP. *Int J Dermatol* 2011;50:609-10.
 119. Retrouvey M, Koch LH, Williams JV. Gianotti-Crosti syndrome after childhood vaccination. *Pediatr Dermatol* 2012;29:666-8.
 120. Retrouvey M, Koch LH, Williams JV. Gianotti-Crosti syndrome following childhood vaccinations. *Pediatr Dermatol* 2013;30:137-8.
 121. Monastirli A, Varvarigou A, Pasmazi E, et al. Gianotti-Crosti syndrome after hepatitis A vaccination. *Acta Derm Venereol* 2007;87:174-5.
 122. Kolivras A, André J. Gianotti-Crosti syndrome following hepatitis A vaccination. *Pediatr Dermatol* 2008;25:650.
 123. Sigmon JR, Venkatesh S, Leshner JL. Gianotti-Crosti syndrome associated with hepatitis A and influenza vaccination. *J Drugs Dermatol* 2012;11:260-1.
 124. Andiran N, Sentürk GB, Bükülmez G. Combined vaccination by measles and hepatitis B vaccines: a new cause of Gianotti-Crosti syndrome. *Dermatology* 2002;204:75-6.
 125. Karaka M, Durdu M, Tuncer I, et al. Gianotti-Crosti syndrome in a child following hepatitis B virus vaccination. *J Dermatol* 2007;34:117-120.
 126. Cambiaghi S, Scarabelli G, Pistrutto G, et al. Gianotti-Crosti syndrome in an adult after influenza virus vaccination. *Dermatology* 1995;191:340-1.
 127. Lam JM. Atypical Gianotti-Crosti syndrome following administration of the AS03-adjuvanted H1N1 vaccine. *J Am Acad Dermatol* 2011;65:127-8.
 128. Kroeskop A, Lewis AB, Barril FA, et al. Gianotti-Crosti syndrome after H1N1-influenza vaccine. *Pediatr Dermatol* 2011;28:595-6.
 129. Kang NG, Oh CW. Gianotti-Crosti syndrome following Japanese encephalitis vaccination. *J Korean Med Sci* 2003;18:459-61.
 130. Velangi SS, Tidman MJ. Gianotti-Crosti syndrome after measles, mumps and rubella vaccination. *Br J Dermatol* 1998;139:1122-3.
 131. Erkek E, Sentürk GB, Ozkaya O, et al. Gianotti-Crosti syndrome preceded by oral polio vaccine and followed by varicella infection. *Pediatr Dermatol* 2001;18:516-8.
 132. Brunner MJ, Rubin L, Dunlap F. A new papular erythema of childhood. *Arch Dermatol* 1962;85:539-40.
 133. Bodemer C, de Prost Y. Unilateral laterothoracic exanthem in children: a new disease? *J Am Acad Dermatol* 1992;27:693-6.
 134. Taïeb A, Mégraud F, Legrain V, et al. Asymmetric perilesional exanthem of childhood. *J Am Acad Dermatol* 1993;29:391-3.
 135. McCuaig CC, Russo P, Powell J, et al. Unilateral laterothoracic exanthem. A clinicopathologic study of forty-eight patients. *J Am Acad Dermatol* 1996;34:979-84.
 136. Mørtz CG, Bygum A. Asymmetric perilesional exanthema of childhood. *Ugeskr Laeger* 2000;162:2050-1.
 137. Coustou D, Léauté-Labrèze C, Bioulac-Sage P, et al. Asymmetric perilesional exanthem of childhood: a clinical, pathologic, and epidemiologic prospective study. *Arch Dermatol* 1999;135:799-803.
 138. Coustou D, Masquelier B, Lafon ME, et al. Asymmetric perilesional exanthem of childhood: microbiologic case-control study. *Pediatr Dermatol* 2000;17:169-73.
 139. Gutzmer R, Herbst RA, Kiehl P, et al. Unilateral laterothoracic exanthem (asymmetrical perilesional exanthem of childhood): report of an adult patient. *J Am Acad Dermatol* 1997;37:484-5.
 140. Peker S, Höger PH, Moll I. Unilateral lat-

- erotheracic exanthema. Case report and review of the literature. *Hautarzt* 2000;51:505-8.
141. Núñez Giralda A. Asymmetric periflexural exanthema: apropos of a case. *An Pediatr (Barc)* 2005;63:269-70.
 142. Niedermeier A, Pfützner W, Ruzicka T, et al. Superimposed lateralized exanthem of childhood: report of a case related to adenovirus infection. *Clin Exp Dermatol* 2014;39:351-3.
 143. Chan PK, To KF, Zawar V, et al. Asymmetric periflexural exanthem in an adult. *Clin Exp Dermatol* 2004;29:320-1.
 144. Chuh AAT, Chan HHL. Unilateral mediothoracic exanthem – a variant of unilateral laterothoracic exanthem – original description of two patients. *Cutis* 2006;77:29-32.
 145. Zawar V, Chuh A. Unilateral laterothoracic exanthem with coincident evidence of Epstein-Barr virus reactivation: exploration of a possible link. *Dermatol Online J* 2008;14:24.
 146. Chuh A. Asymmetric periflexural exanthem / unilateral laterothoracic exanthem related to parvovirus B19 infection – an adult carrier of β -globin thalassaemia gene mutation in Hong Kong. *Australas J Dermatol* 2016;57 [in press].
 147. Harangi F, Varszegi D, Szucs G. Asymmetric periflexural exanthem of childhood and viral examinations. *Pediatr Dermatol* 1995;12:112-5.
 148. Zawar VP. Asymmetric periflexural exanthema: a report in an adult patient. *Indian J Dermatol Venereol Leprol* 2003;69:401-4.
 149. Chuh A, Zawar V. Unilateral mediothoracic exanthem – Report of the third patient in the literature. *Int J Trop Dis Health* 2016;14 [in press].
 150. Gelmetti C, Grimalt R, Cambiaghi S, Caputo R. Asymmetric periflexural exanthem of childhood: report of two new cases. *Pediatr Dermatol* 1994;11:42-5.
 151. Corazza M, Virgili A. Asymmetric periflexural exanthem in an adult. *Acta Derm Venereol* 1997;77:79-80.
 152. Pauluzzi P, Festini G, Gelmetti C. Asymmetric periflexural exanthem of childhood in an adult patient with parvovirus B19. *J Eur Acad Dermatol Venereol* 2001;15:372-4.
 153. Duarte AF, Cruz MJ, Baudrier T, et al. Unilateral laterothoracic exanthem and primary Epstein-Barr virus infection: case report. *Pediatr Infect Dis J* 2009;28:549-50.
 154. Bauzá A, Redondo P, Fernández J. Asymmetric periflexural exanthem in adults. *Br J Dermatol* 2000;143:224-6.
 155. Guimerá-Martín-Neda F, Fagundo E, Rodríguez F, et al. Asymmetric periflexural exanthem of childhood: report of two cases with parvovirus B19. *J Eur Acad Dermatol Venereol* 2006;20:461-2.
 156. Arun B, Salim A. Transient linear eruption: asymmetric periflexural exanthem or blaschkitis. *Pediatr Dermatol* 2010;27:301-2.
 157. Fort DW, Greer KE. Unilateral laterothoracic exanthem in a child with acute lymphoblastic leukemia. *Pediatr Dermatol* 1998;15:51-2.
 158. Nahm WK, Paiva C, Golomb C, et al. Asymmetric periflexural exanthem of childhood: a case involving a 4-month-old infant. *Pediatr Dermatol* 2002;19:461-2.
 159. Lichon V, Khachemoune A. Left-sided eruption on a child: case study. *Dermatol Nurs* 2007;19:366-7.
 160. Scheinfeld N. Unilateral laterothoracic exanthema with coincident evidence of Epstein Barr virus reactivation: exploration of a possible link. *Dermatol Online J* 2007;13: 13.
 161. Chuh AAT. Pediatric viral exanthems. *Yearbook of dermatology and dermatologic surgery*. St. Louis: Mosby; 2005. pp 16-43.
 162. Harms M, Feldmann R, Saurat JH. Papular-purpuric gloves and socks syndrome. *J Am Acad Dermatol* 1990;23:850-4.
 163. Harel L, Straussberg I, Zeharia A, et al. Papular purpuric rash due to parvovirus B19 with distribution on the distal extremities and the face. *Clin Infect Dis* 2002;35:1558-61.
 164. Alfadley A, Aljubran A, Hainau B, et al. Papular-purpuric gloves and socks syndrome in a mother and daughter. *J Am Acad Dermatol* 2003;48:941-4.
 165. Pavlovi MD. Papular-purpuric gloves and socks syndrome caused by parvovirus B19. *Vojnosanit Pregl* 2003;60:223-5.
 166. Sklavounou-Andrikopoulou A, Iakovou M, Paikos S, et al. Oral manifestations of papular-purpuric gloves and socks syndrome due to parvovirus B19 infection: the first case presented in Greece and review of the literature. *Oral Dis* 2004;10:118-22.
 167. Manzi A, Saldutti MT, Battista A, et al. Papular purpuric gloves and socks syndrome. A case report. *Minerva Pediatr* 2004;56:227-9.
 168. Bilenchi R, De Paola M, Poggiali S, et al. Papular-purpuric gloves and socks syndrome. *G Ital Dermatol Venereol* 2012;147:119-21.
 169. Bello S, Fanizzi R, Bonali C, et al. Papular-purpuric gloves and socks syndrome due to parvovirus B19: a report of two simultaneous cases in cohabitant families. *Reumatismo* 2013;65:40-5.
 170. Elena-González A, Lozano-Durán C, Cuadros-Tito P, et al. Papular-purpuric gloves and socks syndrome and thrombocytopenia related to parvovirus B19 infection. *Enferm Infecc Microbiol Clin* 2014;32:61-2.
 171. Feldmann R, Harms M, Saurat JH. Papular-purpuric gloves and socks syndrome: not only parvovirus B19. *Dermatology* 1994;188:85-7.
 172. Carrascosa JM, Bielsa I, Ribera M, et al. Papular-purpuric gloves-and-socks syndrome related to cytomegalovirus infection. *Dermatology* 1995;191:269-70.
 173. Hsieh MY, Huang PH. The juvenile variant of papular-purpuric gloves and socks syndrome and its association with viral infections. *Br J Dermatol* 2004;151:201-6.
 174. Vargas-Díez E, Buezo GF, Aragües M, et al. Papular-purpuric gloves-and-socks syndrome. *Int J Dermatol* 1996;35:626-32.
 175. Guibal F, Buffet P, Mouly F, et al. Papular-purpuric gloves and socks syndrome with hepatitis B infection. *Lancet* 1996;347:473.
 176. Vélez A, Fernández-de-la-Puebla R, Moreno JC. Second case of papular-purpuric gloves-and-socks syndrome related to hepatitis B infection. *Br J Dermatol* 2001;145:515-6.
 177. Ruzicka T, Kalka K, Diercks K, et al. Papular-purpuric gloves and socks syndrome associated with human herpesvirus 6 infection. *Arch Dermatol* 1998;134:242-4.
 178. Ghigliotti G, Mazzarello G, Nigro A, et al. Papular-purpuric gloves and socks syndrome in HIV-positive patients. *J Am Acad Dermatol* 2000;43:916-7.
 179. Pérez-Ferriols A, Martínez-Aparicio A, Aliaga-Boniche A. Papular-purpuric gloves and socks syndrome caused by measles virus. *J Am Acad Dermatol* 1994;30:291-2.
 180. Seguí N, Zayas A, Fuertes A, et al. Papular-purpuric gloves-and-socks syndrome related to rubella virus infection. *Dermatology* 2000;200:89.
 181. Fretzayas A, Douros K, Moustaki M, et al. Papular-purpuric gloves and socks syndrome in children and adolescents. *Pediatr Infect Dis J* 2009;28:250-2.
 182. Ongvári J, Becker K, Horváth A, et al. Simultaneous infection by human herpesvirus 7 and human parvovirus B19 in papular-purpuric gloves-and-socks syndrome. *Arch Dermatol* 2000;136:672.
 183. Vág T, Sonkoly E, Kemény B, et al. Familiar occurrence of papular-purpuric gloves and socks syndrome with human herpes virus-7 and human parvovirus B19 infection. *J Eur Acad Dermatol Venereol* 2004;18:639-41.
 184. Hakim A. Concurrent Henoch-Schönlein purpura and papular-purpuric gloves-and-socks syndrome. *Scand J Rheumatol* 2000;29:131-2.
 185. Higashi N, Fukai K, Tsuruta D, et al. Papular-purpuric gloves-and-socks syndrome with bloody bullae. *J Dermatol* 2002;29:371-5.
 186. Calza L, Manfredi R, Chiodo F. Papular-purpuric gloves and socks syndrome associat-

- ed with parvovirus B19 in an adult female. *Presse Med* 2001;30:1354.
187. Passoni LF, Ribeiro SR, Giordani ML, et al. Papular-purpuric gloves and socks syndrome due to parvovirus B19: report of a case with unusual features. *Rev Inst Med Trop Sao Paulo* 2001;43:167-70.
 188. Ghigliotti G, Mazzarello G, Nigro A, et al. Papular-purpuric gloves and socks syndrome in HIV-positive patients. *J Am Acad Dermatol* 2000;43:916-7.
 189. Sklavounou-Andrikopoulou A, Iakovou M, Paikos S, et al. Oral manifestations of papular-purpuric gloves and socks syndrome due to parvovirus B19 infection: the first case presented in Greece and review of the literature. *Oral Dis* 2004;10:118-22.
 190. Schmid D, Gabbe D, Wolnik C, Pietruschka WD. A 28-year-old patient with exanthema on hands and feet. *Internist (Berl)* 2006;47:1284-6.
 191. Carlesimo M, Palese E, Mari E, et al. Gloves and socks syndrome caused by parvovirus B19 infection. *Dermatol Online J* 2006;12:19.
 192. Petter G, Rytter M, Hausteine UF. Juvenile papular-purpuric gloves and socks syndrome. *J Eur Acad Dermatol Venereol* 2001;15:340-2.
 193. Toyoshima MT, Keller LW, Barbosa ML, Durigon EL. Papular-purpuric gloves and socks syndrome caused by parvovirus B19 infection in Brazil: a case report. *Braz J Infect Dis* 2006;10:62-4.
 194. Tom WL, Friedlander SF. Viral exanthems. In: Harper's textbook of pediatric dermatology. 3rd ed. Irvine AD, Hoeger PH, Yan AC, eds. Oxford: John Wiley & Sons Ltd Publication; 2011. Chapter 49.
 195. Schmid D, Gabbe D, Wolnik C, et al. A 28-year-old patient with exanthema on hands and feet. *Internist (Berl)* 2006;47:1284-6.
 196. Martínez GMJ, Elgueta NA. A family outbreak of parvovirus B19 atypical exanthemas: report of two cases. *Rev Med Chil* 2008;136:620-3.
 197. Cherry JD, Bobinski JE, Horvath FL, et al. Acute hemangioma-like lesions associated with ECHO viral infections. *Pediatrics* 1969;44:498-502.
 198. Prose NS, Tope W, Miller SE, et al. Eruptive pseudoangiomatosis: a unique childhood exanthem? *J Am Acad Dermatol* 1993;29:857-9.
 199. Larralde M, Ballona R, Correa N, Schroh R, Coll N. Eruptive pseudoangiomatosis. *Pediatr Dermatol* 2002;19:76-7.
 200. Guillot B, Dandurand M. Eruptive pseudoangiomatosis arising in adulthood: 9 cases. *Eur J Dermatol* 2000;10:455-8.
 201. Mazereeuw-Hautier J, Cambon L, Bonafé JL. Eruptive pseudoangiomatosis in an adult renal transplant recipient. *Ann Dermatol Venereol* 2001;128:55-6.
 202. Stoeber PE, Templier I, Ligeron C, et al. Familial eruptive pseudoangiomatosis. *Dermatology* 2002;205:306-7.
 203. Guillot B, Chraïbi H, Girard C, et al. Eruptive pseudoangiomatosis in infant and newborns. *Ann Dermatol Venereol* 2005;132:966-9.
 204. Brouillard C, Guyot Caquelin P, Truchetet F. An outbreak of eruptive pseudoangiomatosis. *Ann Dermatol Venereol* 2012;139:684-5.
 205. Chaniotakis I, Nomikos K, Gamvroulia C, Zioga A, Stergiopoulou C, Bassukas ID. Eruptive pseudoangiomatosis: report of an adult case and unifying hypothesis of the pathogenesis of paediatric and adult cases. *Dermatology* 2007;215:59-62.
 206. González Enseñat MA, Vicente Villa MA, Castellá Badrinas NC, et al. Eruptive pseudoangiomatosis. A case report. *An Esp Pediatr* 1997;46:69-70.
 207. Neri I, Patrizi A, Guerrini V, et al. Eruptive pseudoangiomatosis. *Br J Dermatol* 2000;143:435-8.
 208. Angelo C, Proveni A, Ferranti G, et al. Eruptive pseudoangiomatosis. *Pediatr Dermatol* 2002;19:243-5.
 209. Venturi C, Zendri E, Medici MC, et al. Eruptive pseudoangiomatosis in adults: a community outbreak. *Arch Dermatol* 2004;140:757-8.
 210. Restano L, Cavalli R, Colonna C, et al. Eruptive pseudoangiomatosis caused by an insect bite. *J Am Acad Dermatol* 2005;52:174-5.
 211. Oka K, Ohtaki N, Kasai S, et al. Two cases of eruptive pseudoangiomatosis induced by mosquito bites. *J Dermatol* 2012;39:301-5.
 212. Yang JH, Kim JW, Park HS, et al. Eruptive pseudoangiomatosis. *J Dermatol* 2006;33:873-6.
 213. Kim JE, Kim BJ, Park HJ, et al. Clinicopathologic review of eruptive pseudoangiomatosis in Korean adults: report of 32 cases. *Int J Dermatol* 2013;52:41-5.
 214. Pérez-Barrio S, Gardeazábal J, Acebo E, et al. Eruptive pseudoangiomatosis: study of 7 cases. *Actas Dermosifiliogr* 2007;98:178-82.
 215. Pitarch G, Torrijos A, García-Escrivá D, Martínez-Menchón T. Eruptive pseudoangiomatosis associated to cytomegalovirus infection. *Eur J Dermatol* 2007;17:455-6.
 216. Henry M, Sava an S. Eruptive pseudoangiomatosis in a child undergoing chemotherapy for Hodgkin lymphoma. *Pediatr Blood Cancer* 2012;59:342-3.
 217. Zawar V, Bharatia P, Chuh A. Eruptive hypomelanosis – a novel exanthem associated with viral symptoms in children. *JAMA Dermatol* 2014;150:1197-201.
 218. Chuh A, Bharatia P, Zawar V. Eruptive hypomelanosis in a young child as a paraviral exanthem. *Pediatr Dermatol* 2016;33:e38-39.
 219. Bharatia P, Zawar V, Chuh A. Eruptive hypomelanosis as a new paraviral exanthem in a child: a case report. *Indian J Dermatol Venereol Leprol* 2015;81 [in press].
 220. Chuh A, Zawar V, Maheshwari A, Bharatia P. A mini-epidemic of eruptive hypomelanosis in three children of the same family – the first piece of epidemiological evidence for an infectious cause of a novel paraviral exanthem. *Pediatr Dermatol* 2016;32 [in press].