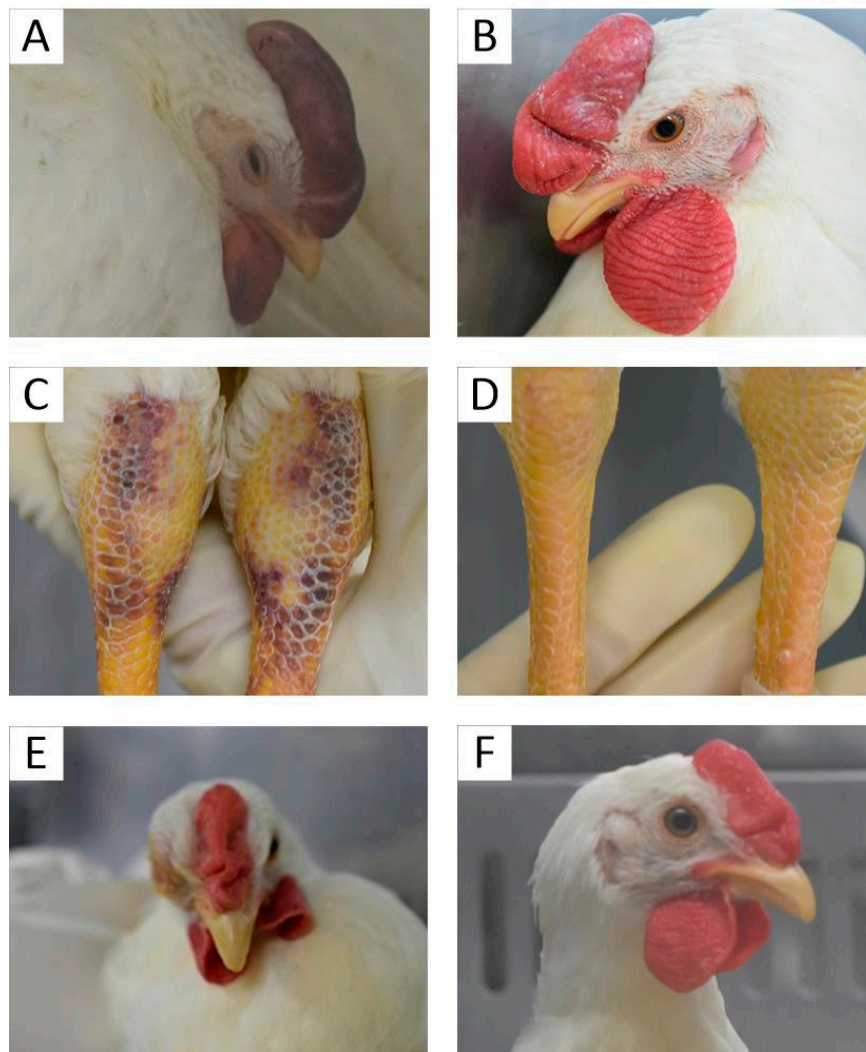


## Supplementary Materials



**Figure S1** Clinical symptoms of chickens infected via the nasal route. **(A)**Clinical symptoms of chickens after infection with Th005 and its passaged strains: depression, cyanosis of wattles, and edema of the face. **(B)**Chicken without infection. **(C)**Skin surface bruising in chicken legs after infected with Th005 and its passaged strains. **(D)**Chicken legs without infection. **(E)** Conjunctivitis and edema of the face in an Anhui CK-infected chicken. **(F)** Conjunctivitis and edema of the face in the Anhui CK-infected chicken disappeared next day.