Experience with Mandibular Reconstruction Using Transport-Disc-Distraction Osteogenesis

Lorena Pingarrón-Martín, MD, PhD[1] T. González Otero, MD, PhD[2] L.J. Arias Gallo, MD, PhD[3]

[1] Department of Oral and Maxillofacial Surgery, University Hospital Rey Juan Carlos, Madrid, Spain
[2] Department of Oral and Maxillofacial Surgery, La Paz University Hospital, Madrid, Spain
[3] Department of Oral and Maxillofacial Surgery, Hospital La Moraleja/ Hospital La Zarzuela, Madrid, Spain

Address for correspondence Lorena Pingarrón-Martín, MD, PhD, Hospital Rey Juan Carlos. Servicio Cirugía Maxilofacial, C/Gladiolo S/N. 28933 Móstoles, Madrid, Spain (e-mail: lorena.pingarron@idcsalud.es; lorenapingarron@yahoo.es).

Craniomaxillofac Trauma Reconstruction 2015;8:117–122

Abstract

The goal of transport-disc-distraction osteogenesis (TDDO) is to restore bone continuity by using in-situ bone. It may be useful following trauma, gunshot injuries, or tumor ablation, especially when there may be contraindications at the donor site or for prolonged surgery. To the best of the authors' knowledge, this is the first time TDDO has been used for mandibular reconstruction reporting additional procedures, which include osseointegrated dental implants rehabilitation and orthognathic surgery. A retrospective study is performed analyzing all mandibular reconstruction cases that may be suitable for distraction from January 2006 to December 2011. A thorough description of the documented cases includes details about sex, gender, complications, duration of hospitalization, etiology, size, and location of the defect. Eight cases of mandibular reconstruction were included. Six cases correspond to mandibular ameloblastoma. The remaining two cases were mandibular gunshot comminuted fractures. Range of the defects was from 45 to 60 mm. Length of the transport disc was 15 to 20 mm. Protocolized technique consisted of 5 days of latency period, 19 to 45 days of activation term (average 30 days), and 8 to 12 weeks for consolidation. Mean distraction length achieved was 40.45 mm. We can conclude that TDDO is an alternative to conventional and more invasive procedures, when we face severe segmental mandibular defects reconstruction. It shows the potential to restore a better anatomical bone regeneration, also providing soft tissues and reducing donor-site morbidity. Patients' education and awareness about the proper use of the transport-disc-distraction device is important to optimize functional outcomes.

Keywords
- transport-disc-distraction osteogenesis
- TDDO
- mandibular reconstruction
- gunshot injury
- ameloblastoma

The most common indication for mandibular reconstruction remains ablative surgery for neoplastic processes involving the oral cavity and oropharynx. Nevertheless, further causes of mandibular defects include trauma, infection/inflammation, osteoradionecrosis, and congenital deformities.

Refinements in technique try to improve functional and aesthetic outcomes of oromandibular reconstruction. Following this concept, alternative treatments, such as transport-disc-distraction osteogenesis (TDDO), have gained popularity. This procedure tries to achieve a better anatomical regeneration not only of bone, but also of soft tissues, reducing donor-site morbidity.

The goal of this technique is to restore bone continuity by using in-situ bone, when available, to avoid bone grafting or revascularized free-tissue transfer.[1,2]

received
December 29, 2013
accepted after revision
April 21, 2014
published online
November 18, 2014

Copyright © 2015 by Thieme Medical Publishers, Inc., 333 Seventh Avenue, New York, NY 10001, USA.
Tel: +1(212) 584-4662.

DOI http://dx.doi.org/10.1055/s-0034-1393729.
ISSN 1943-3875.

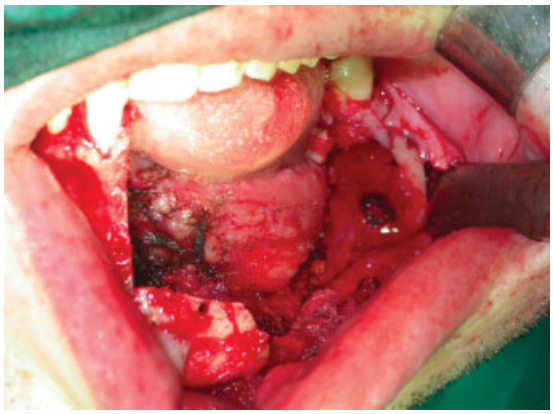

Fig. 1 Mandibular defect after osteotomy from left canine to left third molar.

In this report, the authors present their experience facing different situations of large mandibular defects reconstructed with transport osteogenesis, to establish whether TDDO devices are worthwhile according limitations and disadvantages of this emergent reconstructive option.

To the best of the authors' knowledge, this is the first time TDDO has been used for mandibular reconstruction reporting additional procedures, which include osseointegrated dental implants rehabilitation and orthognathic surgery.

Material and Methods

A retrospective study was performed analyzing the database review of all mandibular reconstruction cases that may be suitable for TDDO technique during the period from January 2006 to December 2011.

Protocolized technique consisted of 5 days of latency period, followed by 19 to 45 days of transport or activation term (average 30 days) when segments were moved twice per day at 0.5 mm/time, and finally 8 to 12 weeks of consolidation period (mean, 80 days; range, 70–84 days).

A thorough description of the documented cases includes details about sex, gender, remarkable perioperative complications, etiology, size, and location of the defect. Also, amount of bone regenerated was quantified. Finally, duration of hospitalization was considered too.

A stereolithographic model was required for patients with symphyseal and body mandible reconstruction where a Herford Transport Distractor (plate guided) (KLS Martin Group, Tuttlingen, Germany) fixed on a ThreadLock TS reconstruction plate of 2.7 mm was used. Distraction procedures were evaluated by using panoramic radiographs. Additional procedures trying to achieve an improvement in the occlusion, masticatory function, and aesthetic condition were discussed.

Surgical Technique

A representative case is a 24-year-old boy whose main complaint was painless left mandibular swelling corresponding to ameloblastoma. Prior to surgical treatment, occlusion of right-side healthy teeth was noted, and to try to avoid potential postoperative malocclusion of the remaining jaw, surgical splints were applied.

Tumor was excised via both intraoral and extraoral approaches in the submandibular region (►**Figs. 1** and **2**).

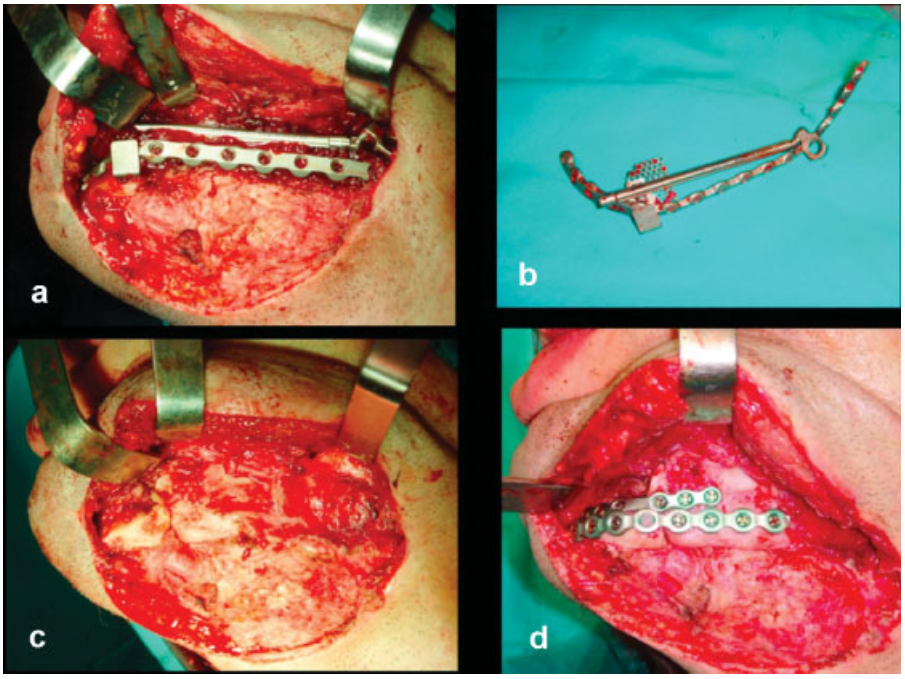

Fig. 2 (**a**) Transport-disc-distraction osteogenesis device set in the mandibular defect. (**b**) The device configuration contains an activation distraction mechanism, the bone transport unit, the activation arm, and the frame, which is composed of two longitudinal bars that provide both a guide and stability for the bone transport unit and the support plate that provide the support for the active distraction system and the fixation ends. (**c**) Regenerated bone after the consolidation period and the removal of the device. (**d**) Transport segments and grafted bone between the segments were fixed with titanium plates.



Fig. 3 Placement of five dental implants in the reconstructed mandible and a screw-retained prosthesis for dental rehabilitation.

Marginal mandibular branch of the facial nerve was preserved, and segmental mandibulectomy was performed from distal left canine up to left third molar.

Of the 55 mm defect generated by tumor resection, 40 mm was regenerated by mandibular TDDO technique. The remaining 15 mm was restored by grafting an iliac bone fragment 15 mm high and 15 mm in mesiodistal diameter. Transport segments and grafted bone between these were fixed with titanium plates (►**Fig. 2**).

Ten months later, five dental implants were inserted in the reconstructed mandible and a screw-retained prosthesis was customized and placed (►**Fig. 3**). Eight-month follow-up is uneventful and satisfactory. Patient 7 presented comminuted mandibular fracture and additional midface fractures as consequence of a gunshot injury (►**Fig. 4**). Although the first emergency surgery for this patient, which included coronal, subciliary, and cervical approaches, allowed bone segments reduction and osteosynthesis, the patient presented severe sequelae: mandibular bone and soft tissues loss, laterodeviated malocclusion, and facial deformity (►**Figs. 5** and **6**).

One year after the initial trauma, mandibular defect was reconstructed through a bifocal transport-disc device (ThreadLock Transport Distractor fixed on a ThreadLock TS reconstruction plate of 2.7 mm) using the previous cervical scar (►**Fig. 7**).

A special tip in this case was the task of monomaxillary orthognathic surgery, which was performed two years after the consolidation distraction period, to restore occlusion and facial symmetry. This procedure consisted of conventional Le Fort I osteotomy with neither segmentation nor interpositional bone grafts. Three months after the orthognathic surgery, the patient presented a considerable improvement,

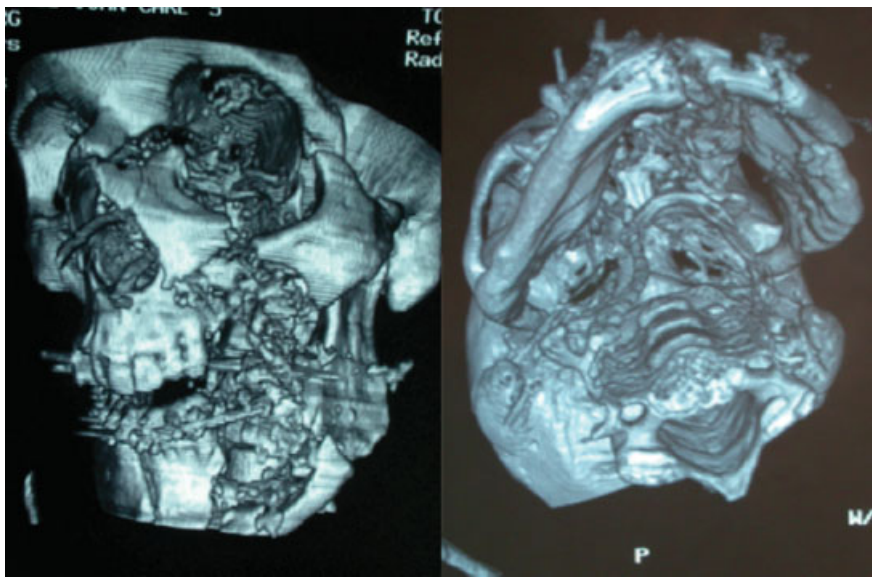

Fig. 4 3D CT image diagnosed comminuted mandibular fracture, comminuted orbitomalar and zygomatic fractures.

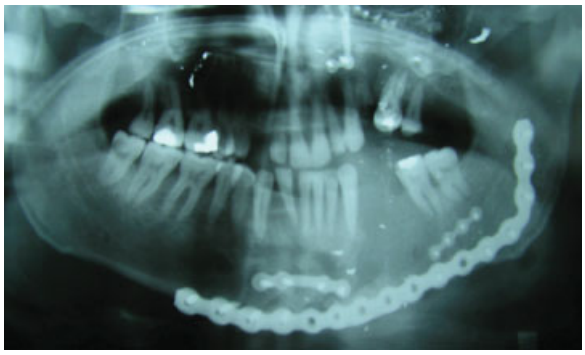

Fig. 5 Osteosynthesis and reduction of the bone segments as emergency surgery. The patient presented severe sequelae of bone deficiency in left mandibular body.

affecting not only the occlusal deviation, but also the facial deformity (►**Fig. 6**).

Results

Eight cases of mandibular reconstruction with bifocal transport osteogenesis were documented and included in the study, during the period from January 2006 to December 2011 (►**Table 1**).

Six cases corresponded to mandibular ameloblastoma. The remaining two cases were mandibular gunshot comminuted fractures. Range of defects changed from 45 to 60 mm. Length of the transport disc was 15 to 20 mm. Mean distraction length achieved was 40.45 mm (as calibrated on the device). Four cases needed further augmentation by adding non-vascularized autologous iliac crest bone grafts. In these cases, two corresponded to gunshot-injured patients who needed additional 15 mm bone grafting, patient 1 whose body mandibular reconstruction required 15 mm free iliac crest graft, and finally patient 3 presenting body and symphyseal mandibular defect, whose integral reconstruction made necessary an additional 18 mm bone graft. Symmetric facial balance was achieved in all cases. All incidents and single characteristics faced during the distraction process were documented in the patient's record as follows (►**Table 1**).

In patients 1, 2, 4, 5, and 6, ameloblastoma tumor was responsible for body mandibular reconstruction, whereas patient 3 underwent a symphyseal plus body mandibular reconstruction as a consequence of the same primary etiology. At the end of consolidation period, a gap was noticed in four of the remaining cases. They were filled up with iliac crest graft—three of them with bone chips and the other one with corticocancellous bloc. Dental implants were placed on the new bone for adequate rehabilitation in three cases. All surgeries were performed in the hospital with the patient being discharged no more than 4 days postoperatively.

Discussion

There are several different clinical presentations of mandibular continuity loss, including patients with odontogenic tumors that have adversely affected the structural integrity of the mandible, patients who need mandibulectomy for malignant disease in the oral cavity or oropharynx that involves the mandible, and patients with traumatic mandible loss.[2–4] The first and third conditions are the most frequent ones in our series of patients and the main situations where TDDO will fit properly.

Odontogenic tumors include locally aggressive tumors, such as ameloblastoma, or expansive lesions, as odontogenic myxoma or odontogenic keratocyst. Patients with these

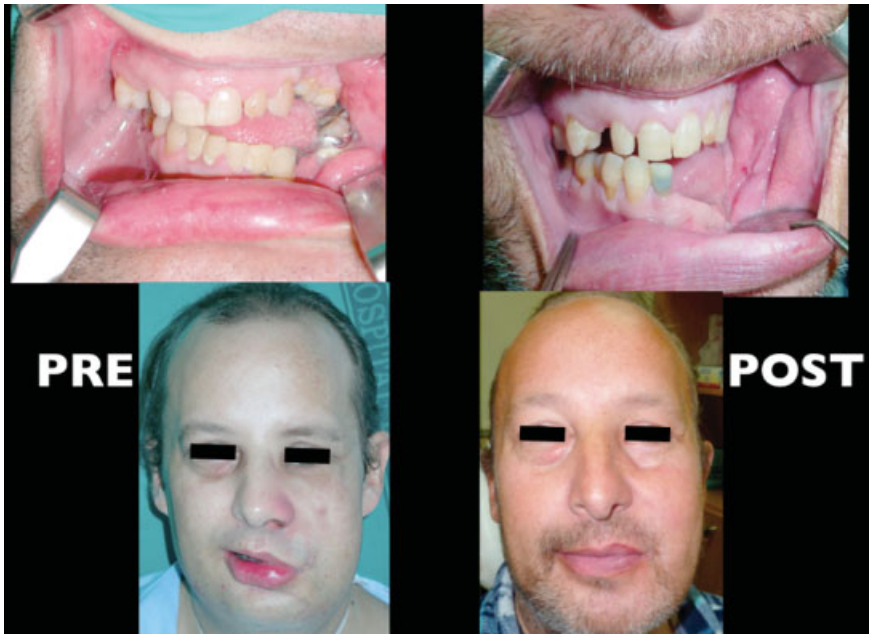

Fig. 6 Preoperative image shows the facial deformity and severe lateromandibular deviation. The postoperative outcome shows a proper restoration of facial contour with adequate dental occlusion after orthognathic surgery.

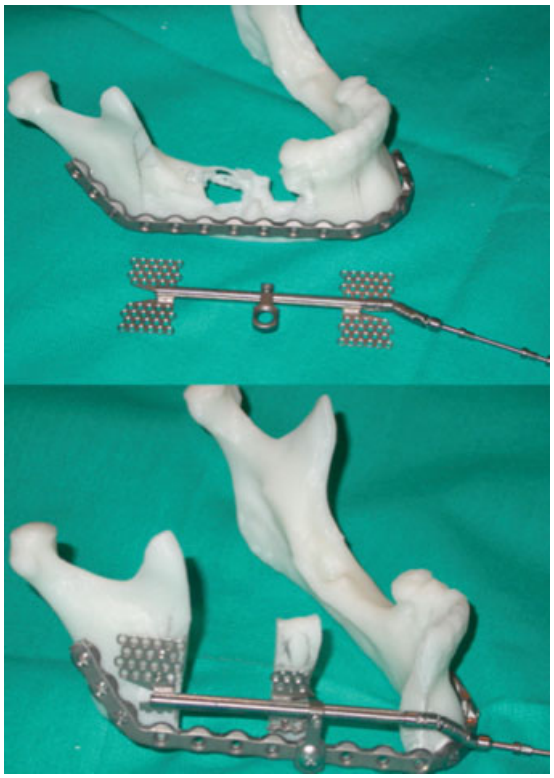

Fig. 7 Stereolithographic model for surgical planification of the tumor resection and the TDDO process.

tumors are likely to need surgical resection without any radiotherapy or chemotherapy.

Patients presenting malignancies who do not need radiotherapy are uncommon, but are ideal candidates for TDDO.[4,5]

One of the major challenges involving the use of this technology in head and neck oncological reconstruction will be the effect of radiotherapy on the regenerated bone, especially in patients who have previously received or will need radiotherapy as part of their treatment.

Other patients who may need mandibular reconstruction are those who suffer a traumatic mandibular loss. Most of these patients may have suffered a missile-type injury which is similar to patients with benign tumors. Main common alternatives for reconstruction are free bone grafts or revascularized-tissue transfer, the main problem being not only the bone defect, but also the lack of soft tissue covering the bone.

One challenge in TDDO has been to perform reconstruction in curved structures such as the mandibular symphysis. This is the case of patient 3 in our series. In this situation, the procedure involves sectioning the transport disc (here it is crucial to keep the integrity of the lingual mucosa to ensure the vascular supply not only for the transport disc segment but also for the neoformed bone). Also, rotation of the distraction device, followed by gradual distraction of the most proximal segment to the transport disc across the surgical defect, is so important to permit the formation of a

Table 1 Characteristics of the distraction process and patients' details

Patient	Age/ Gender	Etiology	Defect location	Defect size (mm)	Hospitalization time (d)	Perioperative complication	Additional procedures
P1	24 y/M	Ameloblastoma	Left mandibular body	55	3	Infection of transport disc	Five osseointegrated dental implants. 15-mm bone graft
P2	52 y/M	Ameloblastoma	Left mandibular body	50	4	Mistake of the patient during the activation period (counter-clockwise turn)	Four osseointegrated dental implants
P3	33 y/F	Ameloblastoma	Left mandibular body	55	3		Stereolithographic model
P4	46 y/F	Ameloblastoma	Symphysis and right mandibular body	60	3	Intraoral dehiscence of the wound with local infection	Stereolithographic model. 18-mm bone graft
P5	37 y/M	Ameloblastoma	Right mandibular body	52	3		Stereolithographic model
P6	23 y/F	Ameloblastoma	Left mandibular body	45	4		Four osseointegrated dental implants
P7	49 y/M	Gunshot injury	Left mandibular body	45	3		Monomaxillary orthognathic surgery. 15-mm bone graft
P8	53 y/M	Gunshot injury	Left mandibular body	57	3		15 mm bone graft

curved-shaped anterior mandible, thus restoring the mandible to normal contour and function.

As a refinement of this reconstructive technique, the stereolithographic model has shown several advantages. It is optionally performed in cases of moderate body defects, but, in the authors' opinion, it is mandatory in cases of symphyseal and large reconstructions to try to improve the accuracy of the results (as we introduced as part of the procedure in patients 3 and 4 of the presented series) (►**Fig. 7**). The stereolithographic model allows us a thorough surgical planification with higher precision of the surgical margins of excision and of the transport disc design, a considerable diminution in operating time, and, what is more important, an intraoral approach for the device placement without unaesthetic cervical scars.[6]

The disadvantages of the bone transport method are the long-lasting treatment period and the possible infection around the device during consolidation. Nevertheless, distraction device management and time duration were well tolerated by patients. There were no severe complications during the whole process. The main issue to discuss is the fact that four of our patients needed bone grafting secondarily; thus, it could be criticized that it was the reason for the distraction procedure in the first place. However, a bigger bone graft should not be done primarily in two of the patients who needed secondary bone graft, because the mandibular reconstruction was consequence of gunshot injury with extreme absence of soft tissue cover and, on the other hand, the other two cases suffered infection during the transport osteogenetic procedure with interruption of the whole regeneration.

Our results are coincident with the current literature, which supports the effectiveness of TDDO for the restoration of mandibular defects.[7–9]

In our series, the most remarkable complications were local infections in patients 1 and 4 (in this last case, it may be a consequence of suture's dehiscence, likely due to intraoral placement of the transport-disc device). On the other hand, infections were not severe and were managed by using oral antibiotics for a few days.

Based on their own experience, the authors may assert how transport osteogenesis is a more appropriate reconstructive modality in younger patients. Also, it allows adequate dental implant rehabilitation. The treatment was long, but functionally and morphologically good results were obtained with considerable reduction of donor-site morbidity.

Acknowledgments

The authors thank Dr. Juan Rey for his contribution in the publication of this article. Transport-disc-distraction osteogenesis devices were supplied by Osteoplac-KLS Martin Group.

Conflict of Interest

None.

References

1 Basa S, Uner E, Citir M, Aras K. Reconstruction of a large mandibular defect by distraction osteogenesis: a case report. J Oral Maxillofac Surg 2000;58(12):1425–1428
2 Liu Y, Chen J, Yan F, Ping F. Mandible reconstruction with transport-disc distraction osteogenesis in children of deciduous dentition. Int J Oral Maxillofac Surg 2012;41(10):1223–1228
3 Rubio-Bueno P, Naval L, Rodriguez-Campo F, Gil-Díez JL, Díaz-González FJ. Internal distraction osteogenesis with a unidirectional device for reconstruction of mandibular segmental defects. J Oral Maxillofac Surg 2005;63(5):598–608
4 Takahashi T, Fukuda M, Aiba T, Funaki K, Ohnuki T, Kondoh T. Distraction osteogenesis for reconstruction after mandibular segmental resection. Oral Surg Oral Med Oral Pathol Oral Radiol Endod 2002;93(1):21–26
5 Kuriakose MA, Shnayder Y, DeLacure MD. Reconstruction of segmental mandibular defects by distraction osteogenesis for mandibular reconstruction. Head Neck 2003;25(10): 816–824
6 Wang X, Lin Y, Yi B, Wang X, Liang C, Li Z. Mandibular functional reconstruction using internal distraction osteogenesis. Chin Med J (Engl) 2002;115(12):1863–1867
7 Wang JJ, Chen J, Ping FY, Yan Fg. Double-step transport distraction osteogenesis in the reconstruction of unilateral large mandibular defects after tumour resection using internal distraction devices. Int J Oral Maxillofac Surg 2012;41(5):587–595
8 Kim SM, Park JM, Myoung H, Lee JH. Transport disc distraction osteogenesis as an alternative protocol for mandibular reconstruction. J Plast Reconstr Aesthet Surg 2010;63(8):e644–e646
9 Sacco AG, Chepeha DB. Current status of transport-disc-distraction osteogenesis for mandibular reconstruction. Lancet Oncol 2007; 8(4):323–330