Component Approach to the Temporomandibular Joint and Coronoid Process

Miles J. Pfaff, BA[1] James Clune, MD[1] Derek Steinbacher, MD, DMD[1]

[1] Department of Plastic and Reconstructive Surgery, Yale University, New Haven, Connecticut

Address for correspondence Derek Steinbacher, MD, DMD, Plastic Surgery, Yale University, 330 Cedar Street BB 3rd Floor, New Haven, CT 06520 (e-mail: derek.steinbacher@gmail.com).

Craniomaxillofac Trauma Reconstruction 2014;7:323–326

Abstract

Reconstruction of the temporomandibular joint (TMJ) region is challenging. The conventional direct preauricular incision permits only limited access to the TMJ and surrounding structures, therefore risking injury to the facial nerve during retraction. The ideal approach allows sufficient exposure, preservation of underlying neurovascular structures, and achieves an optimal aesthetic outcome. We describe a preauricular posttragal incision with a superficial musculoaponeurotic system flap to allow wide exposure of the zygomatic arch, TMJ, condyle, and coronoid process. We postulate that this approach improves access, lessens the amount of retraction required, and creates a more inconspicuous scar.

Keywords

- temporomandibular joint
- preauricular incision
- posttragal incision
- superficial musculoaponeurotic system
- rhytidectomy

Conventional access to the temporomandibular joint (TMJ) involves a composite preauricular incision.[1] Tortuous superficial temporal vessels are encountered multiple times within this plane, and the capsule and condyle can be difficult to visualize where it is located deeply beneath masseter attachments. Significant retraction is required merely to expose the condyle, and visualization of the coronoid and anterior ramus is not typically possible. Such continuous anterior retraction in an attempt to improve exposure portends possible neuropraxia to the frontal branch of the facial nerve when using this composite technique.

Moreover, the preauricular scar is unsightly, frequently not healing in an aesthetic fashion. Other approaches have been reported, including the postauricular[2,3] and endaural.[3] However, these also carry several disadvantages, including extended temporal scarring and reports of perichondritis.[4]

Facial skin flaps, for cosmetic procedures (rhytidectomy), parotidectomy, and facial reanimation, have been described to be concealed along facial subunits while providing maximum surgical access.[5–8] Rhytidectomy dissection techniques also typically entail manipulation of the superficial musculoaponeurotic system (SMAS) layer, for tissue redraping.[9] The benefit of creating component tissue layers can be applied to TMJ exposure.

We report on an anterior hairline, preauricular posttragal incision, in conjunction with a deep SMAS flap to approach the TMJ. Importantly, this approach allows for wide surgical access, including the entire coronoid process, and facilitates protection of the facial nerve and superficial temporal vessels, while enhancing cosmesis.

Methods

All patients who underwent a component approach to the TMJ and coronoid were identified and included in this report. All patients were operated on by a single surgeon (D.S.) from June 2011 to July 2012 (►**Table 1**).

Technique

The surgical field is prepped and local anesthesia administered. A beveled incision is made from the anterior temporal hairline to the root of the helix, then carried along the preauricular crease to the retrotragal location, terminating at the ear lobule-posterior cheek junction ("reverse hockey

received
February 11, 2013
accepted after revision
February 14, 2013
published online
June 3, 2014

Copyright © 2014 by Thieme Medical Publishers, Inc., 333 Seventh Avenue, New York, NY 10001, USA.
Tel: +1(212) 584-4662.

DOI http://dx.doi.org/10.1055/s-0033-1364196.
ISSN 1943-3875.

Table 1 Presented cases of component SMAS approach to the TMJ

Diagnosis	Age (years)	Sex	Treatment
TMJ ankylosis, retrognathia	5	F	Bilateral condylectomy, coronoidectomy, arthroplasty with distractor placement
TMJ ankylosis	65	F	Bilateral condylectomy, coronoidectomy, TMJ alloplastic reconstruction
Hemifacial microsomia	5	M	Reconstruction of TMJ, zygomatic arch, and neo-glenoid fossa with costal grafts
Bilateral condylar fractures	46	M	Bilateral ORIF of condylar fractures

Abbreviations: ORIF, open reduction internal fixation; SMAS, superficial musculoaponeurotic system; TMJ, temporomandibular joint.

stick") (►**Fig. 1A**). The skin flap is raised subcutaneously toward the malar eminence and the expected trajectory of the frontal branch is then demarcated with surgical ink atop the SMAS (pretragal to lateral brow)[10] (►**Fig. 1B**). A deep SMAS flap is raised beginning horizontally above the zygomatic arch and coursing preauricularly (►**Fig. 1C**). This is subperiosteal along the arch, and incorporates the superior extent of parotideomasseteric fascia. The masseter is then divided from the attachments on the arch to expose the TMJ capsule (►**Fig. 1C, D**). The capsule is then incised and the lateral pole of the condyle encountered. Dissection is continued posteriorly toward the neck and anteriorly to the sigmoid. The coronoid can then be exposed following additional takedown of the masseter muscle and subperiosteal dissection anteriorly. Alloplastic or autologous reconstruction is then undertaken (►**Figs. 2** and **3**). We present four cases of the component approach to the TMJ and coronoid process (►**Table 1**). Follow-up demonstrated

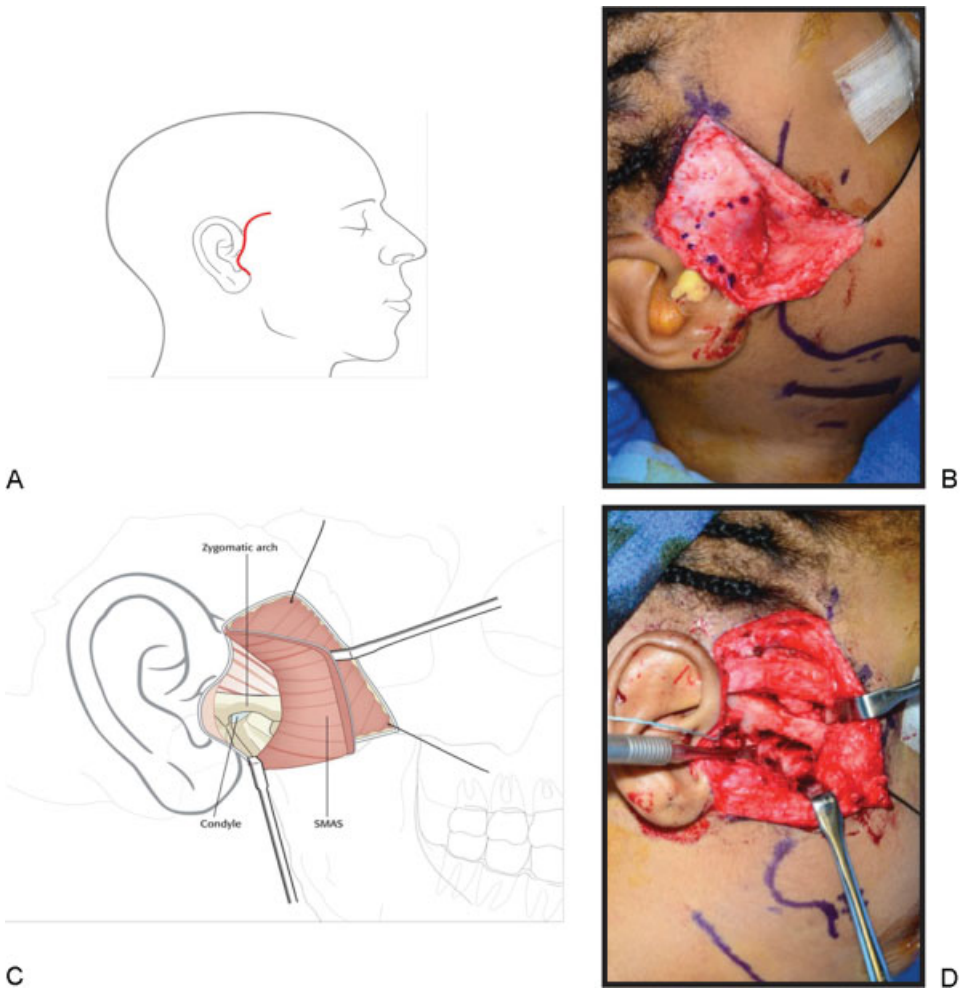

Figure 1 (A) The skin incision extends from the anterior hairline to the root of the helix, then carried within the preauricular crease and terminated at the ear lobule-posterior cheek junction (note the posttragal extension of the incision). (B) The skin flap is elevated subcutaneously toward the malar region, exposing the frontal branch of the facial nerve. The trajectory of the frontal branch of the facial nerve is then outlined intraoperatively. (C and D) A deep SMAS flap is raised above the zygomatic arch and preauricularly to permit visualization of the zygomatic arch, condyle, and coronoid process. SMAS, superficial musculoaponeurotic system.

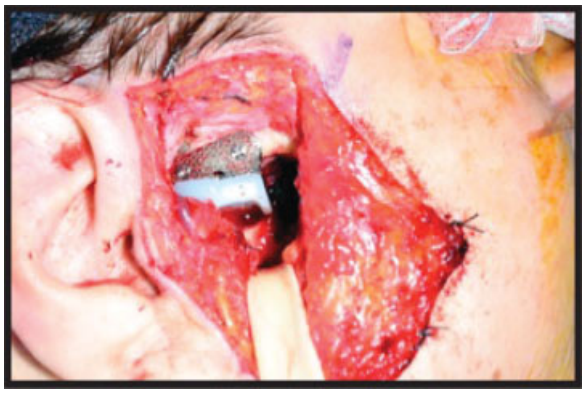

Figure 2 A 65-year-old woman presented with bilateral TMJ ankylosis and coronoid hypertrophy. Anterior hairline preauricular posttragal incisions with SMAS flaps were made bilaterally to perform condylectomies, coronoidectomies, and total TMJ alloplastic reconstruction. TMJ, temporomandibular joint; SMAS, superficial musculoaponeurotic system.

preserved cosmesis and facial nerve function in all cases (►**Fig. 4**).

Discussion

Reconstruction of TMJ structures is challenging for many reasons, not the least of which is the difficulty obtaining sufficient exposure. The ideal approach allows for wide access, avoidance of vital structures, and optimal esthetics. Maintaining the facial tissue planes together, as a composite flap, limits easy exposure of the sigmoid and anterior structures of the TMJ, as well as the coronoid. More tension is required to retract this composite tissue anteriorly risking traction on the facial nerve. Even with such robust retraction, this conventional approach allows only minimal exposure, with pertinent structures located deep in the field and visibility for dissection and hemostasis limited. In addition to the unsightly incision location, the continued tension from retraction can traumatize the skin edges, perhaps increasing scarring. Recently, Pau et al described a modified preauricular approach to include a trans-tragal extension.[11] This modification provided greater access to the condyle but may not reduce the need for retraction (1/16 patients developed temporary impairment of a branch of the facial nerve) and access to the coronoid is insufficient.



Figure 3 A 46-year-old man presented with multiple facial fractures affecting the left and right condyles and mandible. For open reduction and internal fixation of the left condylar fracture, a left-sided hairline preauricular posttragal incision with a SMAS flap was created. Pre- and postfixation computed tomographic images are presented (*left* and *right*, respectively).



Figure 4 A 65-year-old woman following bilateral reconstruction of the TMJ at 11 months postoperatively demonstrating intact function of the temporal branch of the facial nerve via furrowing of the brow (*above*) with preserved cosmesis and a well-concealed scar.

Incisions posterior to the ear with dissection through the cartilaginous auditory canal have also been described. The resulting flap from this postauricular design is elevated and reflected anteriorly, providing excellent exposure of the lateral and deep structures of the TMJ; however, serious complications of the external auditory canal (EAC) including stenosis, infection, and necrosis, as well as prolonged operating time are associated with this procedure.[2] Alternatively, an incision from the inferior portion of the anterior meatal wall extending superiorly to the preauricular crease and through the soft tissue into the temporal hair region has been used clinically. This endaural approach provides exposure of the lateral and posterior TMJ with limited anterior exposure.[3] In both the postauricular and endaural approaches, the facial nerve is well protected within the flap, but coronoid access remains limited and canal stenosis can occur.

Shortcomings of the conventional preauricular exposure are addressed in our procedural design by including the anterior temporal hairline and extending the incision posttragally. This rhytidectomy-styled dissection separates anatomic components

allowing for deep SMAS flap elevation as well as increased exposure of the TMJ, condyle, and coronoid process. Improved visualization decreases the need for retraction and consequent risk of injury to the facial nerve. Additionally, posttragal extension of the incision conceals a significant portion of the scar, effectively reducing scar visibility. The incision within the preauricular crease utilizes the natural contours of the ear, further reducing scar visibility, and a beveled incision perpendicular to the underlying hair follicles in the temporal hair-bearing region allows preservation and regrowth of hair anterior and posterior to the incision.[6,12] Finally, with increased exposure of all structures of the TMJ, this approach proves to be flexible and versatile in its surgical application including acquired or congenital defects.

Conclusion

We report on a component approach to the TMJ and coronoid process, and demonstrate implementation in four heterogeneous cases. The rhytidectomy incision with a deep SMAS flap improves access (to the TMJ, sigmoid, and coronoid process), lessens the amount of retraction required (and thus risk of damage to the facial nerve), and creates a more inconspicuous scar.

Financial Disclosures
The authors have no commercial associations or disclosures that may pose or create a conflict of interest with the information presented within this article.

References

1 Ellis E. Surgical Approaches to the Facial Skeleton. 2nd ed. Philadelphia, PA: Lippincott Williams & Wilkins; 2006:193–214
2 Kreutziger KL. Extended modified postauricular incision of the temporomandibular joint. Oral Surg Oral Med Oral Pathol 1987; 63(1):2–8
3 Kreutziger KL. Surgery of the temporomandibular joint. I. Surgical anatomy and surgical incisions. Oral Surg Oral Med Oral Pathol 1984;58(6):637–646
4 Gulya AJ. Glasscock-Shambaugh Surgery of the Ear. 6th ed. Shelton, CT: Peoples Medical Publishing House; 2010
5 Frey M, Giovanoli P. The three-stage concept to optimize the results of microsurgical reanimation of the paralyzed face. Clin Plast Surg 2002;29(4):461–482
6 Kridel RW, Liu ES. Techniques for creating inconspicuous face-lift scars: avoiding visible incisions and loss of temporal hair. Arch Facial Plast Surg 2003;5(4):325–333
7 Carniol PJ, Ganc DT. Is there an ideal facelift procedure? Curr Opin Otolaryngol Head Neck Surg 2007;15(4):244–252
8 Lohuis PJ, Tan ML, Bonte K, van den Brekel MW, Balm AJ, Vermeersch HB. Superficial parotidectomy via facelift incision. Ann Otol Rhinol Laryngol 2009;118(4):276–280
9 Rodriguez-Bruno K, Papel ID. Rhytidectomy: principles and practice emphasizing safety. Facial Plast Surg 2011;27(1):98–111
10 Stuzin JM, Wagstrom L, Kawamoto HK, Wolfe SA. Anatomy of the frontal branch of the facial nerve: the significance of the temporal fat pad. Plast Reconstr Surg 1989;83(2):265–271
11 Pau M, Feichtinger M, Reinbacher KE, Ivancic P, Kärcher H. Transtragal incision for improved exposure of diacapitular and condylar neck fractures. Int J Oral Maxillofac Surg 2012;41(1): 61–65
12 Mowlavi A, Majzoub RK, Cooney DS, Wilhelmi BJ, Guyuron B. Follicular anatomy of the anterior temporal hairline and implications for rhytidectomy. Plast Reconstr Surg 2007;119(6): 1891–1895, discussion 1896