Superolateral Dislocation of Bilateral Intact Condyles—An Unusual Presentation: Report of a Case and Review of Literature

Virendra Singh, MDS[1] Pranav Gupta, MDS[2] Shruti Khatana, MDS[2] Amrish Bhagol, MDS[2]

[1] Department of Oral and Maxillofacial Surgery, Government Dental College, Pt. B.D., Sharma University of Health Sciences, Haryana, India
[2] Oral and Maxillofacial Surgery, PGIDS, Rohtak, India

Address for correspondence Virendra Singh, MDS, Department of Oral and Maxillofacial Surgery, Government Dental College, Pt. B.D. Sharma University of Health Sciences–Rohtak, Haryana, India (e-mail: drvirendrasingh1@yahoo.co.in).

Craniomaxillofac Trauma Reconstruction 2013;6:205–210

Abstract

Dislocation of the mandibular condyle is the clinical condition of the condyle head being displaced out of the glenoid fossa but still remaining within the joint capsule. However, the anatomy of the mandibular condyle, glenoid fossa, and zygomatic arch usually prevent the dislocation of intact condyles out of the glenoid fossa whenever the mandible is subjected to high impact. Complete dislocation of the mandibular condyle from the glenoid fossa can be classified into four groups: anterior, posterior, lateral, and superior dislocation. All the groups except anterior dislocation are rare. Superolateral dislocation of the intact mandibular condyle occurs very rarely. We report a case of lateral dislocation of bilateral intact condyles associated with left parasymphysis fracture. The purpose of this report is to review all of the available English literature on this dislocation and discuss the possible causative mechanism and diagnostic features, as well as clinical management.

Keywords
- condylar dislocation
- mandible fracture

Dislocation of the mandibular condyle has been described as the clinical condition "when the condyle head is displaced out of the glenoid fossa but still remains within the capsule of the joint."[1] However, the anatomy of the mandibular condyle, glenoid fossa, and zygomatic arch usually prevent the dislocation of intact condyles out of the glenoid fossa whenever the mandible is subjected to high impact. Complete dislocation of the mandibular condyle from the glenoid fossa can be classified into four groups: anterior, posterior, lateral, and superior dislocation. All the groups except anterior dislocation are rare. Superolateral dislocation of the intact mandibular condyle occurs very rarely.

We report a case of lateral dislocation of bilateral intact condyles associated with left parasymphysis fracture. The purpose of this report is to review all of the available English literature on this dislocation and discuss the possible causative mechanism and diagnostic features, as well as clinical management.

Case Report

A 22-year-old man presented to the emergency department with a history of motor bike accident. He lost consciousness for ~10 to 15 minutes but was conscious at the time of admission and his vital signs were within normal limits. The patient had chin laceration, abrasion of left lower lip region, and significant swelling in bilateral preauricular region with apparent retrusion of the chin (►**Fig. 1**). There was bleeding from bilateral ear region. The patient was unable to close his mouth with associated bilateral open bite (►**Fig. 2**). The maxillary central incisors and mandibular left central incisor were missing. On initial examination it was thought to be a case of bilateral condylar fracture and primarily the mandible was supported with barrel bandage. Further examination revealed the patient could barely move his mandible with persistent open bite; his lateral excursive and protrusive

received
July 14, 2012
accepted
July 22, 2012
published online
June 6, 2013

Copyright © 2013 by Thieme Medical Publishers, Inc., 333 Seventh Avenue, New York, NY 10001, USA.
Tel: +1(212) 584-4662.

DOI http://dx.doi.org/10.1055/s-0033-1343780.
ISSN 1943-3875.



Figure 1 Preoperative photograph showing swelling in bilateral preauricular region and receded chin.

movements were nil and he had severe pain in bilateral preauricular region when he attempted movement.

The patient underwent conventional posteroanterior mandible, reverse Towne's view radiograph, which revealed lateral dislocation of bilateral intact condyles and an incomplete left parasymphysis fracture. He also underwent computed tomography (CT) and three-dimensional CT. The CT scan revealed that both the intact condyles were dislocated laterally and superiorly, crossing the zygomatic arches (►**Figs. 3** and **4**). Both the zygomatic arches were intact.



Figure 2 Preoperative intraoral photograph showing inability to close the mouth and bilateral open bite.

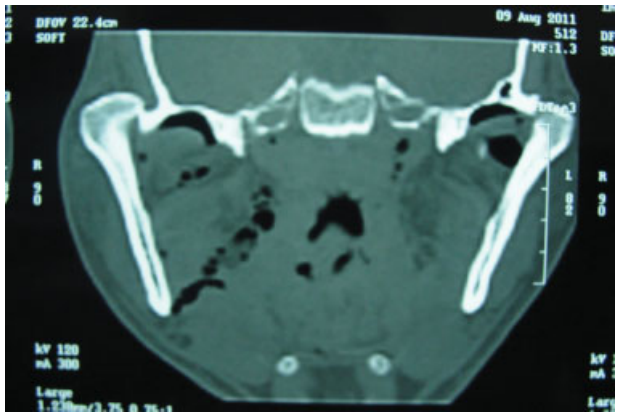

Figure 3 Coronal section of preoperative computed tomography scan showing superolateral dislocation of bilateral intact condyles.

There was associated left mandibular parasymphysis fracture with step defect between left central incisor and lateral incisor, and the lower border appeared intact. There was also associated dentoalveolar fracture in relation to left maxillary anterior teeth. On clinical and radiographic correlation, a diagnosis of bilateral lateral dislocation of intact condyles with associated left parasymphysis fracture was made.

Surgery under general anesthesia was performed 2 days after admission. The right angle region of the mandible was exposed via small submandibular incision, and a through-and-through hole was drilled to pass a traction wire. The traction wire was held firmly with a wire tightener and pulled downward and forward to reduce the right condyle, and a channel retractor was engaged in the sigmoid notch to pull the condyle downward in the fossa (Finck's technique[2]). Once the right condyle was reduced, the left condyle was manually reduced with the help of a mouth gag. The mouth gag was placed between left posterior teeth and rotated clockwise to pull the left condyle downward. Once both the condyles were reduced, mandibular movements were checked and condylar movements were palpated in the glenoid fossae. A 33-mm intraoperative mouth opening was achieved. The left mandibular parasymphysis fracture site was exposed intraorally

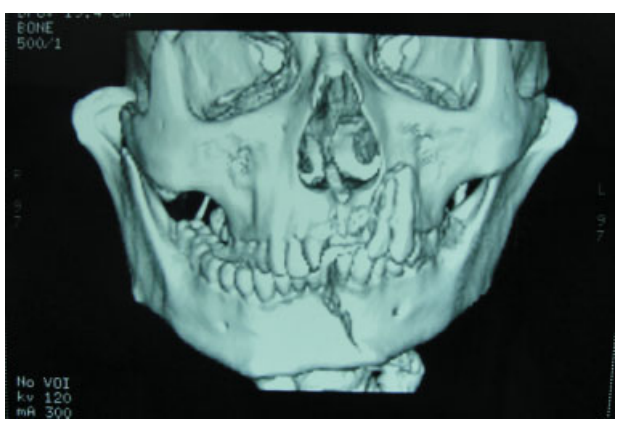

Figure 4 Three-dimensional reconstruction showing superolateral dislocation of condyles and left mandibular parasymphysis fracture.

and reduced with the help of a bone lever and chin retractor. Pretrauma occlusion was achieved and maxillomandibular fixation was done while applying bilateral gonial pressure. The fracture site was fixed with a 2.0-mm four-hole miniplate at the lower border and a 2.0-mm two-hole plate superiorly while applying bilateral gonial pressure.

During the initial follow-up, the patient had limited mouth opening for which he was kept on aggressive physiotherapy and responded well. On 6-month follow-up, the patient maintained a maximal incisal opening of 34 mm with adequate mandibular function and a satisfactory occlusion (►**Fig. 5** and ►**Fig. 6**). The postoperative CT revealed complete reduction of both the condyles and the fracture site (►**Figs. 7**, **8**).



Figure 6 Postoperative intraoral photograph showing satisfactory occlusion.

Discussion

The biomechanics of relatively slender condylar neck is such that whenever a high-impact force is exerted over condylar region, the condylar neck fractures before the condyles dislocate and the thin fragile floor of middle cranial fossa fractures. However, in the present case, there is lateral dislocation of bilateral intact condyles due to high-impact trauma. The mode of injury was a motor bike accident. The laceration on the left lower lip and chin region and the step deformity between the left mandibular central and lateral

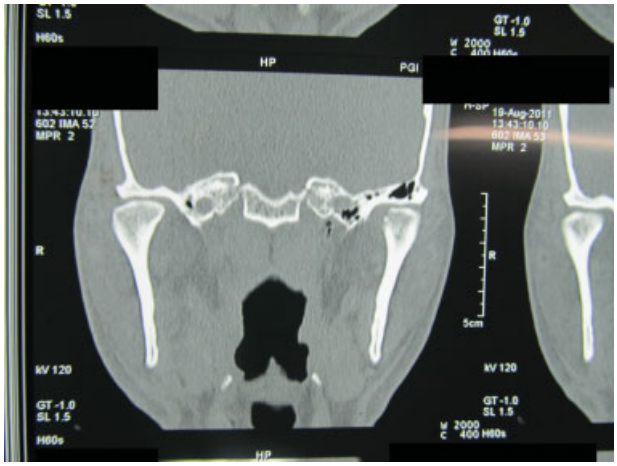

Figure 7 Coronal section of postoperative computed tomography showing complete reduction of both the condyles in their respective glenoid fossae.



Figure 5 Postoperative clinical photograph showing bilateral symmetry of face.

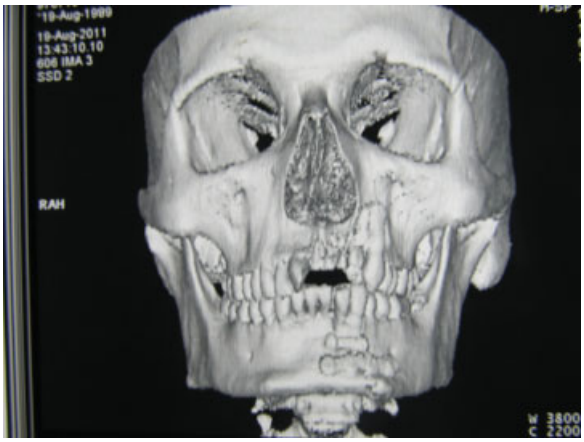

Figure 8 Three-dimensional reconstruction showing complete reduction of the condyles and left parasymphysis fracture site; fixed with two four-hole plates.

incisor suggest that high-impact force from the front on the left parasymphysis region leads to lateral dislocation of the bilateral intact condyles with associated left parasymphysis fracture. It is postulated that during this fall, the passenger was frightened and suddenly opened his jaw either to scream or from fright. The force of the impact displaced the condyles anterior to the articular eminence, rupturing the capsular and ligamentous attachments to the condylar head, and drove the condyles upward anterior to the eminence, lateral to the zygomatic arches, and lateral to the temporalis muscle and fascia into the temporal fossa.

Worthington suggested a mechanism for such a dislocation, stating that two obstacles need to be overcome to achieve such a condition.[3] First, the soft tissue attachments around the condyle must rupture. Second, the transverse dimension of the condylar head (from lateral pole to medial pole) must exceed the lateral dimensions of the space between the zygomatic arch and the medial bony wall of the temporal fossa. In order for the condylar head to pass this obstacle, it is necessary for at least one of following three things to happen: the zygomatic arch may fracture, affording more room for the condyle to pass; the condylar head may fracture, decreasing the bulk; the condyle head may rotate about a vertical axis, which would be likely to occur only in association with a mandibular fracture disposed to facilitate rotation of the ramus.

Allen and Young,[4] Satoh et al,[5] and Kapila and Lata[6] support this and emphasize that a fracture of the symphysis and/or body of the mandible is a prerequisite for the lateral dislocation of the mandibular condyle. In the present case, the fracture of left parasymphysis caused the flaring at dentoalveolar border and compression at lower border and rotation of both the ramus leading to lateral dislocation of the bilateral intact condyles, more severe on the right side.

Cases documented in the English literature are summarized in ►**Table 1**. Allen and Young first reported five cases,

Table 1 Reported cases of superolateral dislocation of intact mandibular condyles

Year	Authors	Type	Uni- or bilateral	Reduction time (d)	Reduction	Outcome
1969	Allen and Young[4]	I	U	8	Partial (C)	Fibro-osseous ankylosis
		II	U	15	Nil (C)	Gross malocclusion
		I	B	1	Complete (C)	25% reduction
		I	U	1	Complete (C)	Full range of jaw movements
		II	U	1	Complete (C)	Not available
1978	Brusati and Paini[10]	II	U	1	Complete (C)	With facial palsy, not detailed
		II	U	12	Complete (O)	With facial palsy and full range of jaw function
1982	Worthington[3]	Unusual	U	14	Partial (O)	Fibro-osseous ankylosis
1988	DeVita et al[14]	II	B	NA	Complete (O)	Not available
1989	Ferguson et al[15]	II	U	1	Complete (O)	Condylectomy, arthroplasty by costal cartilage; mouth opening 30 mm
1989	To[16]	II	U	14	Complete (O)	Bifid condyle, reduced mouth opening
1994	Satoh et al[5]	II	B	13	Partial (O)	Condylectomy, 30-mm mouth opening
1996	Kapila and Lata[6]	II	U	7	Complete (O)	30-mm mouth opening
1998	Hoard et al[17]	II	B	NA	Complete (C)	Not available
2000	Yoshii et al[7]	II	B	16	Complete (C)	20-mm mouth opening
2002	Rattan[11]	II	U	14	Complete (O)	30-mm mouth opening
		II	B	NA	Not reduced	Interpositional gap arthroplasty
2007	Hsieh et al[18]	II	B	1	Complete (C)	41-mm mouth opening
2007	Bu et al[13]	II	U	5	Complete (C)	37-mouth opening
2010	Papadopoulos and Edwards[19]	II	U	1	Complete (C)	32-mm mouth opening with 5 mm lateral excursions
2011	Prabhakar and Singla[20]	III	B	45	Complete (O)	33-mm mouth opening with adequate mandibular function and satisfactory occlusion

B, bilateral; C, closed; NA, data not available; O, open; U, unilateral.

and they subdivided such dislocation into two types: type I (lateral subluxation), in which the condyle has been laterally dislocated out of the fossa, and type II (complete dislocation), in which the condyle has passed laterally and then superiorly to enter the temporal fossa.[4] Satoh et al reported one case and further classified type II dislocation into type IIA, in which the condyle is not hooked above the zygomatic arch[5]; type IIB, in which the condyle is hooked above the zygomatic arch; and type IIC, in which the condyle is lodged inside the zygomatic arch, which is fractured. In the present case the right condylar dislocation would therefore be classified as type IIB and the left as type IIA.

Because of it rarity, these types of dislocation may be misdiagnosed as condylar fractures or completely overlooked. Worthington described the diagnostic features of this type of dislocation as follows[3]: malocclusion persisting after the jaw fracture was reduced, persistence of an open bite, persistent restriction of mandibular movement, an apparent loss of ramus height with elevation of the ramus fragment, and facial asymmetry. Yoshii et al advised that clinicians should consider an unusual condyle dislocation whenever the signs, symptoms, and clinical course were atypical of common mandibular fracture.[7]

The diagnosis can be proved by radiography and CT scans, in particular by three-dimensional CT. Three-dimensional CT scans can clearly demonstrate the dislocated condyle, dislocation type, and whether or not there is a fracture. It is very effective and useful in the diagnosis of this type of dislocation.

Manual reduction is the first choice for a condyle dislocation. A dislocation of a few days may often be corrected by closed/manual reduction.[8] Closed reduction is by far the simplest, least traumatic, and safest of all the alternatives.[9] If closed reduction under general anesthesia is unsuccessful, one of the combined methods involving open traction with closed reduction should be attempted as soon as possible.[3,5–7,10–12] In our patient, the first attempt was made by manual reduction under general anesthesia, which was unsuccessful. The right condyle was then reduced by open traction through holes drilled at lower border of the angle (►**Fig. 9**) and downward traction at the sigmoid notch with the help of channel retractor (Finck's technique[2]). The left condyle was then manually reduced with the help of a mouth gag. Intraoperative mouth opening of 38 mm was achieved.

One of the most critical factors determining the success of treatment is the time between injury and reduction. Delay in the reduction induces fibrosis of the glenoid fossa, resulting in imperfect or unsuccessful reduction. Presence of the fibrous tissue may make closed reduction impossible.

At that time, open reduction/radical surgery becomes essential. Unsuccessful or imperfect reduction induces fibro-osseous ankylosis of the joint, which necessitates condylectomy with or without arthroplasty.[4,5] These previous reports (►**Table 1**) suggest that if diagnosis and treatment in this type of dislocation is delayed, lateral dislocation has a high incidence of unsatisfactory results and imperfect reduction. In our case, the reduction was done 3 days after injury, resulting in complete reduction without much difficulty.

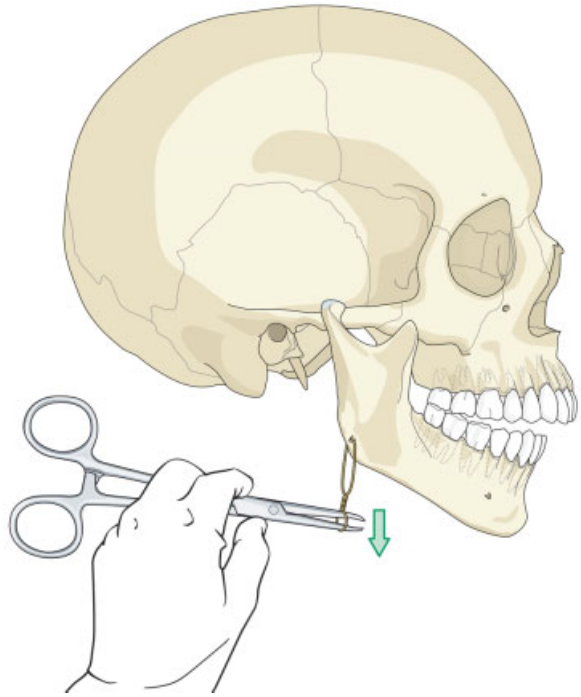

Figure 9 The superolateral dislocation of intact right condyle and method of reduction. The arrow shows the direction of application of force to reduce the dislocated condyle.

The average duration of postoperative immobilization (maxillomandibular fixation) in the literature is 2 weeks.[13] The reduced condyle tends to return to the preoperative position. In addition, immobilization facilitates healing of the presumably damaged ligaments. The patient should receive mouth-opening training to prevent fibrosis from developing. However, in our case postoperative maxillomandibular fixation was not done but the patient was kept on soft diet for 2 weeks followed by active mouth-opening exercises.

Therefore, in conclusion, an interplay of multiple factors determines the successful outcome of such cases. The time lapse between the trauma and definitive management, and extent of reduction and postoperative maxillomandibular fixation followed by patient compliance in terms of postoperative aggressive physiotherapy, are the major factors.

References

1 Sang LK, Mulupi E, Akama MK, et al. Temporomandibular joint dislocation in Nairobi. East African Medical Journal 2010; 87(1):32–37

2 Norman JE deB, Bramley P. Text Book and Colour Atlas of the Temporomandibular Joint. London: Wolfe Med publ Ltd; 1990: 136–150

3 Worthington P. Dislocation of the mandibular condyle into the temporal fossa. J Maxillofac Surg 1982;10:24–27

4 Allen FJ, Young AH. Lateral displacement of the intact mandibular condyle. A report of five cases. Br J Oral Surg 1969;7:24–30

5 Satoh K, Suzuki H, Matsuzaki S. A type II lateral dislocation of bilateral intact mandibular condyles with a proposed new classification. Plast Reconstr Surg 1994;93:598–602

6 Kapila BK, Lata J. Superolateral dislocation of an intact mandibular condyle into the temporal fossa: a case report. J Trauma 1996; 41:351–352

7 Yoshii T, Hamamoto Y, Muraoka S, et al. Traumatic dislocation of the mandibular condyle into the temporal fossa in a child. J Trauma 2000;49:764–766
8 Ord RA, EI-Attar A. Long-standing mandibular dislocations: report of a case, review of the literature. Br Dent J 1986;160: 91–94
9 Kallal RH, Gans BJ, Lagrotteria LB. Cranial dislocation of mandibular condyle. Oral Surg Oral Med Oral Pathol 1977;43:2–10
10 Brusati R, Paini P. Facial nerve injury secondary to lateral displacement of the mandibular ramus. Plast Reconstr Surg 1978;62: 728–733
11 Rattan V. Superolateral dislocation of the mandibular condyle: report of 2 cases and review of the literature. J Oral Maxillofac Surg 2002;60:1366–1369
12 Hayward JR. Prolonged dislocation of the mandible. J Oral Surg 1965;23:585–594
13 Bu SS, Jin SL, Yin L. Superolateral dislocation of the intact mandibular condyle into the temporal fossa: review of the literature and report of a case. Oral Surg Oral Med Oral Pathol Oral Radiol Endod 2007;103:185–189
14 DeVita CL, Friedman JM, Meyer S, Breiman A. An unusual case of condylar dislocation. Ann Emerg Med 1988;17:534–536
15 Ferguson JW, Stewart IA, Whitley BD. Lateral displacement of the intact mandibular condyle. Review of literature and report of case with associated facial nerve palsy. J Craniomaxillofac Surg 1989; 17:125–127
16 To EWH. Supero-lateral dislocation of sagittally split bifid mandibular condyle. Br J Oral Maxillofac Surg 1989;27:107–113
17 Hoard MA, Tadje JP, Gampper TJ, Edlich RF. Traumatic chronic TMJ dislocation: report of an unusual case and discussion of management. J Craniomaxillofac Trauma 1998;4:44–47
18 Hsieh CH, Chen CT, Tsai HH, Lai JP. Lateral dislocation of bilateral intact mandibular condyles with symphysis fracture: a case report. J Trauma 2007;62:1518–1521
19 Papadopoulos H, Edwards RS. Superolateral dislocation of the condyle: report of a rare case. Int J Oral Maxillofac Surg 2010; 39:508–510
20 Prabhakar V, Singla S. Bilateral anterosuperior dislocation of intact mandibular condyles in the temporal fossa. Int J Oral Maxillofac Surg 2011;40:640–643