Management of a Life Threatening Bleeding Following Extraction of Deciduous Second Molar Related to a Capillary Haemangioma

Amr Amin Ghanem, BDS, MDS, PhD[1] Yasser Nabil el Hadidi, BDS, MDS, MOMS RCSEd[1]

[1] Department of Oral and Maxillofacial Surgery, Faculty of Dentistry, Ain Shams University, Cairo, Egypt

Craniomaxillofac Trauma Reconstruction 2017;10:166–170.

Address for correspondence Yasser Nabil el Hadidi, BDS, MDS, MOMS RCSEd, Department of Oral and Maxillofacial Surgery, Faculty of Dentistry, Ain Shams University, Cairo 11566, Egypt (e-mail: yasserelhadidi@asfd.asu.edu.eg; yelhadid@hotmail.com).

Abstract

Various forms of vascular lesion affect the head and neck region. The head and neck vascular lesions are classified into neoplasms and malformations. Neoplasm presents either as hemangioma or lymphangioma; neoplasm usually presents in young age compared with vascular malformation. A 9-year-old female patient presented to the outpatient clinic referred from the department of pedodontics after extraction of a right mandibular second deciduous molar. Extraction was done by dental GP in outpatient clinic. Massive bleeding followed the extraction. Bleeding was controlled by electrocoagulation of bleeding site and systemic and local application of antifibrinolytic agent. An intravenous line was placed to provide fluid replacement. Injection of intravenous cyklokapron was given to stabilize the blood clot. Selective embolization was performed 24 hours prior to surgical resection of lesion and the lesion was removed under general anesthesia followed by peripheral ostectomy of bone to remove any feeders. Different protocols are used to control life-threatening bleeding. Primary local measures such as Gelfoam packing, Tranexamic or Aminocaproic topical application, Surgicel application, Electrocautery, Bone wax, Ligation of External Carotid or Common Carotid Artery, or Selective Embolization of feeder vessel may be used to control the bleeding. Interventional radiographic blockage of feeder vessel currently shows high success rate in the management of life-threatening bleeding compared with previous techniques.

Keywords
- vascular lesion
- haemangioma
- selective embolization
- bleeding emergency
- pediatric oral surgery

Various forms of vascular lesion affect the head and neck region. The head and neck vascular lesions are classified into neoplasms and malformations.[1] Neoplasm presents either as hemangioma, hemangioendothelioma or angiosarcoma; neoplasm usually present in young age compared with vascular malformation.[2] hemangioma are further classified into congenital, infantile capillary and venous hemangiomas based on histological and clinical features and various terms were used to describe various forms of hemangioma and several classifications were set.[3] Vascular malformations are either high flow or low flow; slow flow lesions are classified into capillary, lymphatic or venous and the fast flow were classified mainly as arterial malformations.[3]

Hemangioma is the most commonly occurring tumor in pediatric population. The rate of occurrence of hemangioma is 4% to 10% in the Caucasian ethnic group. Hemangiomas are three to 5-folds more common in females compared with males. The oral and maxillofacial area is the most affected in the whole body; 60% of all Hemangiomas occur in the craniofacial region.[4]

Several methods are used to stop a life-threatening bleeding in dental office. Primary local measures such as Gelfoam

received
August 11, 2016
accepted after revision
September 27, 2016
published online
March 16, 2017

Copyright © 2017 by Thieme Medical Publishers, Inc., 333 Seventh Avenue, New York, NY 10001, USA.
Tel: +1(212) 584-4662.

DOI http://dx.doi.org/10.1055/s-0037-1598102.
ISSN 1943-3875.

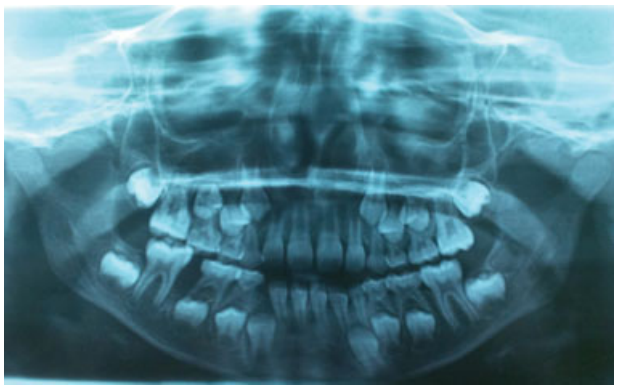

Fig. 1 A preoperative OPG showing slight displacement of lower second deciduous molar and no bone destruction.

packing, Tranexamic or Aminocaproic topical application, Surgicel application, Electrocautery or Bone wax may be used to stop the bleeding. Ligation of external carotid or common carotid artery may manage uncontrolled major bleeding. Interventional radiographic blockage of feeder vessel currently show high success in management of life threatening bleeding compared with all previous techniques.[5]

Case Report

A 9-year-old female patient presented to the outpatient clinic referred from the department of pedodontics for extraction of a right mandibular second deciduous molar. The molar had a carious decay and was mobile; the mobility was attributed by the pediatric staff to the normal exfoliation process sequence. The patient chief complaint was a small swelling related to the molar which was suspected to be pyogenic granuloma because it was red in color, bleeds on touch, soft in texture and associated with badly decayed tooth. Central lesions were excluded; since, the lesion had no radiographic presentation in orthopantomogram (OPG) (►**Fig. 1**).

The extraction was performed under local anesthesia by the general practitioner (GP) dentist in outpatient clinic. Profuse bleeding followed the extraction. Packing and pressure application failed to control the bleeding episode. As the bleeding, increased emergency measures were taken. High volume suction was advocated to identify the bleeder. The bleeding site was from within the bony socket. Electrocoagulation was applied to control the bleeding site. An intravenous line was placed. Saline was administered to achieve open venous access for volume replacement therapy if needed. Injection of intravenous cyklokapron was done to stabilize the blood clot. Once the bleeding was controlled the patient was immediately referred to the internal medicine department to rule out any coagulation anomalies and perform emergency blood transfusion if needed. The patient's hemoglobin had dropped from 9 md/dl prior to extraction to 6.1mg/dl and had series of transfusion to replace the lost volume (►**Fig. 2**).



Fig. 3 Lesion proliferation post extraction.

The case was referred to interventional radiography. CT angiography was performed which confirmed the vascular nature of lesion but failed to confirm a final diagnosis. The treatment plan placed included selective embolization of the feeding vessels followed by excision of the intraoral lesion. The possibility of ligation of the external carotid was not excluded. The lesion expanded enormously and the patient suffered from recurrent bleeding throughout the patient



Fig. 2 Intraoral photographic image showing the socket post extraction bleeding control.



Fig. 4 Showing an extra oral swelling in right side.

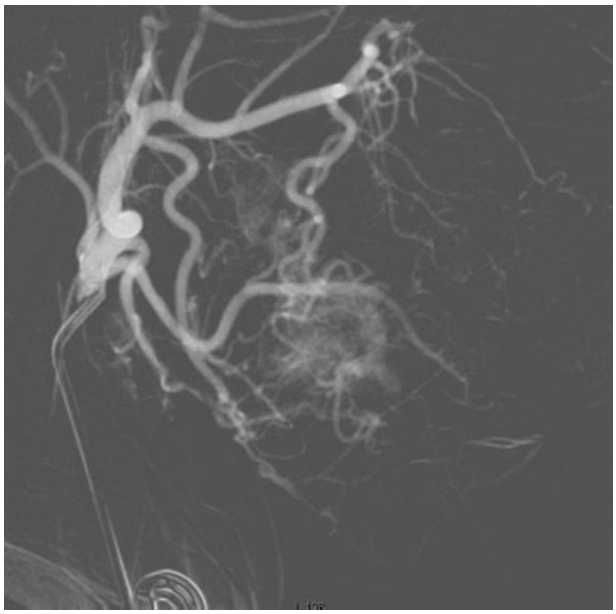

Fig. 5 Angiogram showing vascular lesion related to right side branches of ECA.

preparation phase (►**Fig. 3** and ►**Fig. 4**). Interventional radiographic aids confirmed vascular nature of lesion but failed to confirm a final diagnosis (►**Fig. 5**).

Selective embolization was performed 24 hours using N-butyl cyanoacrylate synthetic polymer prior to the surgical excision of the lesion (►**Fig. 6**) and the lesion was removed under general anesthesia followed by peripheral ostectomy of bone to remove any feeders. Post-operative biopsy results showed that the lesion is a capillary hemangioma (►**Fig. 7**).



Fig. 6 Angiogram showing the lesion site post embolization procedure.



Fig. 7 Intraoral photographic image showing the bleeding site post-surgical resection of lesion.

Discussion

Mulliken and Glowackic classified hemangiomas and vascular malformations giving them significantly different therapeutic approaches. Hemangioma is a true vascular neoplasm histologically formed of multiple blood vessels. On the other hand, AV malformation (AVM) is considered an abnormal communication between arteries and veins. AVM is a result of increased blood flow rather than cell proliferation; hence it is not considered a tumor.[1]

The case under study presented with the following criteria: tooth displacement, positive blood aspiration, and rapid growing lesion with high rate of expansion in response to any local trauma as well as the hemorrhagic episode associated with the extraction. An initial diagnosis of AVM was reached in agreement with Kohout et al.[6]

After performing any dental extraction usually, the tooth and socket is examined to be sure that bony architecture and soft tissue architecture is intact. However, in the current case the GP dentist failed in examining the socket because of perfuse bleeding.[7] Normally, the patient is asked to bite on gauze and is given instruction to avoid clot disruption. If hemostasis is not achieved after 2–3 minutes the wound should be reassessed. However, If the socket keeps oozing after 2–3 minutes of extraction; the blood origin may be vascular, soft tissue or bony in origin. The persistent bleeding should be controlled by electrocautery, ligating, hemostatic gauze, suture, chemical agents (cyklokapron or tranexamic acid) burnishing of bony source of bleeding if possible or inserting bone wax.[7]

The persistent bleeding following those measures is usually of a systemic origin which is either congenital or acquired cause. Congenital defects are either vascular defect as hereditary hemorrhagic telangiectasia, platelets defect as idiopathic thrombocytopenia or coagulation defects as hemophilia. Acquired defects may be associated with liver or renal disease, aspirin therapy, anti-platelet therapy (Plavix), oral anticoagulants (Warfarin) or intravenous anticoagulants (heparin therapy). Transfusion of platelets manages platelets defects, hemophilia disease is managed by providing specific factor replacement and DDAVP, liver and renal disease need referral for adjustment of medical condition, Warfarin action in

reversed by vitamin K administration. Heparin action is reversed by Protamine Sulfate administration.[8] However, in current case all those regimens were of no concern because the cause of bleeding was local from vascular lesion.

To avoid those accidents; the Points to know section in the Canadian dental association journal Web site answered the important question (How do I manage a suspected oral vascular malformation?)[9] The article presented some clinical signs which may raise suspicions to a vascular lesion affecting oral cavity as periodontal bleeding, clinical teeth mobility and occlusal plane affection (super eruption of affected tooth).[10] The article recommended a preoperative radiograph for the suspected area, however in current case the radiographic image didn't show any abnormality.[11] However, the pediatric staff didn't suspect any incidence of vascular lesions and didn't perform aspiration biopsies.

The life-threatening bleeding was controlled by a protocol advocated by Khanna and Dagum.[12] Initially, air way assessment and preservation was achieved via high volume suction; since 93% of cases presented in Khanna and Dagum review[12] suffered initially from airway affection and needed a definitive airway to resuscitate the patient. After air way securing the bleeding was stopped by conservative means as oral packing, applying pressure over wound, local anticoagulant adjunctive agent's applications as tranexamic acid, gauze, gelfoam and cautery.

Systemic administration of cyklokapron injection was advocated for stabilization of the blood clot. Cyklokapron and Tranexamic acid are used a lot to decrease and control postoperative bleeding. Choi et al used those antifibrinolytic agents to decrease post orthognathic surgery bleeding[13] and Song et al used it with children undergoing craniosynostosis to decrease the need of blood transfusion.[14]

Trans catheter arterial embolization was performed by N-butyl cyanoacrylate synthetic polymer in agreement with Alonso et al[15]; prior to the surgical intervention by the interventional radiology team of the hospital. Bouloux et al[16]study showed that Trans catheter arterial embolization replaced conventional extraoral arterial ligation and had more superiority in embolization of inaccessible arteries. Trans catheter arterial embolization showed a 96 percent success rate in controlling of life threatening bleeding as claimed by Khanna et al.[12]

Diagnosis of vascular lesions is usually performed using US color Doppler examination and Angiography.[15] The USS Doppler, CT with contrast and the angiogram confirmed the vascular nature of the lesion. However, no final diagnosis was achievable prior to the surgical intervention.

Different material and protocols of embolization are currently used.[17–20] Longacre et al used silicone balls impregnated with barium or tantalum.[21] Injection of n-butyl cyanoacrylate maybe used and offers more stability.[22] Gel foam resorbs in 1–2 weeks so it can be used only as a temporary mean of vessel obstruction. Polyvinyl alcohol which is used usually in embolization and sclerotherapy also causes a permanent obstruction.[23,24] Immediate intervention and resection within 24–48 hours; must be done to avoid risk of revascularization of lesion.[4] Post-operative biopsy showed numerous thin walled vascular vessels lined by endothelium coinciding with histopathological features of hemangioma.[25]

Conclusion

Minor surgical procedures performed in outpatient clinics may be associated with life threatening bleeding. Dental office armamentarium must include different local measures of management of bleeding emergency. Interventional radiographic blockage of feeder vessel currently show high success in management of life threatening bleeding compared with all previous techniques with minimal morbidity compared with external carotid ligation.

Recommendation

The pediatric staff and the general practitioners should have more training and education regarding clinical steps of screening of oral vascular lesions. Screened out vascular lesions must be treated under hospitals care not in an outpatient clinic to avoid perfuse life threatening bleeding; a preoperative angiogram and selective embolization would have prevented this bleeding episode if the case was properly diagnosed from beginning and a safe tumor excision would have been easily performed with minimal morbidity.

References

1 Vesnaver A, Dovsak DA. Treatment of vascular lesions in the head and neck using Nd:YAG laser. J Craniomaxillofac Surg 2006;34(1): 17–24

2 Mulliken JB, Burrows PE, Fishman SJ. Mulliken and Young's Vascular Anomalies Hemangiomas and Malformations. 2nd ed. New York, NY: Oxford University Press; 2013

3 Lee BB, Laredo J, Lee TS, Huh S, Neville R. Terminology and classification of congenital vascular malformations. Phlebology 2007;22(6):249–252

4 Marler JJ, Mulliken JB. Current management of hemangiomas and vascular malformations. Clin Plast Surg 2005;32(1):99–116, ix ix .

5 Moghadam HG, Caminiti MF. Life-threatening hemorrhage after extraction of third molars:case report and management protocol. J Can Dent Assoc 2002;68(11):670–674

6 Kohout MP, Hansen M, Pribaz JJ, Mulliken JB. Arteriovenous malformations of the head and neck: natural history and management. Plast Reconstr Surg 1998;102(3):643–654

7 McCormick NJ, Moore UJ, Meechan JG. Haemostasis. Part 1: The management of post-extraction haemorrhage. Dent Update 2014; 41(4):290–292, 294–296

8 Gupta A, Epstein JB, Cabay RJ, Cabay RJ. Bleeding disorders of importance in dental care and related patient management. J Can Dent Assoc 2007;73(1):77–83www.cda-adc.ca/jcda/vol-73/issue-1/77.pdf

9 Ray BW, Matthew IR. Point of Care. How do I manage a suspected oral vascular malformation? J Can Dent Assoc 2009;75(8):575–577www.cda-adc.ca/jcda/vol-75/issue-8/575.pdf

10 Johnson LM, Cook H, Friedlander A. Central arteriovenous malformations of the maxillofacial skeleton: case report. J Oral Maxillofac Surg 1991;49(7):759–763

11 Noreau G, Landry P P, Morais D. Arteriovenous malformation of the mandible: review of literature and case history. J Can Dent Assoc 2001;67(11):646–651www.cda-adc.ca/jcda/vol-67/issue-11/646.htm

12 Khanna S and Dagum AB. Critical Review of the Literature and an Evidence-Based Approach for Life-Threatening Hemorrhage in Maxillofacial Surgery. Ann PlastSurg 2012;69:474Y478
13 Choi WS, Irwin MG, Samman N. The effect of tranexamic acid on blood loss during orthognathic surgery: a randomized controlled trial. J Oral Maxillofac Surg 2009;67(1):125–133
14 Song G, Yang P, Zhu S, et al. Tranexamic Acid reducing blood transfusion in children undergoing craniosynostosis surgery. J Craniofac Surg 2013;24(1):299–303
15 Alonso N, Bastos EO, and Massenburg BB. Pseudoaneurysm of the internal maxillary artery: A case report of facial trauma and recurrent bleeding. Int J Surg Case Rep. 2016;21:63–66
16 Bouloux GF, Perciaccante VJ. Massive hemorrhage during oral and maxillofacial surgery: ligation of the external carotid or embolization? J Oral Maxillofac Surg. 2009;67:1547Y1551
17 Gold L, Nazarian LN, Johar AS, Rao VM. Characterization of maxillofacial soft tissue vascular anomalies by ultrasound and color Doppler imaging: an adjuvant to computed tomography and magnetic resonance imaging. J Oral Maxillofac Surg 2003;61(1):19–31
18 Oral and Maxillofacial Surgery: Trauma, surgical pathology, temporomandibular disordersRobert D. MarcianiSaunders/Elsevier; 2009
19 Bhandari P.S, Sadhotra L.P, Bhargava P, Bath A.S, Mukherjee M.K, and Maurya Sanjay. Management strategy for facial arteriovenous malformations.
20 Leikensohn JR, Epstein LI, Vasconez LO. Superselective embolization and surgery of noninvoluting hemangiomas and A-V malformations. Plast Reconstr Surg 1981;68(2):143–152
21 Longacre JJ, Benton C, Unterthiner RA. Treatment of facial hemangioma by intravascular embolization with silicone spheres. Case report. Plast Reconstr Surg 1972;50(6):618–621
22 Han MH, Seong SO, Kim HD, Chang KH, Yeon KM, Han MC. Craniofacial arteriovenous malformation: preoperative embolization with direct puncture and injection of n-butyl cyanoacrylate. Radiology 1999;211(3):661–666
23 Lane F.Donnaldy, Denise M. Vascular malformations and hemangiomas: A practical approach via multidisciplinary clinic. Centennial dissertation. Am J Roentgenol 2000;174:577–608
24 Persky MS, Yoo HJ, Berenstein A. Management of vascular malformations of the mandible and maxilla. Laryngoscope 2003; 113(11):1885–1892
25 Fowell C, Monaghan A, Nishikawa H. Infantile haemangiomas of the head and neck: current concepts in management. Br J Oral Maxillofac Surg 2016;54(5):488–495