Basal Cell Adenoma of Retromolar Region from Minor Salivary Gland Origin in a 45-Year-Old Female: A Case Report

Velavan Krishnan, BDS, MDS (OMFS)[1] Karthik Shunmugavelu, BDS, MSc, MCIP, FIBMS, MASID[2] Jamila Rose, MD[3] Kumaravel Subramaniam, BDS, MDS (OMFS)[4]

[1] Department of Oral and Maxillofacial Surgery, Adiparasakthi Dental College and Hospital, Chennai, Tamilnadu, India
[2] Department of Dentistry and Faciomaxillary Surgery, Kasthuri Multispeciality Hospital, Chennai, Tamilnadu, India
[3] Department of Pathology, Government Stanley Medical College and Hospital, Chennai, Tamilnadu, India
[4] Department of Dentistry and Faciomaxillary Surgery, K.C. Multispeciality Hospital, Chennai, Tamil Nadu, India

Address for correspondence Karthik Shunmugavelu, Department of Dentistry and Faciomaxillary Surgery, Kasthuri Multispeciality Hospital, Shanmugam Road, West Tambaram, Chennai, Tamilnadu 600045, India (e-mail: drkarthiks1981@gmail.com).

Craniomaxillofac Trauma Reconstruction 2017;10:162–165.

Abstract

Basal cell adenoma is a rare benign salivary gland neoplasm. The most common location is in parotid region. Clinically, gradual growth and firm consistency are seen. They account for 1 to 3% among all salivary gland neoplasms. Prominent basaloid cells with cluster of isomorphic cells and interspersed trabeculae are present histopathologically. In this article, we present a rare case of basal cell adenoma of retromolar region from minor salivary gland origin.

Keywords
- salivary gland
- retromolar
- basal cell adenoma
- chondromyxoid matrix
- excisional biopsy

Among the head and neck neoplasms, salivary gland tumors constitute only 2 to 6.5%. Within the salivary gland tumors, only 25% and less is from that of minor origin.[1,2] Among the minor origin, diagnostic challenge was headed by the basaloid group of tumors, constituting 1 to 3%. Being known as monomorphic adenoma (due to resemblance to pleomorphic adenoma) in the past, Kleinsasser and Klein presented the nomenclature as basal cell adenoma in 1967. The gender predominance target females than males, usually in the fifth, sixth, and seventh decades. Histopathologically, this benign epithelial neoplasm lacks chondromyxoid matrix and consists of numerous basaloid cells.[3–7] Microscopically, they are classified as solid, trabecular, tubular, and membranous.[3,8,9] Low recurrence rate has been reported after excisional biopsy of the neoplasm. In this article, we present a rare case of basal cell adenoma of retromolar region from minor salivary gland origin in a 45-year-old female patient.

Case Presentation

A 45-year-old female patient reported to the Department of Dentistry and Faciomaxillary Surgery in 2015, with slowly growing asymptomatic swelling on the right inner posterior part of the cheek present since 6 months. The patient also added that this growth has been progressing since 4 years, but she noticed only before 6 months. On inspection, the right retromolar region appeared normal, while on palpation a 2 × 2 cm, firm, well-circumscribed movable mass was present 2 cm posterior to the right mandibular third molar region (►**Fig. 1**) No ulceration was seen on the overlying mucosa. Differential diagnosis includes basal cell adenocarcinoma, pleomorphic adenoma, adenoid cystic carcinoma, chronic sialadenitis, cutaneous basal cell carcinoma, and metastatic basaloid squamous carcinoma. Treatment procedure was as follows: the growth was excised along with the adjoining normal borders under local

received
November 3, 2015
accepted after revision
January 24, 2016
published online
July 18, 2016

Copyright © 2017 by Thieme Medical Publishers, Inc., 333 Seventh Avenue, New York, NY 10001, USA.
Tel: +1(212) 584-4662.

DOI http://dx.doi.org/10.1055/s-0036-1584394.
ISSN 1943-3875.

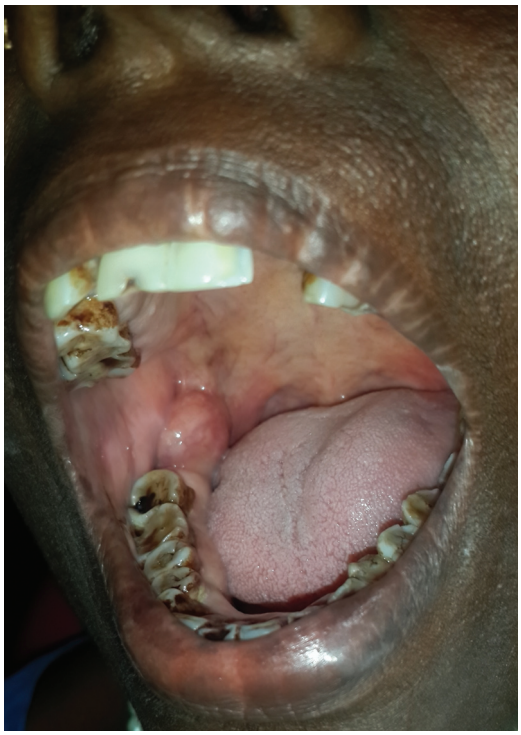

Fig. 1 Preoperative view depicting intraoral mass in right retromolar region.

anesthesia (►**Fig. 2**). Grossly, the lesion was grayish white measuring 2 × 2 cm, encapsulated, round and well demarcated and then the specimen was placed in 10% buffer formalin. The nature of the lesion during the procedure was that of a vascular one. The specimen was stained with eosin and hematoxylin. Histopathologically, underlying connective tissue was covered by orthokeratinized, stratified squamous epithelium. In depth, islands and cords of epithelial cells were seen along with well-circumscribed, encapsulated tumor mass and fibrous stroma. Isomorphic basaloid cells were the pathognomonic feature in association with peripheral palisaded cuboidal to columnar cells in spite of round central cells. Hyperchromatism was observed in peripheral cells, whereas the central ones possessed pale stained nuclei. Based on the features, it was diagnosed as basal cell



Fig. 2 Postoperative excised specimen.

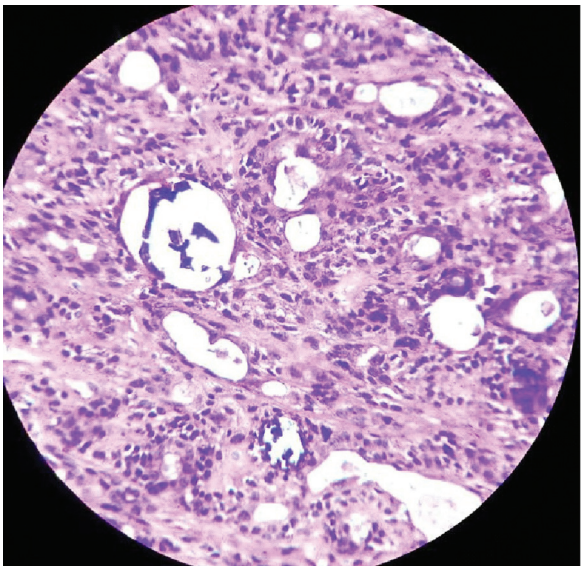

Fig. 3 High power view (hematoxylin and eosin, ×40) showing tubules lined by luminal epithelial cells and basal myoepithelial cells surrounded by a fibrous stroma.

adenoma. Minor features such as squamous whorls and acinar cells were also seen (►**Figs. 3–6**). Uneventful postoperative period was followed by absence of recurrence in a span of 6 months.

Discussion

In the past, basal cell adenoma was referred to as monomorphic adenoma. Lack of chondromyxoid material and presence of basaloid cells modified the name as basal cell adenoma. Basal cell adenoma usually affects individuals in their fifth, sixth, or seventh decades with a predilection towards female gender.

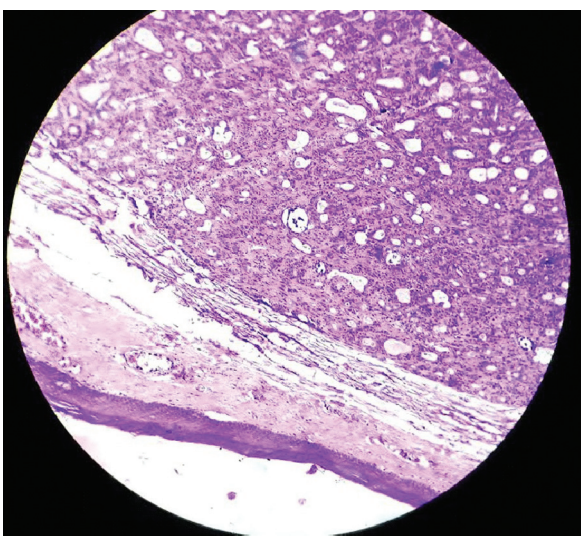

Fig. 4 Low power view (hematoxylin and eosin, ×10) shows squamous mucosa and an underlying well-encapsulated neoplasm showing tubular, acinar, and trabecular pattern.

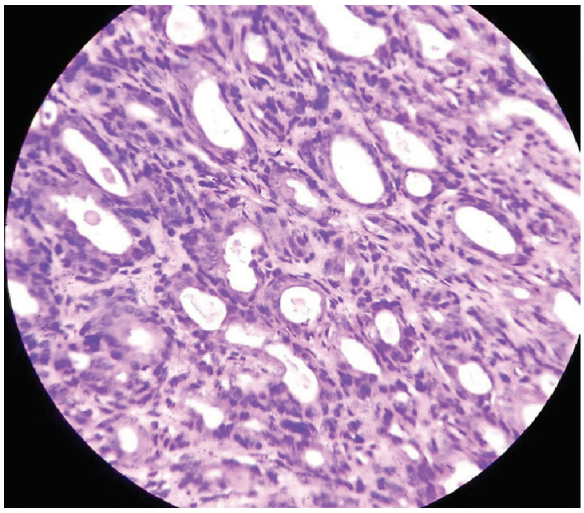

Fig. 5 High power view (hematoxylin and eosin, ×40) showing uniform basaloid cells forming tubules with intraluminal secretions. No atypia or mitosis evident.

Brooke-Spiegler syndrome comprises of basal cell adenoma and adnexal tumors. The proportion of the neoplasm varies as follows: 1 to 3% of major salivary gland tumors, 7.5% of primary epithelial parotid gland tumors and 54% of monomorphous adenomas. The most common location is in the parotid gland, especially in the superficial lobe.[10–14] This article illustrates a rare case of basal cell adenoma in the retromolar region. Routine appearance is that of well-circumscribed border with round or oval shape unilaterally. Clinical features include painless mass, slow progressive enlargement and a measurement of 3 to 8 cm. A rare case of bilateral basal cell adenoma has been reported by Katsuno et al in a 65-year-old woman, specificity in parotid gland. The features of the excised mass usually consists of grayish white appearance, rich in blood supply, well circumscribed, encapsulated, soft to firm consistency, which might be sometimes cystic or solid in nature.[15–19] Among the solid, tubular, trabecular and membranous, membranous type is histologically distinctive due to its multifocal and multimodal character. Histopathological features include basaloid epithelial cells, uniform, dark, small, encapsulated, peripheral palisading of epithelial nests resulting in basaloid appearance. The cellular arrangement may be of trabecular, solid, tubular and membranous. Yadav et al reported a sixth case of palatal basal cell adenoma in 55-year-old woman, followed by complete tumor excision. The study also added that factors such as age, gender, and method of diagnosis and treatment play an important role in the outcome.[20] On comparison, our case report of basal cell adenoma of retromolar region in a 45-year-old female is the first case to be reported in literature in relation to retromolar region. Histopathologically, a combined tubular, acinar and trabecular pattern followed by basaloid cells and myoepithelial cells were seen. Our treatment plan such as excisional biopsy played a major role in complete removal of the lesion followed by definitive outcome. The malignant part is known as basal cell adenocarcinoma. Infiltrative growth of basal cell adenocarcinoma differentiates from that of basal cell adenoma. Common features of both the neoplasm are squamous morules, haphazard cellular arrangement, basaloid cells, intercellular matrix, peripheral palisading, and cellular aspirate. Differential diagnosis includes basal cell adenocarcinoma, adenoid cystic carcinoma, benign mixed tumor, chronic sialadenitis, cellular pleomorphic adenoma, metastatic basaloid squamous carcinoma, cutaneous basal cell carcinoma, and sialoblastoma. These types of neoplasms are treated by complete surgical excision with negative margins.[21–24]

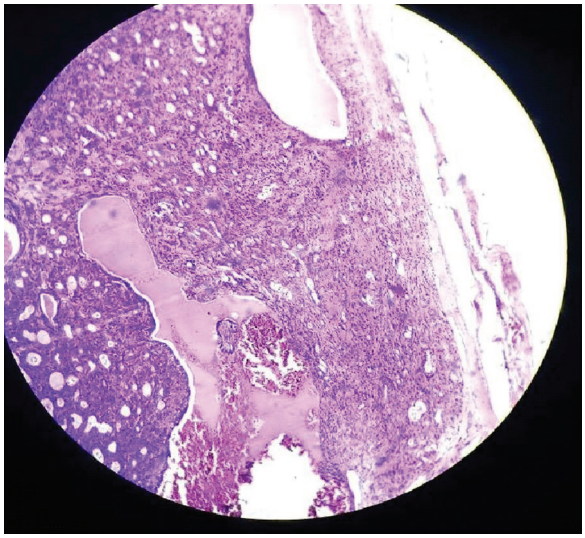

Fig. 6 Scanner view (hematoxylin and eosin, ×5) showing benign cells forming tubules, glands and nests with distinct peripheral nuclear palisading.

Conclusion

In spite of radiological and clinical techniques, histopathology plays an important role in the definitive diagnosis. Differential diagnosis of the malignant counterparts is mandatory. This rare case of basal cell adenoma in the retromolar region has been confirmed histopathologically.

References

1 Leegard T, Lindeman H. Salivary gland tumours: clinical picture and treatment. Acta Otolaryngol Suppl 1969;263:55–59
2 Eveson JW, Cawson RA. Tumours of the minor (oropharyngeal) salivary glands: a demographic study of 336 cases. J Oral Pathol 1985;14(6):500–509
3 Minicucci EM, de Campos EB, Weber SA, Domingues MA, Ribeiro DA. Basal cell adenoma of the upper lip from minor salivary gland origin. Eur J Dent 2008;2(3):213–216
4 Basal Cell Adenoma. Available at: http://medical-dictionary.thefreedictionary.com/basal+cell+adenoma
5 Takeshita T, Tanaka H, Harasawa A, Kaminaga T, Imamura T, Furui S. CT and MR findings of basal cell adenoma of the parotid gland. Radiat Med 2004;22(4):260–264
6 González-García R, Nam-Cha SH, Muñoz-Guerra MF, Gamallo-Amat C. Basal cell adenoma of the parotid gland. Case report and review of the literature. Med Oral Patol Oral Cir Bucal 2006; 11(2):E206–E209

7 Basal Cell Adenoma. Available at: http://www.pathconsultddx.com/pathCon/diagnosis?pii=S1559-8675 (06)70109-. Accessed June 13, 2016
8 Machado de Sousa SO, Soares de Araújo N, Corrêa L, Pires Soubhia AM, Cavalcanti de Araújo V. Immunohistochemical aspects of basal cell adenoma and canalicular adenoma of salivary glands. Oral Oncol 2001;37(4):365–368
9 Seifert G, Donath K. Hybrid tumours of salivary glands. Definition and classification of five rare cases. Eur J Cancer B Oral Oncol 1996; 32B(4):251–259
10 Choi HR, Batsakis JG, Callender DL, Prieto VG, Luna MA, El-Naggar AK. Molecular analysis of chromosome 16q regions in dermal analogue tumors of salivary glands: a genetic link to dermal cylindroma? Am J Surg Pathol 2002;26(6):778–783
11 Ellis G. Basal cell adenocarcinoma. In: Barnes L, Eveson JW, Reichart P, Sidransky D, eds. World Health Organization Classification of Tumours: Head and Neck Tumours. Lyon: IARC Press; 2005:229–230
12 Kawahara A, Harada H, Akiba J, Yokoyama T, Kage M. Fine-needle aspiration cytology of basal cell adenoma of the parotid gland: characteristic cytological features and diagnostic pitfalls. Diagn Cytopathol 2007;35(2):85–90
13 Muller S, Barnes L. Basal cell adenocarcinoma of the salivary glands. Report of seven cases and review of the literature. Cancer 1996;78(12):2471–2477
14 Nagao T, Sugano I, Ishida Y, et al. Basal cell adenocarcinoma of the salivary glands: comparison with basal cell adenoma through assessment of cell proliferation, apoptosis, and expression of p53 and bcl-2. Cancer 1998;82(3):439–447
15 Yerli H, Teksam M, Aydin E, Coskun M, Ozdemir H, Agildere AM. Basal cell adenoma of the parotid gland: dynamic CT and MRI findings. Br J Radiol 2005;78(931):642–645
16 Hemachandran M, Lal A, Vaiphei K. Basal cell adenoma-an unusual presentation. Ann Diagn Pathol 2003;7(5):292–295
17 Katsuno S, Ishii K, Otsuka A, Ezawa S, Usami S. Bilateral basal-cell adenomas in the parotid glands. J Laryngol Otol 2000;114(1):83–85
18 Hall-Craggs M, Toker C. Basaloid tumor of the sigmoid colon. Hum Pathol 1982;13(5):497–500
19 Chow LT, Chow WH. Co-existing pleomorphic and tubular basal cell adenomas of the parotid gland. J Laryngol Otol 1997;111(2): 182–185
20 Yadav AB, Narwal A, Devi A, Kumar S, Yadav SK. Basal Cell Adenoma of Palate, a Rare Occurrence with Review of Literature. J Dent (Shiraz) 2015;16(3, Suppl)291–295
21 Chow LT, Chow WH. Co-existing pleomorphic and tubular basal cell adenomas of the parotid gland. J Laryngol Otol 1997;111(2):182–185
22 Chiu NC, Wu HM, Chou YH, et al. Basal cell adenoma versus pleomorphic adenoma of the parotid gland: CT findings. AJR Am J Roentgenol 2007;189(5):W254-61
23 Luna MA, Batsakis JG, Ordóñez NG, Mackay B, Tortoledo ME. Salivary gland adenocarcinomas: a clinicopathologic analysis of three distinctive types. Semin Diagn Pathol 1987;4(2):117–135
24 Gupta N, Jadhav K, Ahmed MB, Amberkar VS. Basal cell adenoma in a relatively rare site. J Oral Maxillofac Pathol 2009;13(2):101–104