Penetrating Craniomaxillofacial Injury Caused by a Pneumatic Nail Gun

Kevin Jae Choi, MD, MS[1] Marisa Ann Ryan, MD[1] Tracy Cheng, BS[1] David Powers, MD, DMD[2]

[1] Division of Head and Neck Surgery and Communication Sciences, Department of Surgery, Duke University Medical Center, Durham, North Carolina
[2] Division of Plastic, Maxillofacial and Oral Surgery, Department of Surgery, Duke University Medical Center, Durham, North Carolina

Address for correspondence Kevin Jae Choi, MD, MS, Division of Head and Neck Surgery and Communication Sciences, Department of Surgery, Duke University Hospital, Box 2824, Durham, NC 27710 (e-mail: kevin.choi@dm.duke.edu).

Craniomaxillofac Trauma Reconstruction 2017;10:159–161.

Abstract

Craniomaxillofacial injuries can be complex, requiring a multidisciplinary approach. The primary survey is always the first step in trauma management prior to proceeding with further evaluation and treatment. A 26-year-old man presented with a penetrating nail gun injury through the oral and nasal cavities. He did not present in extremis but required elective endotracheal intubation for intraoperative assessment and treatment. Airway management was enhanced by the use of lingual nerve and inferior alveolar nerve blocks via the Vazirani-Akinosi technique to maintain spontaneous respiration while the tongue was distracted from the palate. The nail was removed and rapid sequence induction initiated for orotracheal intubation. Local nerve blocks can be an effective tool in the armamentarium of the craniomaxillofacial trauma surgeon in managing blunt and penetrating injuries. We demonstrate its utility in airway management when a penetrating foreign body in the upper airway precludes orotracheal or nasotracheal intubation.

Keywords
- nail gun injury
- penetrating craniomaxillofacial injury
- pneumatic nail gun

Since the first report in 1959, nail gun injuries have become increasingly common.[1] The Centers for Disease Control and Prevention estimates 37,000 emergency room visits annually due to nail gun injuries. Up to 66% of these injuries are attributed to occupational hazards.[2] Nail gun injuries to the extremities are common, but craniomaxillofacial (CMF) injuries are relatively rare, comprising only 0.1% of all nail gun injuries.[2,3] Such nail gun injuries are usually associated with a good prognosis because pneumatic nail guns commonly produce low velocity projectiles.[4] However, catastrophic consequences such as neurological deficits, vascular injuries, and death have been reported due to damage to the compact and complex anatomy of the CMF skeleton.[5,6] We report a case of CMF trauma caused by a pneumatic nail gun where local nerve blocks were performed to assist in successful endotracheal intubation prior to surgical management of the penetrating injury.

Case Report

A 26-year-old man presented to the emergency department following a work-related pneumatic nail gun accident. The trajectory of the nail lacerated the lower lip and penetrated the tongue and hard palate. The tongue was tethered to the palate but was not edematous (►**Fig. 1**). The patient had significant trismus and dysarthria, but did not demonstrate signs of acute or impending airway obstruction. No neurologic deficits were identified. Tetanus immunoglobulin and Tdap were administered as the patient had an unknown immunization history.[7] CT scan demonstrated a penetrating foreign body through the hard palate, bilateral nasal cavities, and left ethmoid sinus with the distal tip embedded in the left cribriform plate without intracranial extension (►**Fig. 2**).

Intraoperatively, a right lingual nerve block and bilateral inferior alveolar nerve blocks were accomplished via the

received
January 9, 2016
accepted after revision
March 4, 2016
published online
June 27, 2016

Copyright © 2017 by Thieme Medical Publishers, Inc., 333 Seventh Avenue, New York, NY 10001, USA.
Tel: +1(212) 584-4662.

DOI http://dx.doi.org/10.1055/s-0036-1584405.
ISSN 1943-3875.



Fig. 1 Nail penetrating through the oral cavity into the nasal cavity, before and after tongue mobilization following local nerve block administration.

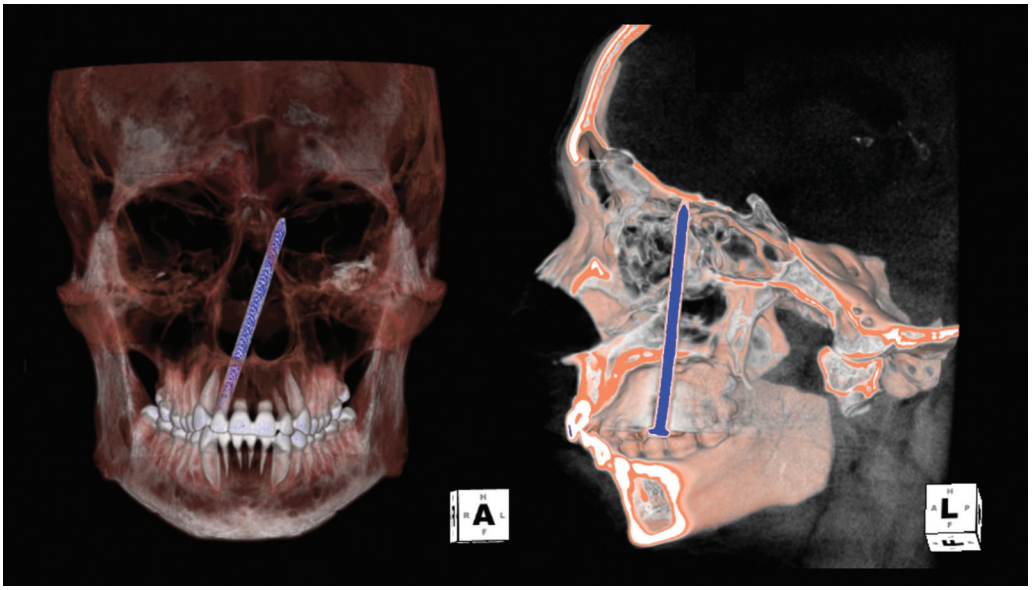

Fig. 2 Computed tomographic reconstruction of penetrating nail through the oral cavity, nasal cavity onto the skull base.

Vazirani-Akinosi technique. The tongue was pulled inferiorly over the nail head to free it from the palate and to relieve the trismus (►**Fig. 1**). Rapid sequence induction followed by orotracheal intubation was performed by the anesthesia team. The zero-degree endoscope was used to examine the nasal cavities and the nail was visualized without evidence of cerebrospinal fluid (CSF) leak. The nail was removed through the oral cavity and repeat endoscopic evaluation demonstrated no evidence of residual foreign body, bleeding, or CSF leak (►**Fig. 3**). The lower lip laceration was repaired and the tongue was left to heal by secondary intent. Patient was discharged from the hospital on postoperative day 1, tolerating a soft diet.

The patient was reevaluated in our CMF trauma and rhinology clinic within 2 weeks of discharge. Patient did not have any sinonasal complaints or evidence of a CSF leak. His injuries were well healed without evidence of oronasal fistula. The patient was given return precautions prior to discharge from our clinic.

Discussion

CMF injuries can be complex, requiring a multidisciplinary approach in devising a treatment plan. Penetrating nail gun injuries require careful evaluation, due to the risk of injuries to neurovascular structures.[6] Commercial nails may also be associated with barbs, washers, and possibly carcinogenic epoxides that must be addressed during surgical removal and care of the injury.[8,9] Despite the rather impressive radiological findings, nail gun injuries to the head without intracranial penetration or vascular injuries are associated with good prognoses.[10,11] Pneumatic nail gun injuries, in particular, are associated with better prognoses than bullet wounds with a similar trajectory because the nail enters at a much lower speed.[4] With lower kinetic energy upon entry, the projectiles are often not powerful enough to penetrate fascial planes or bone to cause injuries to important neurovascular structures.

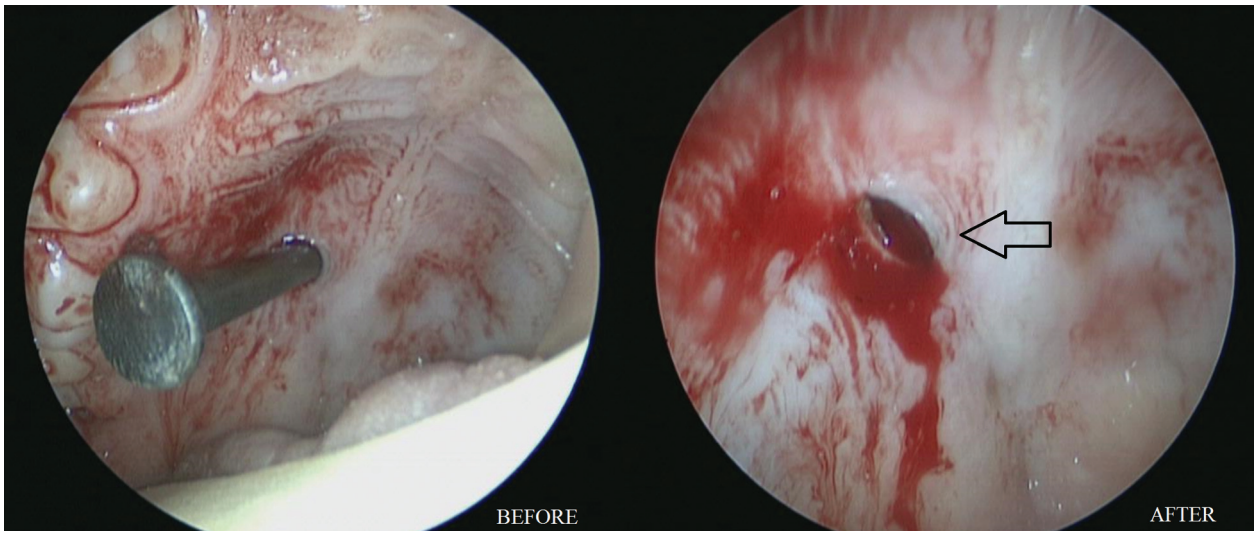

Fig. 3 Hard palate before and after nail removal. The wound (arrow) was allowed to heal by secondary intent.

This case presented a challenge in acute airway management. The penetrating injury through the oral cavity prevented the use of standard equipment to perform a direct laryngoscopy. The projection of the nail onto the anterior skull base through the nasal cavity precluded nasal fiberoptic intubation. Despite the injuries, patient remained neurologically intact, protecting his airway and there was no significant edema of the tongue to prompt an emergent tracheotomy. Through the use of local nerve blocks, adequate analgesia was provided for successful mobilization of the tongue to gain access for orotracheal intubation. This case demonstrates the use of local blocks as an adjunctive measure in successful airway management in acute trauma. Local blocks should not be overlooked and remain as a vital tool in the armamentarium of the CMF trauma surgeon.

References

1 Delsol-Liebel MA, Kaminishi RM, Pineda A. Nail gun injury to the maxillofacial region: report of a case. J Oral Maxillofac Surg 1996; 54(5):632–634
2 Centers for Disease Control and Prevention (CDC). Nail-gun injuries treated in emergency departments—United States, 2001-2005. MMWR Morb Mortal Wkly Rep 2007;56(14): 329–332
3 Schaller BJ, Kleindienst A, Kruschat T, Schliephake H, Buchfelder M, Merten HA. Industrial nail gun injury to the anterior skull base: a case report and review of the literature. J Trauma 2008;64(3): E29–E32
4 Buchalter GM, Johnson LP, Reichman MV, Jacobs J. Penetrating trauma to the head and neck from a nail gun: a unique mechanism of injury. Ear Nose Throat J 2002;81(11):779–783
5 Rezai AR, Lee M, Kite C, Smyth D, Jafar JJ. Traumatic posterior cerebral artery aneurysm secondary to an intracranial nail: case report. Surg Neurol 1994;42(4):312–315
6 Selvanathan S, Goldschlager T, McMillen J, Campbell S. Penetrating craniocerebral injuries from nail-gun use. J Clin Neurosci 2007; 14(7):678–683
7 Advisory Committee on Immunization Practices. Recommended adult immunization schedule: United States, 2012. Ann Intern Med 2012;156(3):211–217
8 Lee AD, Oh YS. Unusual delayed presentation of a nail gun injury through the skull base. Laryngoscope 2007;117(6):977–980
9 Bruno JR, Levin LM, Stanton DC. Pneumatic nail gun injury to the maxillofacial region: case report. J Trauma 1998;45(2):410–412
10 Lee CS, Park KH. Six nails in the head: multiple pneumatic nail gun head injury. Br J Neurosurg 2010;24(4):493–494
11 Woodall MN, Alleyne CH Jr. Nail-gun head trauma: a comprehensive review of the literature. J Trauma Acute Care Surg 2012;73(4): 993–996