Immediate Surgical Management of Traumatic Dislocation of the Eye Globe into the Maxillary Sinus: Report of a Rare Case and Literature Review

Samer Abduljabar Noman, BDS, MSc, DDS, PhD[1] Mostafa Ibrahim Shindy, BDS, MSc, DDS, PhD[2]

[1] Department of Oral and Maxillofacial Surgery, Faculty of Oral and Dental Medicine, Sana'a University, Sana'a, Yemen
[2] Department of Oral and Maxillofacial Surgery, Faculty of Oral and Dental Medicine, Cairo University, Cairo, Egypt

Address for correspondence Samer Abduljabar Noman, BDS, MSc, DDS, PhD, Department of Oral and Maxillofacial Surgery, Faculty of Oral and Dental Medicine, Sana'a University, Algahm'ah Street, Sana'a, Yemen (e-mail: samer_noman@yahoo.com).

Craniomaxillofac Trauma Reconstruction 2017;10:151–158.

Abstract

We report a case of complete dislocation of the globe into the maxillary sinus, with immediate repositioning of the globe. This report highlights the importance of early surgical repair of orbital fracture and globe repositioning to regain the maximum amount of ocular functions. A review of literature found 19 cases of globe dislocation into the maxillary sinus: One case was enucleated 2 months after misdiagnosis as traumatic enucleation, six cases were documented no vision or no light perception, three cases did not have reported vision (patients did not survive), and nine cases with postoperative vision. We recommend early surgical intervention to restore the cosmetic and visual function of the dislocated eye.

Keywords
- globe dislocation
- orbital fracture
- optic nerve
- eye

Traumatic orbital floor fractures with complete globe dislocations into the maxillary sinus are rare presentation and often result in no light perception vision. We report a case with recovery of visual acuity after initial no light perception vision.

Displacement of the globe into the paranasal sinuses can be explained by mechanism of blowout fracture. Orbital blowout fracture will act similar to a pressure valve in that the force of the blow to the eye, in addition to being absorbed by the adnexal structures of the globe, will also be absorbed by the bony rupture of the medial orbital wall, the orbital floor, and compression of air within the paranasal sinuses.[1]

Two mechanisms are possible explanations for blowout fractures. The first is called the buckling effect: forces affecting the orbital rims generating transient deformations that are transmitted to the orbital floor and leading to the blow out. The second mechanism is called the hydraulic effect. In this theory, the traumatic force causes an increase in orbital pressure that results in a fracture of the orbital floor as one of the weak borders of the orbit.[2]

The periorbital tissues act as soft tissue padding and are able to dissipate considerable energy. Thus, blunt trauma to the ocular region can produce significant contusions and fractures of the orbit (especially the orbital floor), while causing little or no damage to the globe itself.[1,3]

According to Amaral et al,[4] traumatic globe luxation can be divided in two types: (1) when the globe is displaced forward the orbit anteriorly (anterior globe luxation) and (2) when the globe is displaced into the paranasal sinuses or anterior cranial fossa.

Hypothetical causes of anterior globe luxation were proposed by Morris et al[5]: (1) an elongated object enters the medial orbit using the nasal sidewall as a fulcrum, propelling the globe forward and (2) a wedge-shaped object enters the orbit medially and displaces the globe anteriorly.

Displacement of the globe into the paranasal sinuses can be explained by mechanism of blowout fracture. When strong blunt forces are applied to the globe fracturing, the thin orbital walls displace the globe. Direct orbital trauma with fractures of medial and floor walls displacing the globe into

received
November 25, 2015
accepted after revision
February 28, 2016
published online
June 24, 2016

Copyright © 2017 by Thieme Medical Publishers, Inc., 333 Seventh Avenue, New York, NY 10001, USA.
Tel: +1(212) 584-4662.

DOI http://dx.doi.org/10.1055/s-0036-1584393.
ISSN 1943-3875.

the paranasal sinuses proved to be the most common cause of traumatic globe luxation.[6]

The present report describes a rare case of complete dislocation of the globe into the maxillary sinus, with immediate repositioning of the globe. This report highlights the importance of early surgical repair of orbital fractures and globe repositioning to regain the maximum amount of ocular functions.

Case Report

A 24-year-old woman was referred to the emergency unit because of a blunt injury to the right orbital region when she was accidentally hit by blunt wooden object during her rehearsal session at the opera theater.

On examination, the patient had a right periorbital hematoma. The eyelids were closed and could not be opened by the patient. During palpation, no disruption of the orbital rims could be found. Skin laceration of the upper right eyelid was noticed. Manual opening of the eyelids were performed and the right globe could not be visualized (anophthalmic right orbital cavity) (►**Fig. 1**). Using a fiber optic bright light for transmaxillary illumination on the right maxillary region, the patient had no light perception.

Computed tomography (CT) scan of the orbit and the midface revealed a blowout fracture of the posterior part of the right orbital floor with a complete dislocation of the intact globe into the right maxillary sinus (►**Fig. 2**).

The patient was taken immediately to the operating room and the dislocated globe was repositioned manually into the orbit via combined transmaxillary and transconjunctival approaches.

A right maxillary antrostomy was performed utilizing 8 mm diameter atraumatic dome-shaped sinus lateral window bur to avoid further injury to the displaced globe. After the antrostomy, the globe was noted to be completely contained within the right maxillary sinus (►**Fig. 3**). Gentle finger pressure was applied at the inferior aspect of the globe to guide the globe cephalically from the maxillary sinus into the orbital cavity. The tone and consistency of the globe was normal on palpation (►**Fig. 4**).

Titanium mesh carefully adapted to fit the bony anatomic contours of the remaining orbital walls. Stable bone around the defect was exposed to allow the mesh to rest on sound bone on all margins of the defect. Anteriorly, the mesh was secured to the inferior orbital rim with screw fixation. The proximal extent of the floor defect was observed extending far posteriorly without sound bony margin, thus a second mesh applied directly through maxillary sinus antrostomy inferiorly and fixed at the superior–posterior maxillary sinus wall to support the globe and orbital contents posteriorly. Maxillary antrostomy was repaired by titanium mesh and screw fixation (►**Fig. 5**) followed by intraoral and transconjunctival wounds closer.

Postoperative, 250 mg of intravenous methylprednisolone was administered every 6 hours for 3 days. Postoperative CT showed good repositioning of the globe (►**Fig. 6**).

Immediate postoperative patient reported no light perception. Light perception vision was tested daily with multiple attempts. The patient was discharged to home with a rapid oral prednisone taper over 7 days. On postoperative day 8, the visual acuity improved to light perception. The patient reported marked improvement in vision at postoperative week 4. On postoperative week 7, her vision was noted to be 6/12 OD equivalent to United States (20/40 OD). Over the next several months, the visual acuity stabilized at 6/12 and she continued to have an afferent pupillary defect with reduced motility and diplopia in the lateral gaze, her visual function continues to remain stable 10 months after the initial trauma and the patient has a good cosmetic result (►**Fig. 7**).

Discussion

Traumatic displacement of the globe is a rare event that can be classified into three categories: luxation, dislocation, and avulsion. Dislocation can be defined as the migration of the globe into the paranasal sinuses, nasal cavity, or anterior cranial fossa.[3]

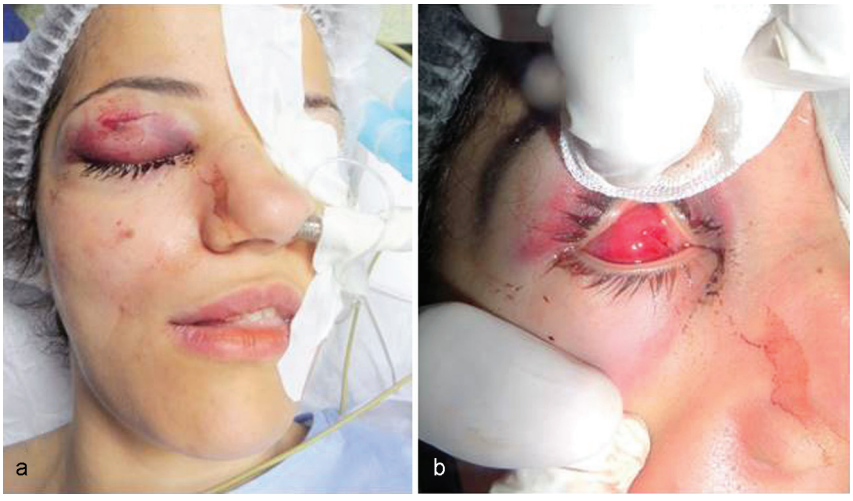

Fig. 1 (**a**) Periorbital hematoma and skin laceration of the upper right eyelid. (**b**) Manual opening of the eyelid without any evidence of the eyeball (anophthalmic right orbital cavity).

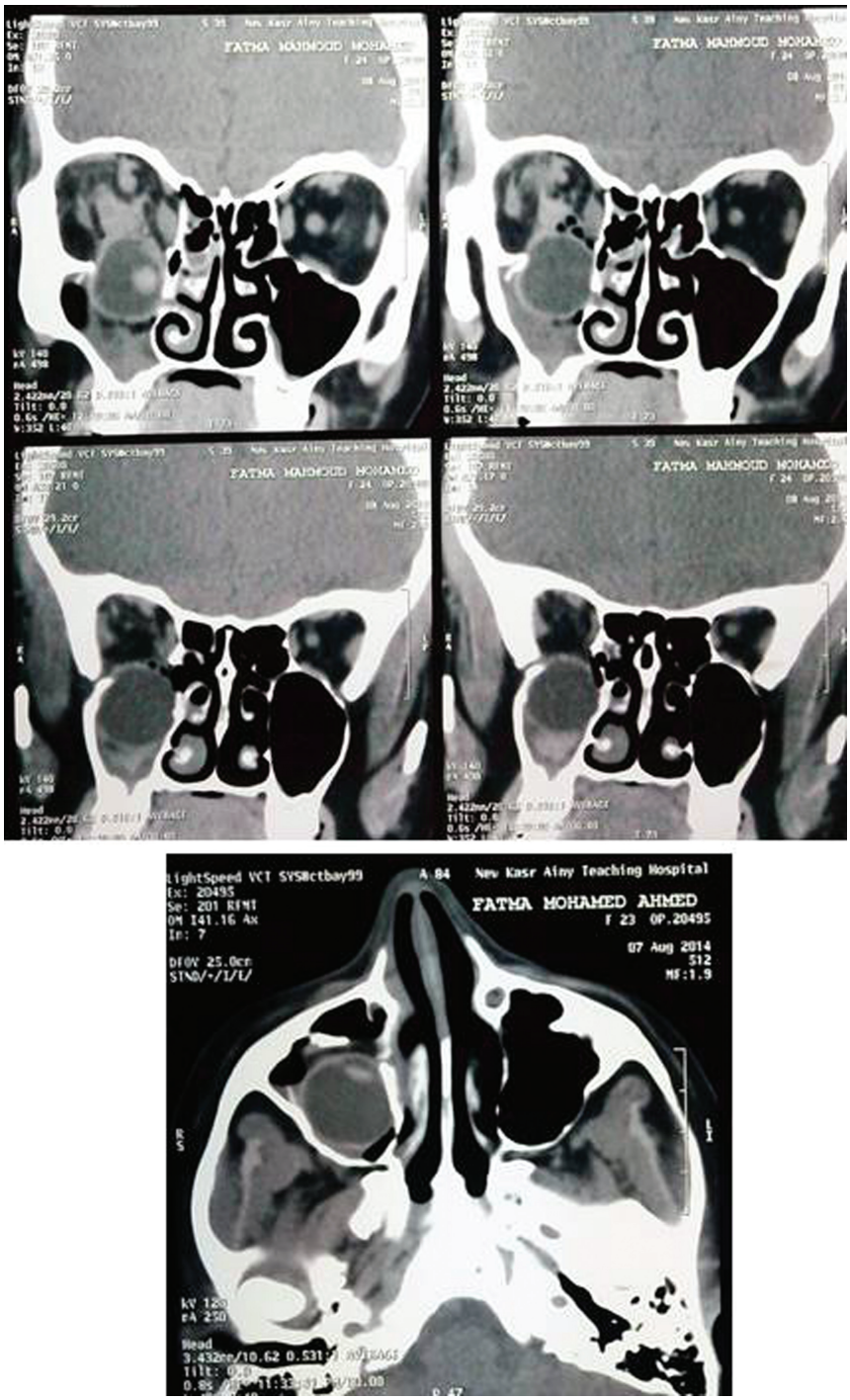

Fig. 2 Preoperative coronal and axial computed tomography scan images showing the right globe completely dislocated into the maxillary sinus.

Previous case reports were researched by detailed investigation of the English-language literature by searching for the following keywords: traumatic dislocation of the globe, traumatic luxation of the globe, traumatic prolapse of the globe, and traumatic displacement of the globe. In the English-language literature, 45 cases (including anterior luxation, dislocation into anterior cranial fossa, and dislocation into paranasal sinuses) have been reported.

Anterior or forward luxation of the globe 18 cases.[4,5,7–19]
Globe dislocation into anterior cranial fossa 3 cases.[20–22]
Globe dislocation into ethmoid sinus 5 cases.[23–27]
Globe dislocation into maxillary sinus 19 cases.[1,3,6,28–42]

We found 19 cases of globe dislocation into the maxillary sinus summarized in ►**Table 1** as follows:

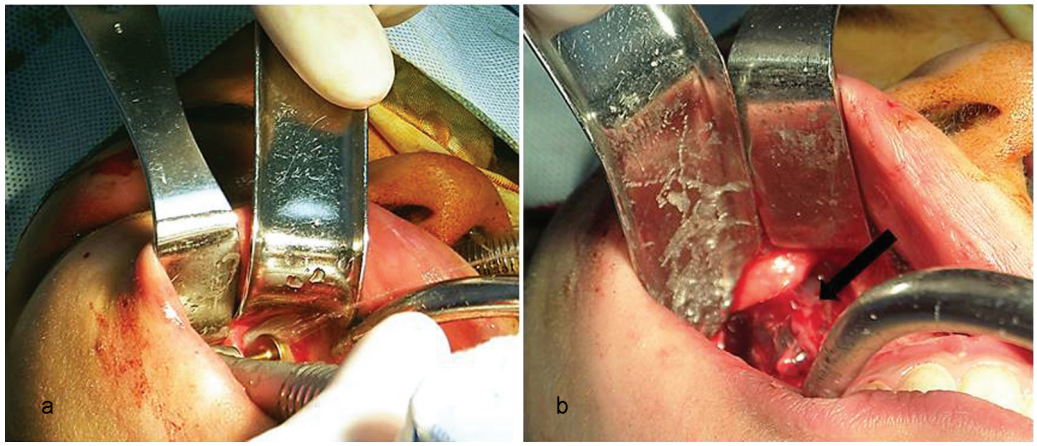

Fig. 3 (**a**) Antrostomy by 8 mm diameter atraumatic dome-shaped sinus lateral window bur. (**b**) The globe (arrow) completely dislocated and contained within the right maxillary sinus.

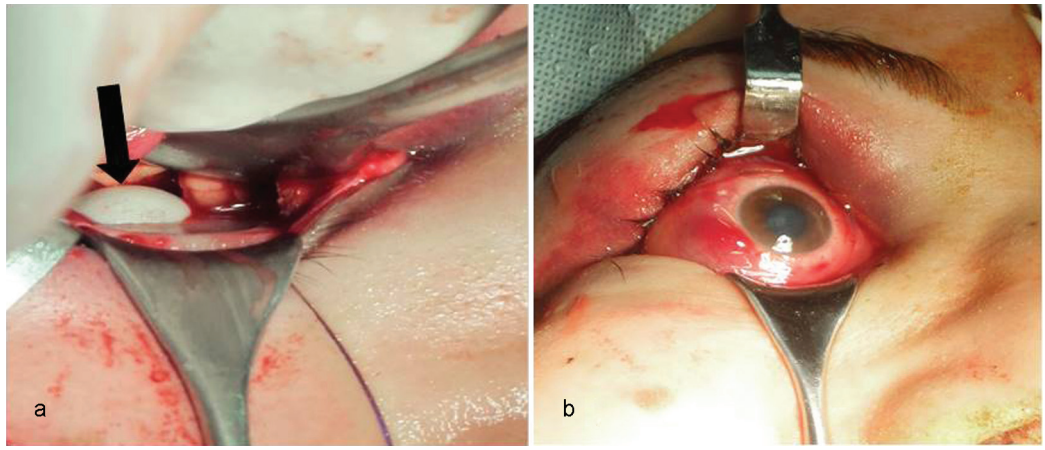

Fig. 4 (**a**) Gloved finger (arrow) introduced inferiorly from the maxillary sinus protruding through orbital floor defect. (**b**) Right globe repositioned within the orbital cavity.

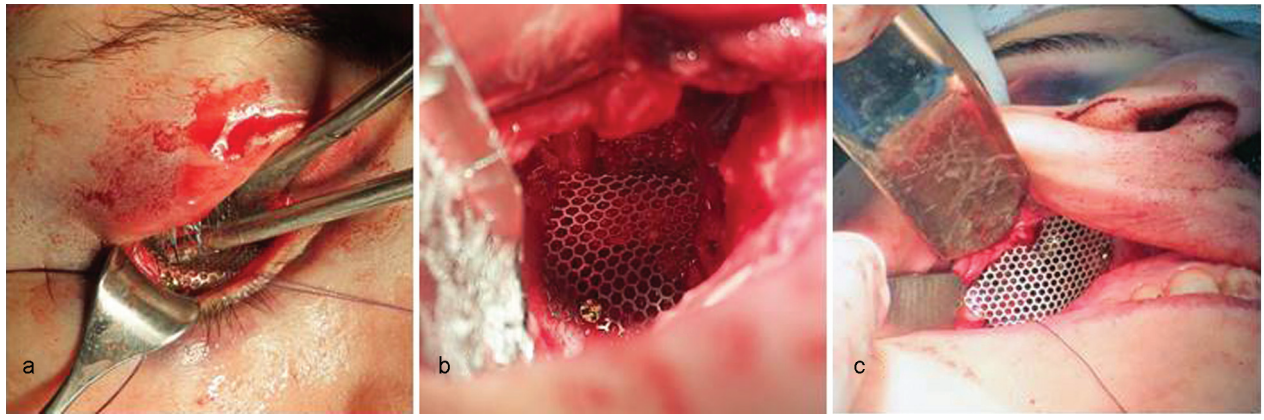

Fig. 5 (**a**) Titanium mesh reconstruct orbital floor defect. (**b**) Second mesh applied through antrostomy to support the globe posteriorly. (**c**) Maxillary antrostomy repaired by titanium mesh.

One was enucleated 2 months after misdiagnosis as traumatic enucleation.[32]
Seven were documented no vision or no light perception.[6,29,31,34,35,42]
Three did not have reported vision.[1,3,38]
Nine had postoperative vision.[3,28,30,33,36,37,39–41]

Our case represents the 20th reported case of dislocated globe into maxillary sinus, the 10th case with postoperative vision

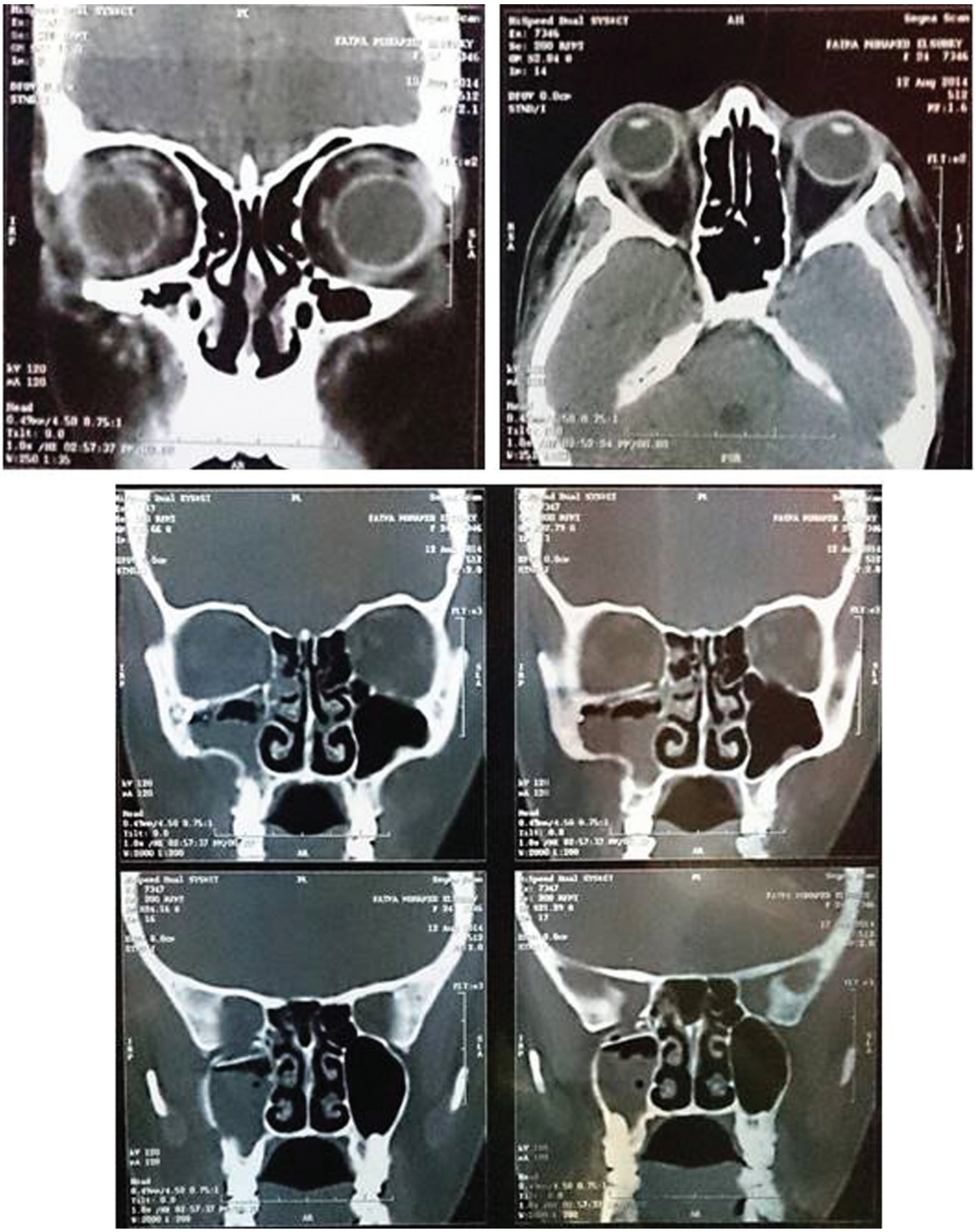

Fig. 6 Postoperative coronal and axial CT scan images showing good repositioning of the globe. Coronal CT scan images showing the posterior extent of the reconstructed defect. CT, computed tomography.

recovery, and the 2nd reported case with recovery of visual acuity after initial postoperative no light vision (►**Table 1**).

The optic nerve has an excess reserve length of 8 mm inside the orbit, which saves it in the event of huge proptosis and globe displacements. The possible mechanism of the optic nerve injury was assumed to be stretching, rotation, and kinking of the nerve fibers causing mechanical damage to the nerve and a possible ischemia due to shearing of vessels and vascular compression. Being a sensory tract, it is not covered by the neurilemma; therefore, there is no regenerative potential when severed and any resulting visual loss will be permanent.[27]

The pathogenesis outlined earlier may explain blindness as Roth et al[43] concluded that traumatic optic nerve neuropathy should be treated as a cell death inducing increased



Fig. 7 Postoperative appearance after repositioning of the right globe with good cosmetic outcome.

intraneuronal pressure complicated by ischemia, axone rupture, and electrolyte imbalance of adjacent tissues just like in spinal paraplegia.

Salvaging the eye in this situation is a surgical challenge. Visual prognosis is generally poor in such cases since the retina and optic nerve are very sensitive to the injury and ischemia, although recovery of a normal vision has been reported in some cases.[3,28,30,33,36,37,39–41]

The obtained outcome in the present case supports the opinion of Müller-Richter et al[36] as they stated in their discussion that the very satisfying results were due to the fact that the orbital floor broke in the posterior part, reducing the strain on the muscles and optic nerve during the dislocation, and preventing their laceration.

Time is a major factor in the management of traumatic globe dislocations. An eye dislocated out of the orbital socket is under serious vascular compromise and sustains severe mechanical damage and early surgical intervention significantly reduces the ocular morbidity.[27]

Although controversy exists regarding the specific surgical and medical management of grossly displaced globes, most investigators have agreed that every attempt should be made to anatomically reposition a displaced globe within the orbital pyramid as soon as possible.[42] Treatment delays

Table 1 Reported cases of globe dislocation into the maxillary sinus

	Age	Sex	Visual acuity	Motility	Pupillary defect	Diplopia
Berkowitz et al (1981)	12	F	Recovery 20/20	NA	NA	NA
Smit et al (1990)	28	M	No	NA	NA	NA
Ziccardi et al (1993)	35	M	Recovery 20/20	Restricted motility	NA	Yes (primary gaze)
Pelton et al (1998)	19	M	NA	NA	NA	NA
Tung et al (1998)	17	M	No	Minimal horizontal gaze and no vertical gaze	NA	NA
Saleh and Leatherbarrow (1999)	29	M	No	NA	NA	NA
Kim and Baek (2005)	68	M	No	Restricted motility	Nonreactive mydriatic pupil	NA
Müller-Richter et al (2007)	62	M	Recovery 20/20	Reduced motility	Anisocoria with dilation of the pupil	Yes (lateral gaze and upward)
Abrishami et al (2007)	18	M	No	Limited in all gazes	Nonreactive mydriatic pupil	NA
Avadhanam et al (2008)	30	F	No	Good motility in all gazes	Nonreactive mydriatic pupil	NA
Kreiner et al (2008)	50	M	No	loss of ocular motility	Nonreactive mydriatic pupil	NA
Ramstead et al (2008)	32	M	Recovery 20/200	Minimal horizontal gaze and no vertical gaze	Afferent pupillary defect	NA
Jellab et al (2008)	24	M	Light perception	Reduced motility	NA	NA
Jellab et al (2008)	50	F	NA	NA	NA	NA
Akhaddar et al (2010)	62	M	NA	NA	NA	NA
Damasceno and Damasceno (2010)	42	M	Recovery 20/20	Loss of ocular motility (except for abduction)	No	Yes
Zhang-Nunes et al (2012)	20	M	Recovery 20/25	NA	Afferent pupillary defect	NA
Xu et al (2013)	46	F	Light perception	Restricted motility	NA	NA
Haggerty and Roman (2013)	35	M	Light perception	Restricted motility	Nonreactive mydriatic pupil	NA
Noman and Shindy (2015)	24	F	Recovery 20/40	Reduced motility in lateral gaze	Afferent pupillary defect	Yes (lateral gaze)

Abbreviation: NA, not available.

increase the risk of complications as edema and strain on the optic nerve and central retinal artery increase with time. The period that the central retinal artery is twisted or stretched further compromises the blood supply to the optic nerve, increasing the probability of irreversible vision loss.[6]

Early surgical intervention significantly reduces the ocular morbidity. Restoration of the eye movements and orbital volume could be aesthetically and emotionally acceptable to the patient as a minimum, if function could not be restored with the best possible efforts.

Conclusion

The present case shows that there is a possibility of regaining fair visual acuity, even though the initial visual acuity was extremely poor due to traumatic dislocation of the eyeball into the maxillary sinus. We recommend early treatment in cases such as our case. Early surgical interventions would help restore the cosmetic and visual function of the dislocated eye.

Acknowledgments

We express our thanks to the patient for her consent to being reported on in this article. Special thanks to Dr. Aya El-Hamalawy for photo documentation of this article.

References

1 Pelton RW, Rainey AM, Lee AG. Traumatic subluxation of the globe into the maxillary sinus. AJNR Am J Neuroradiol 1998;19(8): 1450–1451
2 Ahmad F, Kirkpatrick WN, Lyne J, Urdang M, Garey LJ, Waterhouse N. Strain gauge biomechanical evaluation of forces in orbital floor fractures. Br J Plast Surg 2003;56(1):3–9
3 Jellab B, Baha AT, Moutaouakil A, et al. Management of a severe cranio-orbito-facial trauma with a dislocation of the globe into the maxillary sinus. Bull Soc Belge Ophtalmol 2008;309–310; (309–310):37–41
4 Amaral MB, Carvalho MF, Ferreira AB, Mesquita RA. Traumatic globe luxation associated with orbital fracture in a child: a case report and literature review. J Maxillofac Oral Surg 2015;14 (Suppl 1):323–330
5 Morris WR, Osborn FD, Fleming JC. Traumatic evulsion of the globe. Ophthal Plast Reconstr Surg 2002;18(4):261–267
6 Kreiner B, Amer R, Sharfi G, Solomon A, Ilsar M. Traumatic displacement of the globe into the paranasal sinuses: case report and guidelines for treatment. J Oral Maxillofac Surg 2008;66(4): 826–830
7 Reuling FH, Hadlund RL. Traumatic luxation of the globe. Eye Ear Nose Throat Mon 1970;49(3):129–130
8 Pillai S, Mahmood MA, Limaye SR. Complete evulsion of the globe and optic nerve. Br J Ophthalmol 1987;71(1):69–72
9 van der Wal KG, van der Pol BA. Traumatic luxation of the eyeball. J Craniomaxillofac Surg 1991;19(5):205–207
10 Zengin N, Karakurt A, Gültan E, Kural G. Traumatic globe luxation. Acta Ophthalmol (Copenh) 1992;70(6):844–846
11 Arkin MS, Rubin PA, Bilyk JR, Buchbinder B. Anterior chiasmal optic nerve avulsion. AJNR Am J Neuroradiol 1996;17(9):1777–1781
12 Kiratli H, Tümer B, Bilgiç S. Management of traumatic luxation of the globe. A case report. Acta Ophthalmol Scand 1999;77(3): 340–342
13 Bajaj MS, Kedar S, Sethi A, Gupta V. Traumatic globe luxation with optic nerve transection. Orbit 2000;19(3):165–170
14 Alp B, Yanyali A, Elibol O, Talu H, Karabas L. A case of traumatic globe luxation. Eur J Emerg Med 2001;8(4):331–332
15 Bajaj MS, Pushker N, Nainiwal SK, Balasubramanya R. Traumatic luxation of the globe with optic nerve avulsion. Clin Experiment Ophthalmol 2003;31(4):362–363
16 Song A, Carter KD. Bilateral traumatic globe subluxation. Ophthal Plast Reconstr Surg 2006;22(2):136–137
17 Lelli GJ Jr, Demirci H, Frueh BR. Avulsion of the optic nerve with luxation of the eye after motor vehicle accident. Ophthal Plast Reconstr Surg 2007;23(2):158–160
18 de Saint Sardos A, Hamel P. Traumatic globe luxation in a 6-year-old girl playing with a tube of wrapping paper. J AAPOS 2007; 11(4):406–407
19 Roldan-Valadez E, Corona-Cedillo R, Rojas-Marin C, Valdivieso-Cardenas G, Sanchez-Sanchez JM, Quiroz-Mercado H. Tomographic findings in traumatic globe evulsion caused by blunt head trauma. Br J Radiol 2007;80(958):e247–e249
20 Shimia M, Sayyahmelli S. Traumatic Displacement of the Globe into Brain. RMJ 2009;34(2):234–235
21 Vahdati SS, Sadeghi H. Orbital roof fracture: dislocation of globe into the anterior cranial fossa. JAEMCR 2011;2:47–49
22 Gollapudi PR, Nandigama PK, Maila SK, Karla R, Kotakadira S. Traumatic intracranial prolapse of eye ball - a case report. Br J Neurosurg 2013;27(1):114–116
23 Risco JM, Stratas BA, Knott RH. Prolapse of the globe into the ethmoid sinus. Am J Ophthalmol 1984;97(5):659–660
24 Moon M, Pietris G, Shapter M. Dislocation of the globe into the ethmoid sinuses. Aust N Z J Ophthalmol 1997;25(2):175–176
25 Kang BD, Jang MH. A case of blowout fracture of the orbital wall with eyeball entrapped within the ethmoid sinus. Korean J Ophthalmol 2003;17(2):149–153
26 Okabe H, Kimura K, Sonoda S, Sakamoto T. Displacement of globe into ethmoid sinus by orbital medial wall fracture with good recovery of vision. Jpn J Ophthalmol 2005;49(5):426–428
27 Tranfa F, Di Matteo G, Di Salle F, Strianese D, Bonavolontà G. Traumatic displacement of the globe into the ethmoid sinus. Am J Ophthalmol 2000;130(2):253–254
28 Berkowitz RA, Putterman AM, Patel DB. Prolapse of the globe into the maxillary sinus after orbital floor fracture. Am J Ophthalmol 1981;91(2):253–257
29 Smit TJ, Koornneef L, Zonneveld FW. A total orbital floor fracture with prolapse of the globe into the maxillary sinus manifesting as postenucleation socket syndrome. Am J Ophthalmol 1990;110(5): 569–570
30 Ziccardi VB, Patterson GT, Ramasastry S, Sotereanos GC. Management of a severe zygomatico-orbital fracture with dislocation of the globe into the antrum. J Craniofac Surg 1993;4(2):95–101
31 Tung TC, Chen YR, Santamaria E, Chen CT, Lin CJ, Tsai TR. Dislocation of anatomic structures into the maxillary sinus after craniofacial trauma. Plast Reconstr Surg 1998;101(7):1904–1908
32 Saleh T, Leatherbarrow B. Traumatic prolapse of the globe into the maxillary sinus diagnosed as traumatic enucleation of the globe. Eye (Lond) 1999;13(Pt 5):678–680
33 Avadhanam VS, Sreedhara SP, Ameerally P, El-Ghazali KMS. Traumatic globe dislocations-Significance of early intervention. Inj Extra 2008;39:356–358
34 Kim S, Baek S. Traumatic dislocation of the globe into the maxillary sinus associated with extraocular muscle injury. Graefes Arch Clin Exp Ophthalmol 2005;243(12):1280–1283
35 Abrishami M, Aletaha M, Bagheri A, Salour SH, Yazdani S. Traumatic subluxation of the globe into the maxillary sinus. Ophthal Plast Reconstr Surg 2007;23(2):156–158
36 Müller-Richter UD, Kohlhof JK, Driemel O, Wagener H, Reichert TE. Traumatic dislocation of the globe into the maxillary sinus. Int J Oral Maxillofac Surg 2007;36(12):1207–1210

37 Ramstead C, McCabe J, Alkahtani M, Leong-Sit J, Morhart M. Traumatic dislocation of the globe into the maxillary sinus. Can J Ophthalmol 2008;43(3):364–366
38 Akhaddar A, Elmostarchid B, Boucetta M. Images in emergency medicine. Traumatic intraorbital stone with globe displacement into the maxillary sinus. Emerg Med J 2010;27(11):828
39 Damasceno NAP, Damasceno EF. Traumatic orbital fracture with intact ocular globe displacement into the maxillary sinus. Rev Bras Oftalmol 2010;69:52–54
40 Zhang-Nunes SX, Jarullazada I, Mancini R. Late central visual recovery after traumatic globe displacement into the maxillary sinus. Ophthal Plast Reconstr Surg 2012;28(1): e17–e19
41 Xu B, Xu XL, Yan J. Treatment of traumatic globe dislocated completely into the maxillary sinus. Int J Ophthalmol 2013;6(1):106–107
42 Haggerty CJ, Roman P. Repositioning of a traumatically displaced globe with maxillary antrostomy: review of the literature and treatment recommendations. J Oral Maxillofac Surg 2013;71(11): 1915–1922
43 Roth J, Hingst V, Lenz JH. Blindness following severe midfacial trauma—case report and review. J Craniomaxillofac Surg 2012; 40(7):608–613