A 14-Year Review of Craniomaxillofacial Gunshot Wounds in a Resource-Limited Setting

Olushola Amole, BDS, FMCDS[1] Otasowie Osunde, BDS, FWACS[2] Benjamin Akhiwu, BDS, FMCDS[1] Akinwale Efunkoya, BDS, FMCDS[1] Kelvin Omeje, BDS, FMCDS[1] Taiwo Amole, MBBS, FWACP[3] Zubairu Iliyasu, MBBS, MPH, FWACP[3]

[1] Department of Oral and Maxillofacial Surgery, Bayero University/ Aminu Kano Teaching Hospital, Kano, Nigeria
[2] Maxillofacial Unit, Department of Dental Surgery, University of Calabar Teaching Hospital, Calabar, Nigeria
[3] Department of Community Medicine, Bayero University/Aminu Kano Teaching Hospital, Kano, Nigeria

Address for correspondence Ibiyinka Olushola Amole, BDS, FMCDS, Department of Oral and Maxillofacial Surgery, Bayero University, Aminu Kano Teaching Hospital, Kano, Nigeria (e-mail: solaziggy@yahoo.com).

Craniomaxillofac Trauma Reconstruction 2017;10:130–137.

Abstract

This study analyzed the prevalence, clinical characteristics, and management of civilian-type craniomaxillofacial gunshot wounds (CGSWs) seen over a 14-year period in a Northern Nigerian teaching hospital. A retrospective study of all hospital records relating to CGSWs from January 2000 to December 2013 was conducted to determine the prevalence of CGSWs. Information retrieved included site of injury, type of projectile, management protocol, as well as duration of hospitalization. A total of 46 admissions for CGSWs were recorded during the period under review from a total of 2,228 maxillofacial admissions. This gave a prevalence of 2.1% for CGSWs (95% confidence interval = 1.56–2.81). Sex distribution was 14.3:1 (M:F) with overall mean age of 32.9 ± 8.4 years. Average length of hospitalization was 17.7 (±15.56) days. Management of CGSWs consisted of emergency care, preliminary intervention, definitive reconstruction, revisions, and rehabilitation. Conclusively, analysis of the yearly incidence of CGSWs showed that the incidence and severity increased within the past 2 years under review (18 cases, 39.13%; χ^2 trend = 7.7, $p = 0.006$). This period was noted to correspond with heightened violence within the region mostly due to the acts of unknown gunmen and insurgents.

Keywords
- craniomaxillofacial
- gunshot wounds
- insurgents

Civilian-type, high-energy (HE) craniomaxillofacial gunshot wounds (CGSWs) were rare in Northern Nigeria[1] many decades ago, but there have been recent reports of an increased incidence.[2,3] An increase in regional conflicts within the African subcontinent may have facilitated an influx of military-type weaponry into the region with a resultant increased incidence of CGSWs.[3–5] Over the past 5 years, there has been increased religious insurgency in the region with the use of military-type weaponry in these conflicts.

Lethality of gunshot wounds depends on the weapon's caliber or grade, gun/projectile combinations, and firing distance among other factors.[6,7] Close-range, high-velocity gunshot wounds to the head and neck region frequently result in debilitating and mutilating facial injuries. These are characterized by severe bone fragmentation and soft-tissue avulsion in high velocity impact injuries with splintered bone fragments acting as less energized secondary missiles.[7] Such injuries present a reconstructive challenge frequently requiring both soft- and hard-tissue reconstruction.

received
February 5, 2015
accepted after revision
August 18, 2015
published online
March 6, 2017

Copyright © 2017 by Thieme Medical Publishers, Inc., 333 Seventh Avenue, New York, NY 10001, USA.
Tel: +1(212) 584-4662.

DOI http://dx.doi.org/10.1055/s-0037-1601341.
ISSN 1943-3875.

A primary one-stage (soft tissue, hard tissue, or composite) reconstruction is the preferred treatment option over the conventional delayed reconstruction approach.[8,9] One-stage reconstruction has been proven to reduce postoperative morbidity, shorten hospitalization, and reduce number of hospital admissions.[8–11] Despite various Nigerian publications on CGSWs,[1–4] little is known about the current prevalence and changing trends of CGSWs in Northern Nigeria. The objective of this study was to determine the pattern, characteristics, ballistics, and trends of CGSWs managed in a Northern Nigerian tertiary hospital over a 14-year period. This study also seeks to describe the management protocol for CGSWs at the center.

Methods

A retrospective review of all admitted cases of CGSWs from January 2000 to December 2013 at the Aminu Kano Teaching Hospital (AKTH), Kano, was conducted. AKTH is a tertiary health facility located in North-West Nigeria which serves as a major referral center for the region. Information on patients admitted for gunshot wounds for the duration was obtained from admission records. Case files were retrieved from the hospital health registry for analysis. Data retrieved from case files included sociodemographic characteristics, cause of injury, and duration of hospitalization. In addition, clinical and radiological findings, such as exit and entry wound sites, type of wounding object (bullet, pellet, "radiologically missing"), injury patterns/concomitant injuries, details on emergency care, type of definitive care, and complications were also collated.

Data analysis was done using the Statistical Package for Social Sciences software version 15.0 (SPSS Inc., Chicago, IL). The period prevalence and 95% confidence interval were computed. Period prevalence before and during the insurgency period was compared using the Pearson chi-square test. Quantitative data were summarized using mean and standard deviation. Differences between means were tested using Student *t*-test. A *p*-value of <0.05 was considered statistically significant.

Management Algorithm for CGSWs

Gunshot patients were admitted through the emergency department of the hospital. Emergency management of fresh gunshot victims was done to stabilize victims following advanced trauma life support protocols. A preliminary survey was done at this time to determine the presence of other injuries which would require further emergent intervention. Following emergency management and patient stabilization, initial surgical management was done which usually involved wound debridement and skeletal stabilization. Minimal soft-tissue revision may be done at this stage with the aim of ensuring soft-tissue coverage of exposed bone. In some cases, definitive surgical management can be done at this time depending on wound severity.

Definitive management was guided by the functional and aesthetic demands related to the injury and could range from local advancement to pedicled flaps with or without bone grafts. Definitive management is often delayed for approximately 7 days after gunshot trauma in our center, to allow proper definition of the wound and defects for reconstruction. Soft-tissue configurational defects were acquired from both firearm-related avulsions and defects created, by the excision of contracture, consequent to healing of "injury altered" soft tissues which grossly limited oral functions. The use of pedicled deltopectoral, sternomastoid, submental, Abbe, forehead, *bandoneon*, and other local advancement soft-tissue flaps were frequently employed to restore soft-tissue defects where indicated (►**Table 1**). These flaps are surgically developed and care is taken so as not to injure their major axial supply. They are subsequently anchored to the prepared recipient tissue bed with sutures for 21 days

Table 1 Categories of definitive care given in 28 patients with CGSWs

Site	Configurational Defect	Surgical Intervention	No. of patients	Outcome
Mandible	Lower lip and bone	Mandibular rec/ iliac / bandoneon flap	3	Poor denture stability/retention
Mandible	Lower lip/cheek/bone	Mandibular rec/ iliac /DPF/SG	2	Poor denture stability/retention
Mandible	Lower lip/bone	Miniplate/iliac/DPF/SG/Abbe flap	2	Poor denture stability/retention
Mandible	Bone	Miniplate /Iliac/mandibular fragments/LAP	7	Poor denture stability/retention
Maxilla	Upper lip and bone	Obturator /Forehead flap	4	Satisfactory
Mandible	Fractures	ORIF(miniplates)	8	Satisfactory
Cheek	Cheek Orocutaneous salivary fistula	Submental flap	1	Satisfactory
Submental region	Submental Orocutaneous salivary fistula	Sternomastoid flap	1	Satisfactory
		Total =	28	

Abbreviations: DPF, deltopectoral flap; LAP, local advancement flap; Mandibular rec, Mandibular reconstruction plate; ORIF, open reduction and internal fixation; SG, skin graft.

(for *neovascularization*) before insetting the flap and returning the carrier portion. Donor site defects are covered with dermatome-harvested split thickness skin grafts from the hairless and color-matched anterolateral thigh region. Autogenous anterior iliac crest bone grafts are frequently used to bridge composite oromandibular continuity defects anchoring with 2.5-mm nonlocking *stainless steel* mandibular reconstruction or miniplates and screws (Orthomax, Navadurga, Gujarat, India). These grafts are harvested using a mallet and chisel and can be used as either bone chips or corticocancellous bone and often used in conjunction with wound-acquired autogenous mandibular fragments.

Results

During the study period, 46 CGSW admissions were made from a total of 2,228 maxillofacial inpatient admissions. This gave a period prevalence of 2.1% of maxillofacial admissions. Only six CGSW admissions involved female patients giving a gender ratio (M/F) of 14.3:1. Patients' ages ranged from 17 to 54 years, with a mean (±SD) of 32.9 ± 8.4 years. The pre-insurgency period (2000–2011) recorded a prevalence percentage of 1.54% (28 CGSWs out of 1,817 admissions) compared with 4.37% that characterized the insurgency period (2012–2013, 18 CGSWs of 411 admissions). ►**Table 2** shows percentage of the annual prevalence of admissions indicating significant increase in trend of CGSWs over the 14-year period (χ^2 trend = 7.7, $p = 0.006$). Majority of CGSW admissions were observed in the past 2 years (2012–2013), as also shown in ►**Fig. 1**, with HE CGSW admissions being greater for this period.

Table 2 Analysis for linear trend in proportions of craniofacial gunshot wound admissions

Year	CGSWs admissions	Total admissions	Annual prevalence
2000	0	65	0
2001	2	78	2.5%
2002	2	86	2.3%
2003	2	140	1.4%
2004	3	150	2.0%
2005	3	157	1.9%
2006	1	209	0.5%
2007	1	100	1.0%
2008	2	202	1.0%
2009	4	217	1.84%
2010	4	201	1.99%
2011	4	212	1.88%
2012	10	205	4.9%
2013	8	206	3.9%
2000-2013	46	2,228	2.1%

Note: χ^2 trend = 7.7, $p = 0.006$.

Etiology of injury for the 46 patients over the study duration was armed robbery (31 cases, 67.4%), unknown gunmen (11 cases, 24%), and accidental police discharge (4 cases, 8.7%). For the past 2 years (2012–2013), etiology of injury was distributed as unknown gunmen (11 cases, 61.1%), armed robbery (6 cases, 33.3%), and police discharge (1 case, 5.6%). Projectile entry points were varied with the mandible having the highest value (16 cases, 33.3%), followed by the cheek (13 cases, 28.3%) and nose (5 cases, 10.9%). Other entry points were the submental region, ear, orbital margins, zygoma, lip (2 cases each, 4.3% each), and temporal and mastoid regions (1 case each, 2.2% each). However, only 15 cases had exit wounds which were also distributed in various sites. It was statistically significant that there were more radiologically identifiable projectiles during the pre-insurgency period than in the period of insurgency (87.1 vs. 12.9%, Fisher exact test, $p = 0.0001$. This tendency was buttressed by the incidence of greater tissue disruption and avulsions during the insurgency period with a statistically significant difference ($\chi^2 = 14.2$, $p = 0.0001$) due to heavier caliber weapons.

The distribution of injury type along with the pattern of soft- and hard-tissue injuries are presented in ►**Table 3**. Concomitant injuries occurred in seven (15.2%) cases: dura tear in combination with frontal lobe contusion ($n = 2$; 4.3%), isolated dura tear ($n = 1$), soft-tissue injury to the upper limbs ($n = 3$), and bilateral fractured humeri ($n = 1$). Four patients (8.7%) were referred to our center for definitive reconstruction. Preliminary treatment was provided in 42 cases (91.3%). Four of these patients (8.7%) required tracheostomy and one patient (2.2%) required arrest of severe hemorrhage. Tracheostomy was necessitated by severe bilateral mandibular comminution with loss of tongue support (two patients) and bleeding from floor of the mouth/avulsed palatal segments and airway edema (two patients). The observed complications are presented in ►**Table 4**. The management of 18 patients (37%) stopped at emergency care and preliminary management, which involved wound debridement/missile extraction, skeletal stabilization, and suturing. ►**Table 1** shows the categories of definitive care given in 28 patients with CGSWs.

Twenty-two (47.8%) out of the 46 patients treated required rehabilitation which was in the form of dental prosthesis ($n = 8$), physiotherapy ($n = 6$), dental prosthesis/physiotherapy ($n = 5$), and ocular prosthesis/physiotherapy ($n = 3$). The duration of hospital stay ranged from 3 to 62 days with mean (±SD) of 17.7 (±15.56) days.

Discussion

This study was hospital based and retrospective; thus, prevalence rates of CGSWs obtained from such studies may be under-reported. Several patients may have died before reaching the hospital and thus would not be included in these data. Also, several patients may have gone to other hospitals in the region for treatment. An increase in incidence of CGSWs was observed from 2009, with majority of the cases in the final years of the study attributed to "unknown gunmen." This may be attributable to the

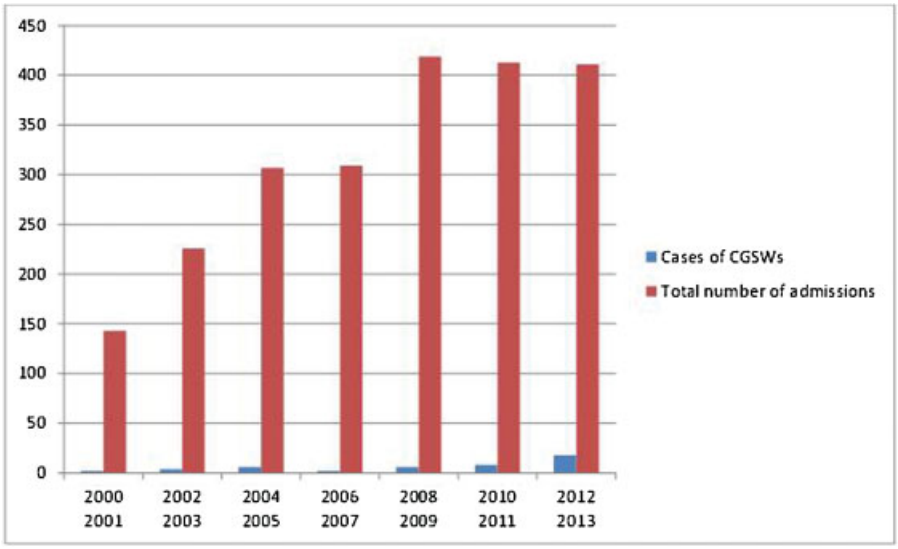

Fig. 1 Schematic representation of craniomaxillofacial gunshot wounds (CGSWs) relative to total number of patients.

activities of religious insurgents/terrorists which appeared to have occurred more as isolated attacks. Insurgency/terrorist activities in Northern Nigeria commenced around September 2009 but reached a peak in January 2012 with more than 3,000 recorded firearm and ordinance explosion deaths.[12]

There was also a change in pattern of injuries from non-avulsive to avulsive in the later part of the review period. This

Table 3 Distribution of projectile type, injury type and pattern of soft and skeletal injuries

VARIABLE		2000–2011	2012–2013	TOTAL (2000–2013)
Projectile	Missing	1(6.7)	14(93.3)	15(100.0)
	Pellets/bullets	27(87.1)	4(12.9)	31(100.0)
	Total	**28(60.9)**	**18(39.1)**	**46(100.0)**
Injury Type	Avulsive	9(36.0)	16(64.0)	25(100.0)
	Non-avulsive	19(90.5)	2(9.5)	21(100.0)
	Total	**28(60.8)**	**18(39.1)**	**46(100.0)**
Soft Tissue Injury	Avulsed lip	2	4	6
	Avulsed cheek	1	3	4
	Lacerated cheek	1	3	4
	Parotid injury	1	6	7
	Forehead laceration	0	1	1
	Globe rupture	0	3	3
	Abrasion	5	0	5
	Total	10	20	30
Hard tissue Injury	Mandible	15	9	24
	Zygoma	2	1	3
	Maxilla	1	1	2
	Zygoma/mandible	0	2	2
	Others*	0	4	4
	Total	18	17	35

Projectile analysis: Fisher's Exact test; Injury type analysis: $p = 0.0001$; $\chi^2 = 14.2$; df $= 1$; $p = 0.0001$ respectively.
*Others: NOE, Maxilla and mandible, Frontal and NOE and Mandible, Maxilla and NOE

Table 4 Complications arising from maxillofacial gunshot injuries

Complications	Frequency	Percentage
Teeth avulsion	14	32.6
Facial nerve injury	8	18.6
Limited mouth opening	7	16.3
Oroantral/salivary fistula	4	9.3
Microstomia	4	9.3
Visual loss	3	7.0
Inferior alveolar nerve damage	2	4.7
Hearing loss	1	2.2
Total	43	100.0

may be due to a possible change in the ballistics of the weapons used as a result of transition from CGSWs mostly seen from armed robbery to those resulting from terrorist activities. Insurgents may have access to heavy-caliber, military-type weaponry, speculatively from subregional conflicts and peace-keeping missions in Africa which gain entry into the country through various means.[3,4]

A comparative analysis of subregional prevalence of CGSWs in Nigeria has shown that etiology varies depending on the socioeconomic, ethnopolitical, and religious indices. In Western Nigeria, Ugboko et al[3] reported a predominance of low-energy (LE) CGSWs arising from accidental discharges. Armed robbery attack was the prevailing cause in Eastern and Southern Nigeria.[4,13] Young male adults are frequently the victims of CGSWs via armed robbery attack, as they constitute the economically productive age group.[1] Kaufman et al[11] opined that male patients were more often involved in ballistic violence, be it accidental, self-inflicted, suicide, combat, or assault. This was also corroborated by other authors within the country,[1–4,13] the United States,[7,10,11] and other regions.[6,8,14] The strength of this observation is buttressed by a cultural norm of keeping women indoors in Northern Nigeria.[1]

The severity of firearm-related injuries is determined by ballistics.[6,7] This is divided into internal (projectile/propellant interaction), external (influencing flight path, e.g., wind), and terminal ballistics (effect on tissues).[6] While it was difficult to identify firearm types in this study, the radiological identification of projectile type and comparison with resultant injury pattern[6,7] suggested injury classification into the nonavulsive LE injury and avulsive HE injury types.

Nonavulsive LE injury types had small entry wounds with minimal bone destruction and soft-tissue contusions. They are the result of injuries sustained from low-velocity firearms (velocity $<$1,200 ft/s).[7] Avulsive HE injury types were characterized by osseous comminution with extensive hard- and soft-tissue avulsions. They had small entry points with large cavitating exit wounds with no radiological evidence of the missile,[7] probably from the *Avtomat Kalashnikova 1947* (AK-47) assault rifle,[15,16] being the most common weapon among insurgents.[16] This weapon[15,16] is common among soldiers and terrorists all over the world because it is simple to handle, cheap, lightweight, and readily available, with an estimated 60 to 70 million AK-47 rifles globally.[17] It fires 7.62 $\times$ 39 mm, 125 grain rounds with a very destructive muzzle velocity of approximately 2,330 ft/s.[17]

The equation $E = 1/2(\text{mass} \times \text{velocity}^2$, where E = energy) suggests that the destructive energy quadruples when the velocity doubles. Thus, the greater distribution of injuries and multisystemic involvement which characterized HE injuries is related to this large energy dissipated on impact. It is a combined consequence of pressure wave and energized secondary fragments[6,7] as compared with nonavulsive LE injuries. The later had pellets or single bullets (9 mm) associated with simple undisplaced basal bone fractures, crushed dentoalveolar segments, and soft-tissue wounds without exits.

Tracheostomy utilization for CGSWs in our study was lower than that of the findings of Hollier et al[10] and Motamedi[9] who reported 21 and 9%, respectively. This may be because of their larger sample size[10] and more frequent involvement of intracranial injuries in both studies.[9,10] Moreover, the latter[9] included battlefield injuries with greater tissue disruption and less optimal care in a poorly controlled combat environment. The post-admission mortalities (11 and 2.2%, respectively) reported by both studies may be due to the stated reasons, particularly intracranial involvement.[7,17,18] Prevalence of difficult posttraumatic hemorrhage in our study was low (one patient) probably because the neck[9,19] was not involved in our patients and such patients might have died before presentation, thereby being excluded from our data. Control of posttraumatic hemorrhage related to CGSWs can be achieved by ligation of the external carotid artery and pressure.[11,19] The benefits of computed tomographic scan (CT) in assessing CGSWs include better visualization of spatial relationships of bone fragments in HE wounds; clearer assessment of continuity defects in its entirety;[6,11,19] and localization of projectile fragments, through visualization of gunpowder residues.[6] Orbital and cranial involvement was also better appreciated.[9] However, due to the resource limitation, it is impracticable to make CT scan mandatory for all cases in our center and thus requests are made only where it would influence treatment (►**Fig. 2a–d**)

Contemporary paradigm suggests that the first major surgery should be performed with the intent to definitively manage all aspects of the injuries within 48 hours[10,11,19,20] (primary treatment). Our experience has shown that wound contamination, secondary infection, and poor clinical status often compromise early reconstruction attempts in our environment. We have thus adopted the delayed approach to management of CGSWs. Reduction of posttraumatic edema, reduced infection rates, and less necrotic debris have been highlighted as some of the benefits of delayed reconstruction.[21]

Vásconez et al,[21] however, observed no significant difference in infection rates between both groups, stating that delayed reconstruction resulted in debilitating wound contracture, evidenced *by* limitation of mouth opening which often made prosthetic rehabilitation difficult.[19] Furthermore, immediate reconstruction reduces local dead space,



Fig. 2 (**a**) High-energy craniomaxillofacial gunshot wound (HE CGSW) showing severe edema and avulsed soft tissues (**b**) 3D CT showing severely comminuted mandible and fractured maxilla. (**c**) Same patient after composite reconstruction using bone grafts anchored to mandibular reconstruction plate. A *bandoneon* flap was used to repair the soft-tissue defect. (**d**) Postoperative 3D CT following mandibular reconstruction.

thus enhancing tissue immunoreactivity, robust biologic coverage, and expediting wound healing through better access to hematogenous nutrients.[22,23] These benefits suggest that patients who had immediate reconstruction experience better healing and have fewer and less complex surgical revisions than the delayed reconstruction group.[9,11]

The iliac crest is a suitable choice for nonvascularized graft to restore bony continuity especially in the mandible because of its dimensional similarity to natural mandible and ease of harvest.[11,20] Our choice of stainless steel–based fixation devices over the titanium-based equivalent is secondary to the high cost of the latter, despite its obvious benefits of greater biocompatibility and malleability. The use of pedicled deltopectoral, sternomastoid, submental, Abbe, forehead, *bandoneon*, and other local advancement soft-tissue flaps for soft-tissue reconstruction is based on their ready availability and their pedigree as reliable alternatives to microvascular tissue transfers.[24] These locoregional flaps[24] with good technique are highly vascular, easy to develop, provide good color match, and hardly fail. The donor-site morbidity is often acceptable to the patient who has been properly consented prior to the procedure and is often skin grafted[24] (►**Fig. 3d**). ►**Fig. 3(a–c)** demonstrates a GSW patient with composite alveolo-palatal defect who had soft-tissue reconstruction with pedicled forehead flap. An interim clasped hollow box obturator was later used to reconstruct the anterior maxillary defect pending bone grafting.

The use of delayed approach to management frequently prolongs hospital stay as seen in our study. This is in addition to reduction in ridge height and loss of sulcular depth that is often associated with our bone replacement technique, as some patients found denture wearing difficult. Hospital stay may be further lengthened in those patients requiring pedicled flaps for soft-tissue reconstruction. Vascularized grafts using microvascular techniques would be a preferable approach where available. Unfortunately, the armamentarium and required expertise are currently not available in our center.



Fig. 3 (**a**) High-energy craniomaxillofacial gunshot wound (HE GSW) with loss of upper lip and anterior alveolo-palatal segment in a male patient. (**b**) Preoperative CT of the same patient showing a configurational defect of the anterior maxilla. (**c**) Forehead flap with axial folding during the process of flap "take." (**d**) Flap insetting after 21 days with split thickness skin grafting of donor site.

Conclusion

There has been a significant increase in incidence and extent of tissue destruction in craniomaxillofacial gunshot injuries which were hitherto uncommon in our environment, with some post-management deficits. There is therefore a great need to review our management protocol to accommodate this change in trend and severity for better treatment outcomes. Microvascular technique, osteointegrated implant services, and techniques of alveolar distraction will be highly useful additions in increasing patients' quality of life following management.

Ethical Approval
Not required.

Conflict of Interest
None.

Acknowledgment
The authors acknowledge Corporal Danlami Shuaibu of the Nigerian Police Armory division for his contribution on descriptive ballistics. This article is dedicated to the memory of Professor Emmanuel Oladepo Adekeye, Professor of Oral and Maxillofacial Surgery, April 4, 1938–March 13, 2015.

References

1 Mohammed AZ, Edino ST, Ochicha O, Umar AB. Epidemiology of gunshot injuries in Kano Nigeria. Nig J Surg Res 2005;7(4):296–299
2 Saheeb BDO, Adeola DS. Cranio-maxillofacial gunshot injuries sustained in religious and ethnic riots in Nigeria. African J Trauma 2004;2:88–91
3 Ugboko VI, Owotade FJ, Oginni FO, Odusanya SA. Gunshot injuries of the orofacial region in Nigerian civilians. SADJ 1999;54(9):418–422
4 Iloh GP, Chuku A, Ofoedu JN, Ugwele OH, Onyekwere JO, Amadi AN. The emerging trend in the epidemiology of gunshot injuries in the emergency department of a Nigerian tertiary hospital in a state without formal pre-hospital emergency medical services. Ann Tropical Med Public Health 2013;6:435–440

5 Nyako M. Is The Massive Killing (By So-Called Boko Haram) State Sponsored? Paper presented at: Symposium on Current Economic, Social and Security Challenges Facing Northern Nigeria; March, 2014; United States Institute of Peace (USIP), Washington, DC
6 Stuehmer C, Blum KS, Kokemueller H, et al. Influence of different types of guns, projectiles, and propellants on patterns of injury to the viscerocranium. J Oral Maxillofac Surg 2009;67(4):775–781
7 Johnson J, Markiewicz MR, Bell RB, Potter BE, Dierks EJ. Gun orientation in self-inflicted craniomaxillofacial gunshot wounds: risk factors associated with fatality. Int J Oral Maxillofac Surg 2012;41(8):895–901
8 Motamedi MH. Primary treatment of penetrating injuries to the face. J Oral Maxillofac Surg 2007;65(6):1215–1218
9 Motamedi MH. Primary management of maxillofacial hard and soft tissue gunshot and shrapnel injuries. J Oral Maxillofac Surg 2003;61(12):1390–1398
10 Hollier L, Grantcharova EP, Kattash M. Facial gunshot wounds: a 4-year experience. J Oral Maxillofac Surg 2001;59(3):277–282
11 Kaufman Y, Cole P, Hollier LH Jr. Facial gunshot wounds: trends in management. Craniomaxillofac Trauma Reconstr 2009;2(2):85–90
12 Onuoha FC. (Un) Willing to Die: Boko Haram and suicide terrorism in Nigeria. Report, Al Jazeera Centre for Studies. December 24, 2012. Available at: http://studies.aljazeera.net/en/report/2012/12/201212249141659533 7.htm. Accessed January 10, 2013
13 Bassey GO, Anyanechi CE, Chukwuneke FN. Civilian gunshot injuries to the oro-facial region in Calabar, south-south Nigeria, 2002-2006. Niger J Med 2008;17(3):257–260
14 Long V, Lo LJ, Chen YR. Facial reconstruction after a complicated gunshot injury. Chang Gung Med J 2002;25(8):557–562
15 Haney EL, Thomsen BM. Beyond Shock and Awe: Warfare in the 21st Century. Penguin; 2007
16 Sprague O, Griffiths H. The AK-47: The world's favourite killing machine. Amnesty International [online]. 2006;1:1–18. Available at: http://www.controlarms.org. Accessed June 26, 2006
17 Shuker ST, Sadda R. Craniomaxillofacial falling bullet injuries and management. J Oral Maxillofac Surg 2010;68(7):1593–1601
18 Kummoona R. Management of missiles injuries of the facial skeleton: primary, intermediate, and secondary phases. J Craniofac Surg 2010;21(4):976–981
19 Dean NR, McKinney SM, Wax MK, Louis PJ, Rosenthal EL. Free flap reconstruction of self-inflicted submental gunshot wounds. Craniomaxillofac Trauma Reconstr 2011;4(1):25–34
20 Motamedi MHK, Ebrahimi A, Shams A. Current trends in the management of maxillofacial gunshot injuries: a critical review. Ann Oral Maxillofac Surg 2013;1(1):1–6
21 Vásconez HC, Shockley ME, Luce EA. High-energy gunshot wounds to the face. Ann Plast Surg 1996;36(1):18–25
22 Vayvada H, Menderes A, Yilmaz M, Mola F, Kzlkaya A, Atabey A. Management of close range/high energy shotguns and rifle wounds to the face. J Craniofac Surg 2005;16(5):794–804
23 Gruss JS, Antonyshyn O, Phillips JH. Early definitive bone and soft-tissue reconstruction of major gunshot wounds of the face. Plast Reconstr Surg 1991;87(3):436–450
24 Motamedi MH, Behnia H. Experience with regional flaps in the comprehensive treatment of maxillofacial soft-tissue injuries in war victims. J Craniomaxillofac Surg 1999;27(4): 256–265