Syme's Amputation

Surgical Technique, Prosthetic Considerations, and Case Reports

Justin R. Hudson, DPM*
Gerard V. Yu, DPM†
Roger Marzano, CPO, CPed‡
Andrew L. Vincent, DPM§

Amputation at the level of the ankle joint is a valuable but underused procedure for a variety of conditions affecting the foot and ankle. The procedure provides a comfortable and durable stump that allows the lower-extremity amputee to function with minimal disability. This article reviews the indications for Syme's amputation, provides a detailed surgical description of the procedure, and discusses postoperative prosthetic considerations. In addition, three case reports are presented in which Syme's procedure was successfully used as an alternative to higher-level amputation. (J Am Podiatr Med Assoc 92(4): 232-246, 2002)

In his original article describing amputation at the level of the ankle joint in 1843, James Syme laments the number of limbs that he had previously cut off that might have been saved with an alternative procedure.[1] Undoubtedly, this is a feeling shared by many foot and ankle surgeons whose own patients have progressed to either below-the-knee or above-the-knee amputation for conditions that were not amenable to either forefoot or midfoot amputations. At the time of its introduction, Syme's amputation was viewed as a major technical advance. The procedure was developed in the era before the advent of antiseptics and anesthesia, and one of Syme's major goals was to develop a safer and more reliable procedure than traditional below-the-knee amputation, which at that time had a mortality rate of between 25% and 50%.[2] Syme believed that compared with below-the-knee amputation, ankle amputation afforded a smaller risk to life, a more comfortable stump, and a more useful limb for support and progressive motion.[1]

Today, more than 150 years after the introduction of Syme's amputation, risk of death from sepsis or hemorrhage after below-the-knee amputation is virtually nil, making it a safe procedure in the absence of comorbid conditions in the patient who is undergoing lower-extremity amputation. Accordingly, a strong contention cannot be made that ankle amputation is today a safer alternative than below-the-knee amputation. However, it can be argued that ankle amputation provides a more useful and durable stump that allows the amputee to function with little or no disability. Periodic case reports in the literature have affirmed the long-term durability of this level of amputation, with patients enjoying more than 40 years of success with the stump.[3,4] Today, the main advantage of Syme's procedure is that it provides a fully weightbearing stump that is nearly as long as the contralateral limb, giving the amputee near-normal functional ability.

Despite these well-recognized advantages of Syme's amputation, it has tended to be underused, with the

*Submitted during third-year residency, St Vincent Charity Hospital, 2351 E 22nd St, Room 312-C, Cleveland, OH 44115.

†Diplomate, American Board of Podiatric Surgery; Fellow, American College of Foot and Ankle Surgeons; Director of Podiatric Medical Education and Residency Training, St Vincent Charity Hospital, Cleveland, OH; Faculty Member, The Podiatry Institute, Tucker, GA.

‡Certified Prosthetist/Orthotist, American Board for Certification in Orthotics and Prosthetics; Certified Pedorthist, Board for Certification in Pedorthics; Vice President of Clinical Services, Yanke Bionics, Akron, OH.

§Submitted during second-year residency, St Vincent Charity Hospital, Cleveland, OH.

procedure enjoying widespread popularity only in Canada and Scotland.[2, 5] The reasons for underuse of the procedure are many. Perhaps there is a perception that wound healing is routinely difficult and prolonged or that the residual stump is prone to ulceration or difficult to fit with a prosthesis. Perhaps it is the result of "tradition," with the established mindset being that after midfoot amputation, below-the-knee amputation is the next choice. The truth is that this procedure is often avoided because many foot and ankle surgeons have been indoctrinated with the notion that the procedure simply "does not work." Consequently, most recently trained foot and ankle surgeons, whether orthopedic or podiatric, receive little if any training in Syme's amputation.

The authors believe that many of the concerns regarding this procedure are misperceptions. The senior author (G.V.Y.) has successfully used this procedure for a variety of foot and ankle conditions that would have traditionally required higher-level amputation. The aims of this article are to review the indications for Syme's amputation and to provide a detailed description of the surgical procedure and postoperative prosthetic management.

Surgical Considerations

Syme's amputation is indicated in patients with a myriad of foot and ankle conditions, including congenital deformities, trauma or crush injury, soft-tissue and osseous sarcomas of the foot, nonsalvageable Charcot processes, ischemia, frostbite, nonhealing ulcerations, osteomyelitis, and fetid foot. Contraindications to performing Syme's procedure include inadequate blood flow to the ankle and rearfoot, infection or open lesions of the heel pad, ascending cellulitis or lymphangitis, severe immunocompromise or malnutrition, and a lack of potential for the amputee to become a community ambulator after the procedure.[6-8] Healing of the amputation has traditionally not been problematic in patients undergoing the procedure for reasons other than severe peripheral vascular disease and diabetes-related manifestations. However, in cases in which the procedure is being performed because of these entities, it is important to confirm the patient's healing capacity for this level of amputation; requirements for wound healing have been outlined by Wagner[9] and later modified by Dickhaut et al[10] and Pinzur et al.[11, 12]

Wound-healing parameters are designed to predict whether the patient has the immunocompetence, nutritional status, and arterial inflow to heal the amputation. Immunocompetence is predicted by a total lymphocyte count greater than 1.5×10^9/L. A serum albumin level greater than 30 g/L is required to ensure a minimum level of tissue nutrition. Adequate blood flow for healing is indicated by an ankle-brachial index greater than 0.5 or a transcutaneous oxygen concentration of at least 30 mm Hg at the level of the amputation site. Last, optimization of the blood glucose level (<13.9 mmol/L [<250 mg/dL]) should be achieved and maintained throughout the perioperative period.

Syme's amputation can be performed as either a one-stage or a two-stage procedure. In 1954, Spittler et al[13] described a two-stage approach to Syme's amputation that was performed for infected war wounds. In the first stage, the ankle joint was disarticulated and "closure without tension" was performed. The second stage was performed 6 to 8 weeks later, at which time the malleoli were removed through medial and lateral elliptical incisions and the wounds were closed. The rationale behind the two-stage procedure was to decrease the chance for infection after the procedure.

Wagner[9] was a proponent of the two-stage procedure in cases of severe diabetic foot infection. He reported close to a 95% success rate with the two-stage procedure when it was performed in patients who met the following clinical indications: positive potential for prosthetic use, heel pad free of open lesions, absence of pus at the amputation site, no ascending lymphangitis, and an ankle-brachial index greater than 0.45. Pinzur et al[14] evaluated the success of the two-stage procedure performed in diabetic patients with forefoot gangrene and nonreconstructible peripheral vascular insufficiency. The results of the study revealed that 31 of 38 amputations eventually healed and were fit with a prosthesis. Twenty-seven of the patients (71%) eventually returned to their preamputation level of ambulatory function.

In a later study, Pinzur et al[15] compared the results of the one-stage *versus* the two-stage Syme procedure in patients undergoing amputation for gangrene or nonsalvageable diabetic foot infections. The study was terminated early when it became evident that the results from both procedures seemed to be similar. The authors concluded that the two-stage procedure subjected these high-cardiac-risk patients to a second hospitalization, anesthetic, and surgery and resulted in higher overall health-care costs. In that study, a total of 44 one-stage and two-stage procedures were performed, with 31 of the amputations (70%) progressing to wound healing and prosthesis fitting.

Whereas the two-stage procedure is useful in cases of aggressive soft-tissue infection, the one-stage procedure is more commonly used today. Typically, the one-stage procedure uses a fish-mouth incision about

the ankle joint that preserves the plantar fat pad and allows for the disarticulation of the ankle joint and resection of the malleoli. One of the most important criteria for performing this procedure is the presence of a viable plantar fat pad of the heel, as this will be the ultimate weightbearing interface between the tibia and fibula and the prosthetic device.

The plantar fat pad is composed of a meshwork of fat that is enclosed within fibroelastic septae arranged in a closed-cell configuration.[16] It is this unique anatomical configuration that allows the plantar fat pad to function as a shock-absorbing structure during ambulation. Given its importance in pain-free weightbearing, every effort must be made to maintain the structural integrity of the plantar fat pad during Syme's procedure. This is best accomplished by using subperiosteal dissection when removing the calcaneus. Various modifications to the standard incisional approach have been described, including an anterior ankle flap for use in patients in whom it is not possible to use the heel as a flap.[17] Although the anterior flap may provide adequate soft-tissue coverage for an ankle amputation in which the heel pad is nonviable, it must be remembered that the anterior flap does not contain the same shock-absorbing qualities as the plantar fat pad and may result in an uncomfortable stump, thereby eliminating a favorable aspect of Syme's amputation.

The first several weeks after Syme's amputation are critical; it is during this time that the wound is most at risk for dehiscence or sloughing. Hematoma and seroma formation are common occurrences and must be managed appropriately. Meticulous hemostasis and use of a surgical drain will help minimize this occurrence. In addition, wound-healing complications can be lessened by using an atraumatic surgical technique. Inadvertent transection of the posterior tibial artery proximal to the distal aspect of the plantar flap may also compromise healing in the first few days after the procedure. However, provided that vascularity is maintained in the flap, predictable stability of the wound is typical after healing of the initial incision site.

Late complications may also occur, including mobility or improper location of the plantar fat pad, stump sensitivity, neuroma formation, and phantom pain; these complications are not, however, unique to this type of amputation but are associated with amputations in general.

Surgical Technique

The surgical procedure is performed with the patient in the supine position. A calf or thigh pneumatic tourniquet may be used if no contraindications are present. A modified fish-mouth incision that preserves the plantar fat pad is outlined about the ankle joint. The key landmarks for creating this flap are the inferior aspects of the malleoli (Fig. 1). A point 1 cm inferior and 1 cm anterior to the tip of the lateral malleolus is marked. Next, a point 1.5 cm inferior and 1 cm anterior to the tip of the medial malleolus is marked. These points are then connected with a line drawn crossing the anterior aspect of the ankle; it is important that the incision is not proximal to the distal aspect of the tibia. The plantar incision is oriented approximately 90° from the dorsal incision and drawn out across the plantar aspect of the foot extending from the two points below the malleoli. The plantar incision should be carried out to the level of the calcaneocuboid joint to ensure adequate length of the plantar flap. When designing this flap, it is better to err in the direction of being too long, because it can always be modified before skin closure. Proper planning of the skin incision cannot be overemphasized.

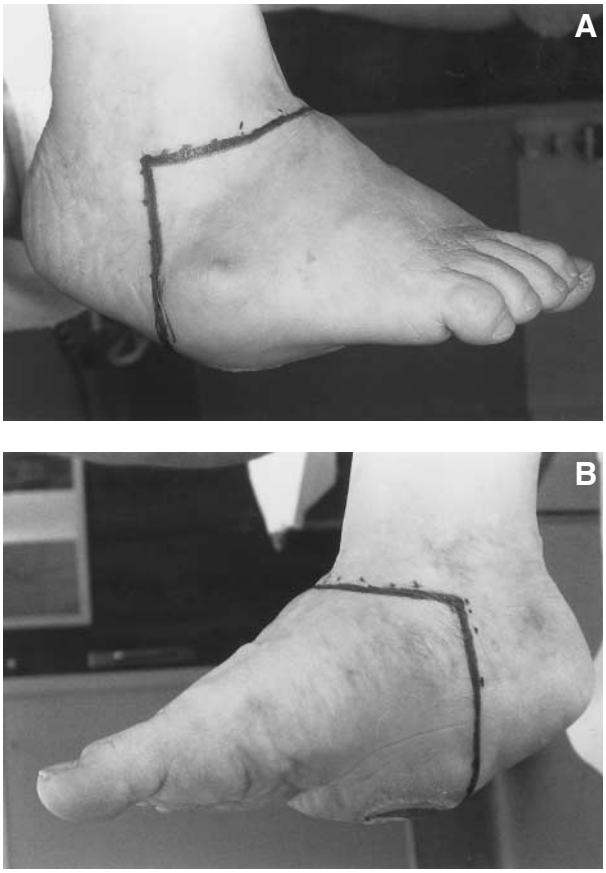

Figure 1. Lateral (A) and medial (B) views of the incision placement for Syme's amputation.

Visualization of the final desired product is a prerequisite for success.

Although the skin incisions can be made directly to bone, the authors prefer to make a controlled-depth incision. With this approach, improved hemostasis and anatomical dissection are achieved. The anterior incision is performed first. No undermining of the incision is performed. Dissection is carried down through the subcutaneous tissue to the level of the deep fascia. Superficial nerves crossing the anterior ankle joint (the saphenous, medial, and intermediate dorsal cutaneous nerves) are identified, sharply transected, and allowed to migrate proximally. All superficial veins are ligated or bovied as necessary. The deep fascia is incised, and the anterior tendons crossing the ankle joint are identified, clamped, pulled distally, sharply transected, and allowed to migrate proximally; these tendons include the tibialis anterior, the extensor hallucis longus, the extensor digitorum longus, and, if present, the peroneus tertius (Fig. 2). The anterior tibial artery is identified and ligated. The deep peroneal nerve is cut under traction and allowed to migrate proximally as well. The anterior ankle joint capsule is now exposed.

The plantar incision is developed next. Again, use of a controlled-depth incision without undermining is recommended. The incision is deepened through the subcutaneous tissues of the plantar foot. On the lateral aspect, the peroneal tendons are identified, placed under traction, severed, and allowed to retract proximally. The lateral dorsal cutaneous nerve is cut under traction and allowed to retract proximally, as is the lesser saphenous vein after ligation. Dissection of the plantar flap is complete at this point once the plantar fascia is visualized (Fig. 3). There should be no dissection along the plane of the plantar fascia.

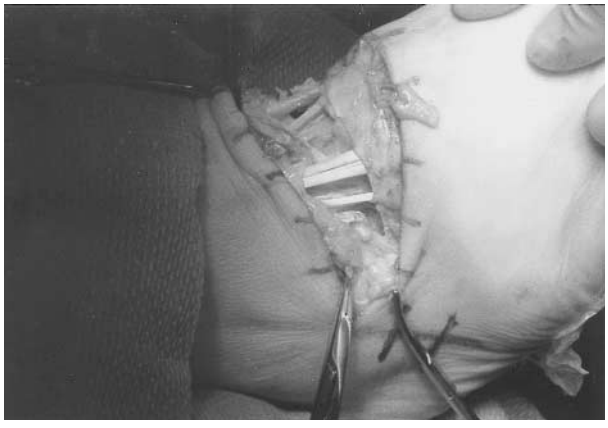

Figure 2. Partially developed superior incision demonstrating the tendons crossing the anterior ankle joint.

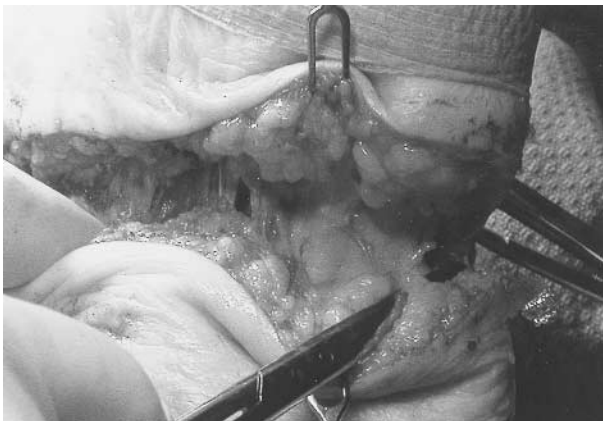

Figure 3. Partially developed inferior incision demonstrating the plantar fascia.

Attention is then redirected to the anterior aspect of the ankle joint, and the capsule is incised. The dome of the talus is now visualized. Transecting the medial and lateral ankle ligaments from the talus allows disarticulation of the ankle joint. Great care must be taken when transecting the medial collateral ligaments to avoid inadvertent transection of the posterior tibial artery, veins, and nerve that lie in close proximity. Preservation of the artery at its maximal length is imperative because it is the sole blood supply to the plantar flap. The long flexor tendons and the posterior tibial tendon are isolated, placed under distal traction, transected, and allowed to migrate proximally. At this point, blunt dissection of the posterior tibial neurovascular bundle should be performed to isolate this structure in the posterior flap. The posterior tibial artery should be traced as far distally as possible and ligated. Next, the posterior tibial nerve is cut under tension and allowed to migrate proximally.

The foot is then plantarflexed, and the posterior ankle joint capsule and periarticular structures are transected. Placing a bone hook into the posterior aspect of the talus and applying distal traction facilitates exposure of the posterior aspect of the ankle joint (Fig. 4). The insertion of the Achilles tendon is identified and released from the calcaneus. It is important to remember that there is little subcutaneous tissue between the Achilles tendon and the posterior skin. Accordingly, the authors encourage use of a meticulous, sharp dissection technique in this area to prevent buttonholing. A Crego periosteal elevator may be a safer and more useful instrument for free-

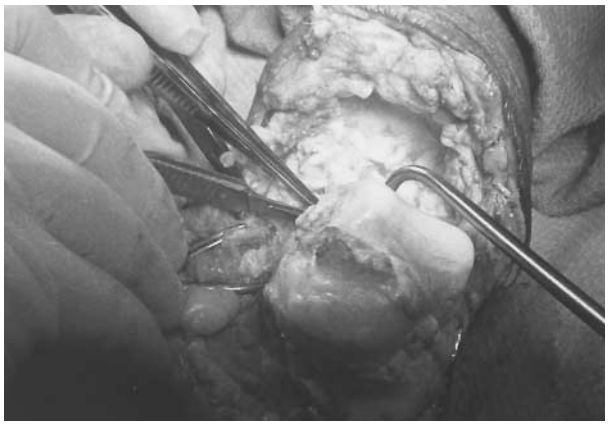

Figure 4. Exposure of the posterior ankle joint is facilitated by placing a bone hook in the posterior aspect of the talus and applying distal traction.



Figure 5. Placement of large, threaded Steinmann pins into the talus and calcaneus after disarticulation of the midtarsal joint.

ing the insertion of the Achilles tendon. After transection of the tendon, further plantarflexion of the foot allows subperiosteal dissection of the posterior, medial, lateral, and plantar surfaces of the calcaneus from its underlying soft-tissue attachments. At this point, the remaining insertions of the plantar fascia and intrinsic musculature to the calcaneus are transected, and the amputated foot is removed from the operative field.

Occasionally, the authors have found it advantageous to disarticulate the foot at Chopart's joint before removing the talus and calcaneus from the ankle joint. After removal of the distal foot, large, threaded Steinmann pins are driven into the head of the talus and the distal articular surface of the calcaneus. These pins are then used as "joysticks" to facilitate subperiosteal dissection of the calcaneus (Fig. 5).

Once the entire foot has been removed, attention is directed toward resection of the tibia and fibula. The articular cartilage of the distal tibia may be retained or resected. Removal of the articular cartilage from the distal tibia may allow for better adherence of the plantar fat pad postoperatively. However, in cases of severe infection in which spread to the tibia is of concern, the cartilage at the distal end of the tibia may be left intact to serve as a physical barrier to the spread of bacteria. Resection is accomplished with a large power saw placed perpendicular to the long axis of the tibia and fibula. The bone cuts are made parallel to the ground-supporting surface. Care is taken to preserve as much of the distal tibia as possible to maintain a large weightbearing surface area. Further remodeling of the distal end of the tibia and fibula is required to square off the osseous component of the stump. The medial and lateral malleoli are resected at a 45° to 60° angle from the long axis of their respective bones, creating a narrow distal stump that facilitates an optimal fit of the prosthesis (Fig. 6).

Before closure, drill holes are made in either the distal anterior or the distal posterior aspect of the tibia, and the Achilles tendon and other remaining deep soft tissues are secured with nonabsorbable sutures. Tenodesis of the Achilles tendon to the tibia is an effective method of decreasing mobility and maintaining the position of the fat pad at the end of the osseous stump.[18]

If a tourniquet is used, it is deflated at this time, and additional hemostasis is achieved as necessary; whereas smaller vessels respond well to electrocoagulation, larger-lumen vessels should be ligated. A large-lumen closed-suction drain is introduced through a separate stab incision and is placed in the area of the former ankle joint. The deep fascia and residual collateral ligamentous tissues are reapproximated over the remaining bone using the absorbable synthetic suture of choice (Fig. 7).

At this time, the plantar flap is advanced, and debulking of the residual intrinsic musculature is performed as necessary. The subcutaneous tissues are reapproximated, and the skin is closed using either simple interrupted 3-0 synthetic monofilament nonabsorbable sutures of choice or, if preferred, skin staples (Fig. 8). It is not uncommon for "dog-ears" to be present on the medial and lateral aspects of the incision; remodeling of dog-ears is possible, but it must be done with caution, as it may compromise circulation to the plantar flap. Instead, it is commonplace to allow these dog-ears to simply remodel with time of their own accord or to return to the operating room

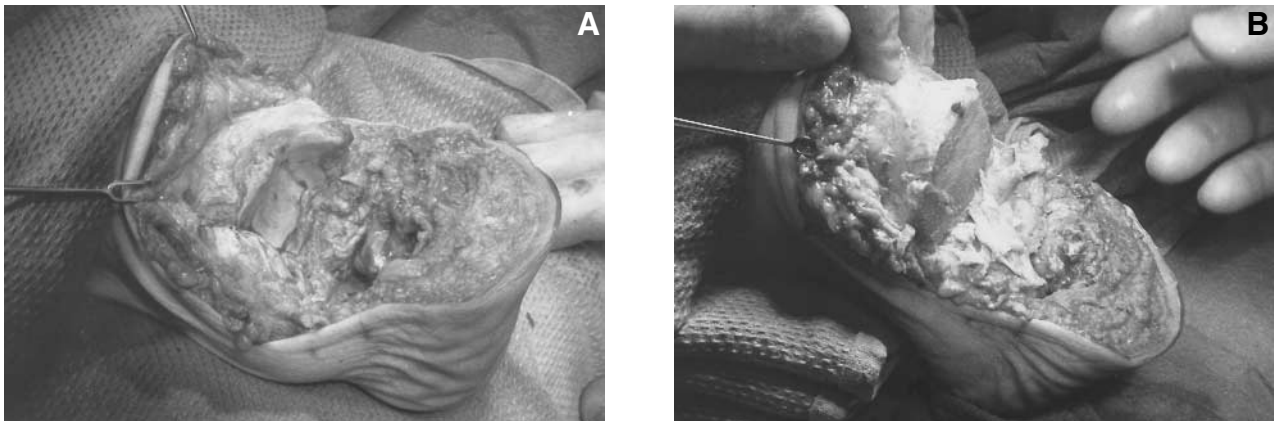

Figure 6. Appearance of the distal tibia and fibula before (A) and after (B) osseous resection.



Figure 7. Closure of the residual deep tissues over the distal tibia and fibula.

for scar revision if needed. Pinzur[19] suggested that the creation of dog-ears may be avoided by placing the apex of the incision just anterior and inferior to the midpoint of the medial and lateral malleoli. The current authors have not found dog-ears to be a significant problem.

Initially, the wound is dressed in a well-molded modified Jones compression bandage to minimize edema and hematoma or seroma formation; this dressing will also help "contour" the stump as the tissues shrink and adapt (Fig. 9). The patient is maintained nonweightbearing for 3 to 6 weeks, until the wound has completely healed; sutures are generally removed approximately 2 to 4 weeks postoperatively. The patient is then placed in a short-leg cast, and weightbearing as tolerated is permitted. The cast is changed at 2- to 3-week intervals until resolution of

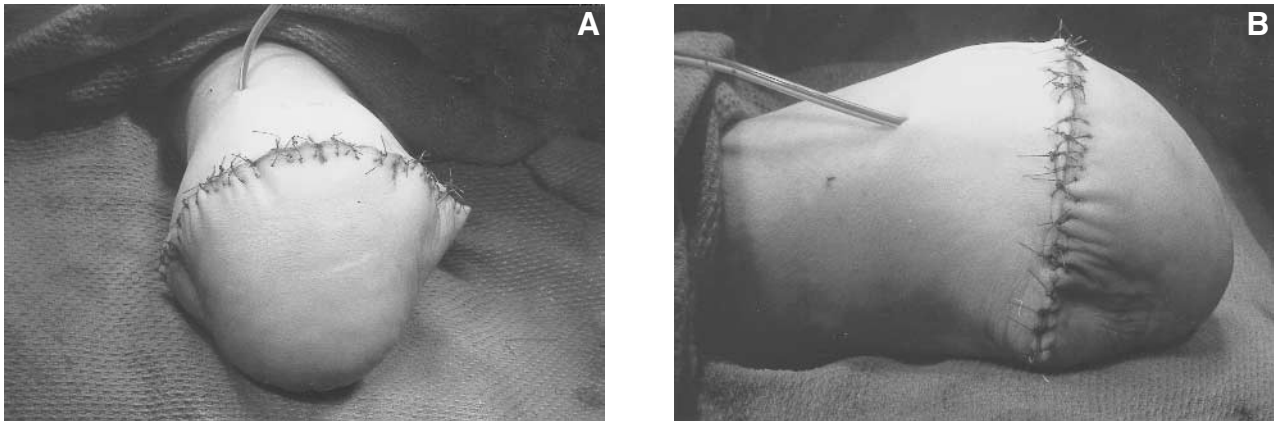

Figure 8 A and B. Appearance of the stump on completion of Syme's amputation.

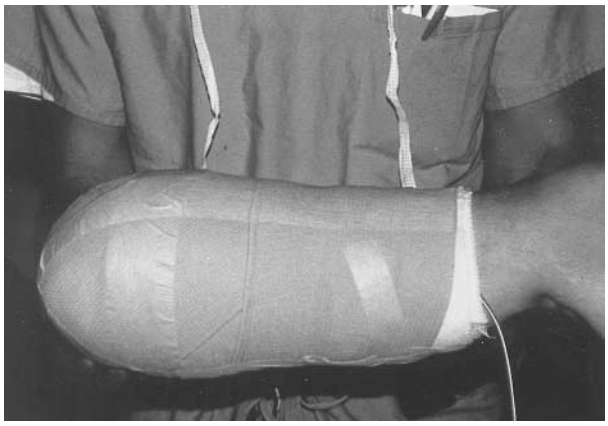

Figure 9. A modified Jones compression dressing is used postoperatively to control edema and to help shape the stump.

all soft-tissue edema and stump shrinkage has occurred. At approximately 5 to 9 weeks, the stump has stabilized and the patient is referred to a prosthetist for fabrication of a preparatory prosthetic device. The preparatory device is used for 3 to 9 months or until shaping and volumetric stabilization of the stump have occurred.[20] At that time, the patient is ready for fabrication of a permanent prosthetic device.

Physical therapy with the prosthesis in place is used as necessary. In general, it has been the authors' experience that only minimal gait training is required, mainly because of the length of the limb that is maintained. However, it is also partly because the heel pad has been preserved, with some maintenance of normal proprioceptive pathways. Short periods of ambulation without the prosthesis are possible, such as getting up to go to the bathroom in the middle of the night.

Prosthetic Considerations

Prosthetic management of the Syme's-level amputee must encompass several objectives. The prosthesis should compensate for the loss of foot and ankle motion while providing the propulsive energy required for ambulation. It is also necessary to compensate for the discrepancy in limb length created by this level of amputation and to suspend the prosthesis adequately during the swing phase of gait. In addition, it is necessary to create an intimately fit socket that will help maintain the fat pad beneath the distal end of the tibia and fibula. This level of amputation has many functional advantages, but it also has some prosthetic component limitations as well as cosmetic limitations due to the nature and shape of the residual limb being managed.

Biomechanically, the prosthesis must be aligned to enhance gait while at the same time minimizing shear and providing a comfortable transition of forces to the residual limb. The prosthetist will work to align the prosthetic foot as far posterior as cosmetically acceptable and in slight dorsiflexion to minimize knee extension forces from the midstance to the toe-off phases of gait. In the coronal plane, the foot is placed lateral to the midline of the limb to provide mediolateral stability. Slight eversion allows the foot to be flat on the ground at midstance. In the transverse plane, the foot is generally externally rotated as much as cosmetically acceptable to minimize knee-extension forces at toe-off and to provide mediolateral stability by widening the base of support.[21]

There are four basic designs of prostheses that are currently used in managing the Syme's-level amputee. The posterior door design, also known as the Canadian design, is more commonly used on individuals with large or bulbous residual limbs, and it is frequently used with Chopart's amputations as well. This design is used least often, as it is the least cosmetic option and has a heavier weight as a result of the construction parameters used.[22]

The most frequently used design is the medial opening or medial door design (Fig. 10). This design has great suspension characteristics due to the intimate nature of the socket construction. An elastic sleeve placed over the door improves cosmesis and facilitates the donning and doffing process by allowing the door to expand.[23]

Another design uses an expandable inner liner enclosed within the rigid outer shell. This design allows for the distal end of the stump to pass through the expandable bladder portion. This hidden-panel expandable wall design is indicated for individuals with small distal ends and is considered the most cosmetic of all designs.[24]

The fourth design often used for the preparatory prosthesis uses a removable foam liner that interfaces with the external socket. This offers the prosthetist the ability to modify the insert to allow for the atrophy that takes place in the limb during the maturation process. This design offers great cosmesis, is lightweight, and is highly adjustable. The preparatory Syme's prosthesis uses the patellar tendon to assist with unloading the limb during the maturation process. As the amputee progresses and the limb matures, the proximal trim lines of most definitive Syme's prosthetic devices are trimmed to the level of, or below, the patellar tendon. The medial flare of the tibia, the lateral pretibial region, and the long lat-



Figure 10. Medial door Syme's amputation prosthesis.

eral fibular region are the more predominantly weight-bearing or loading regions within a Syme's prosthesis socket. Offloading the amputee's weight from the stump to the aforementioned regions and a significant degree of hydrostatic compression using the entire calf are the primary principles used in manufacturing Syme's prostheses.

Owing to the length of the residual limb, prosthetic management has limitations in the number of prosthetic feet available (Fig. 11). Traditionally, standard solid ankle cushion heel feet were used in preparatory Syme's prostheses because weight and biomechanical objectives are well served with this foot. Geriatric and low-level walkers are still well served with this foot construction. Recently, there has been a resurgence in the development of energy-storing or dynamic feet for Syme's prostheses, which offer decreased weight and enhanced performance for the amputee. These feet best serve those amputees who will challenge the limits of prosthetic use.

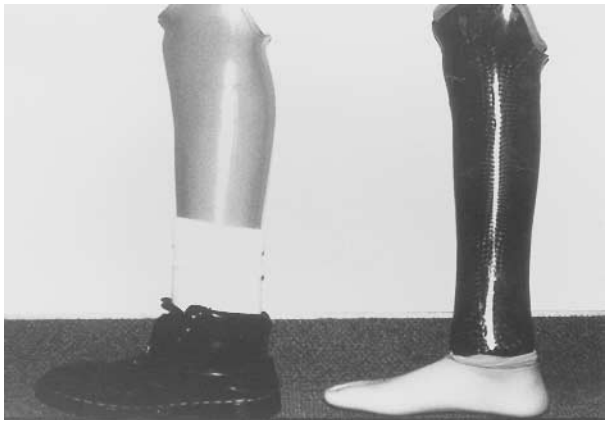

Figure 11. Syme's amputation prosthesis with attached prosthetic foot.

From a prosthetic management perspective, it is the opinion of the authors that the advantages of Syme's-level amputation far outweigh any of its disadvantages. Advantages include decreased energy expenditure, more normal gait, and increased residual limb surface area to transfer and absorb socket pressures[25]; the disadvantages of the cosmetic appearance of the prosthesis and migration of the heel pad in some individuals are minor by comparison.[26]

Syme's-level amputations are a viable, highly successful level of amputation to consider for individuals who meet the preoperative indications outlined in this article. Surgeons would be well advised to seek the opinion of a prosthetist, preferably preoperatively, to establish a prosthetic opinion and to help the future amputee feel more comfortable with the procedure being considered. It is advisable to have the patient see and feel a prosthesis or, better yet, talk to an experienced Syme's-level amputee before moving forward. The surgeon–prosthetist relationship can enhance outcomes by combining the talents of both while also increasing the confidence and comfort level of the patient.

Case Reports

Case 1

A 25-year-old male highway construction worker sustained a crush injury when a 2,500-pound steel I-beam fell on his right foot. The patient was taken to a local level I trauma center, where evaluation revealed an open crush injury to the right midfoot, with extensive soft-tissue loss and disruption of the anterior tibial artery. The posterior tibial pulse was palpable. Radiographic evaluation revealed multiple fracture dislocations of the right midfoot; there were extensive comminuted fractures of all of the metatarsals as well as the cuneiform, navicular, and cuboid bones (Fig. 12). The foot was believed to be nonsalvageable, and immediate below-the-knee amputation was recommended but refused by the patient. The patient underwent guillotine Chopart's-level amputation of the right foot; no dorsal or plantar skin flaps were left for closure. Postoperatively, the patient's original treating physicians again recommended



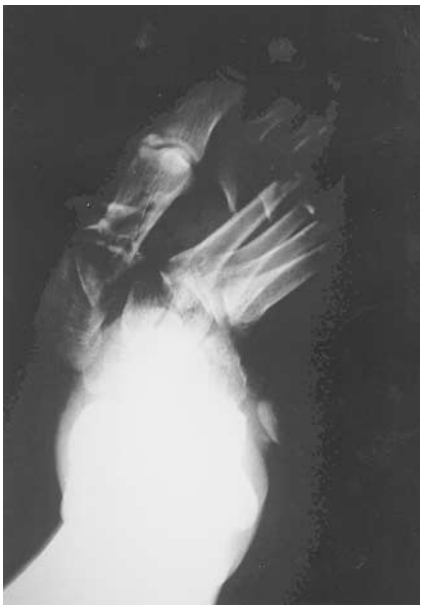

Figure 12. Initial lateral (A) and anteroposterior (B) radiographs revealing a severe crush injury to the midfoot.

below-the-knee amputation owing to a lack of soft-tissue coverage. A series of rubber bands held in place with staples had been positioned within the wound in an attempt to prevent the wound edges from undergoing contraction; however, no specific plan was offered to close the extensive wound.

One week later the patient presented to the senior author's office for a second opinion, stating that he did not want to lose his entire leg. He was extremely anxious and frustrated and had lost confidence in his previous treating physicians. Evaluation at that time revealed an open Chopart amputation of the right foot, with abundant granulation tissue present. The wound was clean, with minimal serosanguineous drainage. There was no sign of infection. Radiographs revealed a normal talus and calcaneus and an intact ankle mortise (Fig. 13).

Because of the large area of tissue loss and the potential for breakdown of a skin graft in this area, it was believed that Syme's amputation was a viable option. The talus and calcaneus were removed, flaps were constructed, and the wound was closed primarily (Fig. 14). The wound healed uneventfully, and the sutures were removed 3 weeks postoperatively. The patient was then referred for fabrication of a prosthetic device. The patient received a preparatory prosthesis 7 weeks postoperatively and was ambulatory with minimal gait training or physical therapy.

He made a full functional recovery but developed a stump neuroma of the superficial peroneal nerve that did not respond to conservative treatment modalities. He subsequently underwent excision of the stump neuroma and superficial peroneal nerve in the distal one-third of the leg to promote an improved outcome (Fig. 15). He continues to function very well, and he walks without any discernible limp and is extremely pleased with the outcome of his surgery (Fig. 16).

Case 2

A 36-year-old woman was referred to the Foot and Ankle Clinic at St Vincent Charity Hospital for evaluation of a deformed right foot and ankle and recurrent chronic ulceration over the right lateral malleolus. Her medical history was significant for type 1 diabetes mellitus, chronic renal insufficiency, and diabetic retinopathy that had left her legally blind. She had undergone a kidney and pancreas transplant 7 years earlier and was not taking any medications for diabetes at the time of presentation. She was receiving chronic immunosuppressive therapy (prednisone and cyclosporine) to prevent organ rejection.

The patient related a history of a right ankle sprain approximately 2 years before the initial visit. Since that time, progressive deformity of the right foot and ankle had developed, despite evaluation and treatment by numerous physicians. The patient's most recent treating physicians all recommended below-the-knee amputation.

The initial physical examination revealed an obvious Charcot deformity of the right ankle with a partially reducible medial and varus dislocation of the foot (Fig. 17). The patient was walking on the lateral







Figure 13. Clinical (A and B) and radiographic (C) appearance of the foot on presentation to the senior author's office.



Figure 14. Appearance of the stump on completion of Syme's amputation.

malleolus and had developed a 1.5 × 2.5-cm superficial ulceration that was not infected and had a granular base. Neurovascular examination revealed palpable pedal pulses and absent protective neurologic sensation. Radiographs at the time of presentation revealed total collapse and fragmentation of the talar body, heterotrophic bone formation within the ankle joint, and medial displacement of the foot from within the ankle mortise (Fig. 18). Radionuclide imaging with sequential technetium-99m methylene diphosphonate and indium-111 scans were performed to rule out osteomyelitis of the lateral malleolus.

Attempts at bracing the foot and ankle were unsuccessful, and the patient was becoming progressively wheelchair bound. After extensive consultation, the patient elected to proceed with amputation, and a Syme procedure of the right ankle was performed. Postoperatively, the patient was maintained nonweightbearing in a wheelchair.

Seven weeks postoperatively, the patient developed a wound dehiscence along 15% to 20% of the in-



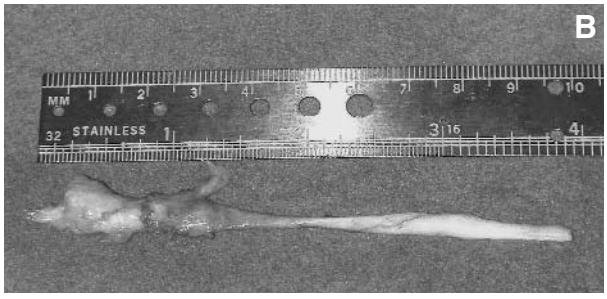

Figure 15. A, Intraoperative photograph demonstrating excision of a stump neuroma of the superficial peroneal nerve in the lower one-third of the leg; B, gross appearance of the excised stump neuroma.

cision, with copious serosanguineous drainage. Cultures of the drainage were negative, and local wound care was initiated. The patient subsequently underwent two surgical revisions of the wound at weeks 8 and 16 postoperatively. The wound continued to drain after the second revision, and a small dehiscence of the incision remained. No clinical or microbiologic signs of infection were present throughout the entire postoperative period. At postoperative week 20, a platelet-derived growth factor was added to the patient's local wound-care regimen; the wound healed within the following 2 months.

One year postoperatively, the patient was still not walking independently with her prosthesis because of the Charcot changes that had developed in the midfoot of the contralateral limb during treatment. However, with consolidation of the Charcot process in the left foot, the patient has since begun walking in her prosthesis. Although the postoperative course was prolonged and difficult, the patient has been very pleased with her care and the fact that she has not required below-the-knee amputation. She lives alone and has progressed to full independent ambulation without any assistive devices other than her prosthesis (Fig. 19).

Case 3

A 52-year-old man with a long-standing history of uncontrolled non-insulin-dependent diabetes mellitus presented to the emergency department of St Vincent Charity Hospital with the chief complaint of a swollen and painful left foot. The patient was febrile, with a temperature of 38.7°C, and had a pulse rate of 110/min. Physical examination revealed a 1.0 × 2.0-cm ulceration plantar to the left fifth metatarsal head with exposed bone. Extensive bullae formation was noted on the dorsum of the foot, with erythema, edema, and calor extending to the level of the tibial tuberosity. Inguinal lymphadenopathy was present. The fourth and fifth toes were cool and dusky. Pedal pulses were palpable; however, protective neurologic sensation was absent. The patient's complete blood cell count with differential revealed a white blood cell count of 28×10^9/L with 18 bands. Radiographic evaluation was significant for osteopenia and cortical disruption of the fifth metatarsal head as well as extensive soft-tissue swelling.

The patient was given broad-spectrum antibiotic coverage and was scheduled for an immediate incision and drainage. As the incision was deepened, it became evident that extensive debridement was required (Fig. 20). The patient had an obvious deep space infection, with osteomyelitis of multiple metatarsals. Partial fourth and fifth ray resections were performed, and the wound was irrigated with a pulsatile lavage system using 6 liters of isotonic sodium chloride solution (Fig. 21). The wound was packed open. Cultures from surgery were positive for heavy growth of group B *Streptococcus agalactiae*.

The initial postoperative dressing change revealed residual necrotic tissue with copious amounts of purulent drainage on compression of the medial arch. An infectious disease consultation was obtained, and







Figure 16. Postoperative appearance of the stump with (A) and without (B) the prosthesis; C, lateral radiograph demonstrating the stump and prosthesis within the patient's shoe.



Figure 17. Initial clinical appearance of the patient demonstrating an obvious Charcot deformity of the right ankle.

below-the-knee amputation was recommended. It was obvious that the foot could not be salvaged. The patient returned to the operating room 4 days after the initial procedure for a second incision and drainage with a more proximal amputation. At that time, Chopart's amputation was performed, and the wound was again packed open (Fig. 22). Local wound care along with twice-daily irrigations was instituted.

The patient's condition stabilized, and he was subsequently scheduled for definitive Syme's amputation with primary closure 5 days after the second debridement. After the procedure, the patient remained in the hospital for an additional week to receive intravenous antibiotics; he underwent oral antibiotic therapy at home for an additional 2 weeks.

The patient maintained a nonweightbearing status, and a modified Jones compression dressing was



Figure 18. Anteroposterior (A) and lateral (B) radiographs revealing severe Charcot changes in the rearfoot and ankle.

used to control edema and to help mold the distal stump. Wound healing progressed uneventfully, and the staples were removed 3 weeks postoperatively. Eight weeks postoperatively, the patient received a preparatory prosthesis and began gait training. Nine months postoperatively, the patient reported minimal disability with the prosthesis and had no complaints about the stump. He was fully ambulatory, with a near-normal gait pattern, and was pleased with the final outcome (Fig. 23).

Conclusion

After its introduction in the late nineteenth century, Syme's-level amputation was largely discarded by many surgeons because of the perception that the wound failure rate was high and because of difficulty fitting the residual stump with a functional prosthesis. Since that time, two major technological advances have helped rekindle interest in the procedure. The first is the improved assessment of the

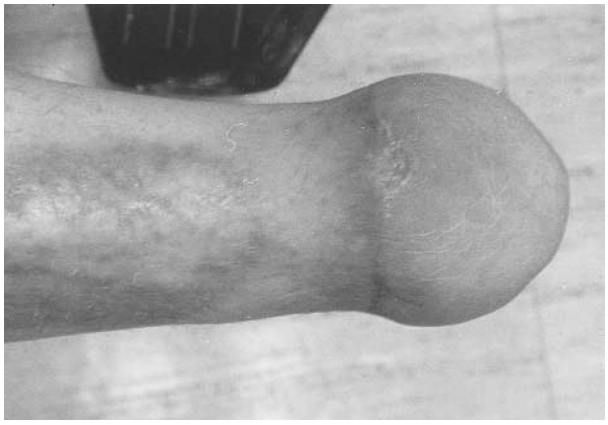

Figure 19. Final appearance of the stump after Syme's amputation.



Figure 20. Intraoperative appearance of the foot during the initial incision and drainage procedure.



Figure 21. Final appearance of the foot after the initial incision and drainage procedure with partial fourth and fifth ray resections.



Figure 22. Appearance of the foot after the second incision and drainage procedure and Chopart's amputation.

various wound-healing parameters that help the surgeon accurately predict the success of various amputation levels. The other development was an improvement in the materials, methods, and techniques used to manufacture prosthetic devices, providing an improved functional outcome for the amputee. The procedure did not experience widespread popularity again until the late 1970s, when Wagner[9, 27] reported excellent results with the procedure.



Figure 23. Final appearance of the healed Syme's amputation stump.

Syme's procedure has proved to be a valuable asset in the surgical treatment of severe foot and ankle deformities that would otherwise require a higher level of amputation. Predictable healing of this procedure can be expected if the proper wound-healing parameters are met and the procedure is properly performed. In addition, ankle amputation is more likely to be accepted by patients than higher-level amputations, although female patients may be disappointed with the final cosmetic appearance. Furthermore, should this amputation level fail, it can be converted to traditional below-the-knee or above-the-knee amputation without difficulty.

Advances in prosthetic materials and technology have enabled the creation of highly functional prosthetic devices. However, it is important to remember that creating a high-quality prosthetic device requires a prosthetist with experience in the management of this level of amputation. Accordingly, the surgeon must ensure that a qualified prosthetist is available to create a well-fitting, functional device.

Syme's procedure enables a more energy-efficient gait than do midfoot and higher-level amputations and requires minimal postoperative physical therapy.

Ease of rehabilitation has been associated with the decreased energy demands required by this amputation level compared with a more proximal level of amputation.[27-29] Minimizing the metabolic cost of walking is an important goal in the diabetic patient with multisystem disease and a limited cardiopulmonary reserve. A final beneficial aspect of this procedure is that patients can be weightbearing for short periods of time without the prosthetic device if necessary, further enhancing the overall quality of life.

Acknowledgment. The Podiatry Institute and Atlanta Slide Art Productions (Tucker, Georgia) for their assistance in the preparation of the photographs.

References

1. LETTS M: Surgical cases and amputations: amputation at the ankle-joint. Clin Orthop **256:** 3, 1990.
2. HARRIS RI: Syme's amputation: the technical details essential for success. J Bone Joint Surg Br **38:** 614, 1956.
3. CATTERALL RC: Syme's amputation by Joseph Lister after sixty-six years. J Bone Joint Surg Br **49:** 144, 1967.
4. RATLIFF AHC: Syme's amputation: result after forty-four years. J Bone Joint Surg Br **49:** 142, 1967.
5. BAKER GCW, STABLEFORTH PG: Syme's amputation: a review of sixty-seven cases. J Bone Joint Surg Br **51:** 482, 1969.
6. BOWKER JH, SAN GIOVANNI TP: "Amputation and Disarticulations," in *Foot and Ankle Disorders*, Vol 2, ed by MS Myerson, p 466, WB Saunders, Philadelphia, 2000.
7. BOWKER JH, SAN GIOVANNI TP: "Minor and Major Lower Limb Amputations in Persons with Diabetes Mellitus," in *Levin and O'Neal's The Diabetic Foot*, 6th Ed, ed by JH Bowker and MA Pfeifer, p 627, CV Mosby, St Louis, 2001.
8. MALONE JW: "Lower Extremity Amputation," in *Vascular Surgery: A Comprehensive Review*, 4th Ed, ed by WS Moore, p 822, WB Saunders, Philadelphia, 1993.
9. WAGNER FW: A classification and treatment program for diabetic, neurotrophic and dysvascular foot problems. Instr Course Lect **28:** 143, 1979.
10. DICKHAUT SC, DELEE JC, PAGE CP: Nutritional status: importance in predicting wound-healing after amputation. J Bone Joint Surg Am **66:** 71, 1984.
11. PINZUR MS, SAGE R, STUCK R, ET AL: Transcutaneous oxygen as a predictor of wound healing in amputations of the foot and ankle. Foot Ankle Int **13:** 271, 1992.
12. PINZUR MS, STUCK R, SAGE R, ET AL: Transcutaneous oxygen tension in the dysvascular foot with infection. Foot Ankle Int **14:** 254, 1993.
13. SPITTLER AW, BRENNAN JJ, PAYNE JW: Syme amputation performed in two stages. J Bone Joint Surg Am **36:** 37, 1954.
14. PINZUR MS, MORRISON C, SAGE R, ET AL: Syme's two-stage amputation in insulin-requiring diabetics with gangrene of the forefoot. Foot Ankle Int **11:** 394, 1991.
15. PINZUR MS, SMITH D, OSTERMAN H: Syme ankle disarticulation in peripheral vascular disease and diabetic foot infection: the one-stage versus the two-stage procedure. Foot Ankle Int **16:** 124, 1995.
16. JAHSS MH, MICHELSON JD, DESAI P, ET AL: Investigations into the fat pads of the sole of the foot: anatomy and histology. Foot Ankle Int **13:** 233, 1992.
17. ROBINSON KP: Disarticulation at the ankle using an anterior flap. J Bone Joint Surg Br **81:** 617, 1999.
18. SMITH DG, SANGEORZAN BJ, HANSEN ST, ET AL: Achilles tendon tenodesis to prevent heel pad migration in the Syme's amputation. Foot Ankle Int **15:** 14, 1994.
19. PINZUR MS: Restoration of walking ability with Syme's ankle disarticulation. Clin Orthop **361:** 71, 1999.
20. COTTRELL-IKERD V, IKERD F, JENKINS DW: The Syme's amputation: a correlation of surgical technique and prosthetic management with an historical perspective. J Foot Ankle Surg **33:** 355, 1994.
21. RADCLIFFE CW: The biomechanics of the Syme prosthesis. Artif Limbs **6:** 76, 1961.
22. THE CANADIAN ASSOCIATION OF PROSTHETISTS AND ORTHOTISTS: "Socket Designs for the Syme's Amputee," in *Clinical Aspects of Lower Extremity Prosthetics*, ed by D Weber, p 169, Elgan Enterprises, Oakville, Ontario, 1991.
23. NORTHWESTERN UNIVERSITY MEDICAL SCHOOL PROSTHETIC-ORTHOTIC CENTER: *Prosthetic Manual*, p 227A, Northwestern University Medical School Prosthetic-Orthotic Center, Chicago, 1993.
24. SARMIENTO A: A modified surgical-prosthetic approach to the Syme's amputation: a follow-up report. Clin Orthop **85:** 11, 1972.
25. WATERS RL, PERRY J, ANTONELLI D, ET AL: Energy cost of walking amputees: the influence of level of amputation. J Bone Joint Surg Am **58:** 43, 1976.
26. SINCLAIR WF: Below the knee and Syme's amputation prostheses. Orthop Clin North Am **3:** 349, 1972.
27. WAGNER FW: Amputations of the foot and ankle: current status. Clin Orthop **122:** 62, 1977.
28. PINZUR MS: Amputation level selection in the diabetic foot. Clin Orthop **296:** 68, 1993.
29. PINZUR MS, WOLF B, HAVEY RM: Walking pattern of midfoot and ankle disarticulation amputees. Foot Ankle Int **18:** 635, 1997.