Atypical Presentation of Plantar Fasciitis Secondary to Soft-Tissue Mass Infiltration

Alan Ng, DPM*
Terrance Beegle, DPM†
Andrea K. Rockett, DPM‡

This article describes a patient with plantar fascial pain who presented to the office of one of the authors. Physical examination and the patient's description of the history of symptoms revealed classic signs and symptoms of plantar fasciitis. The patient was treated with numerous conservative modalities, including ultrasound, nonsteroidal anti-inflammatory medications, trigger-point injections, over-the-counter orthoses, and stretching exercises. When the pain was not relieved by these conservative measures, magnetic resonance imaging of the area was performed. Visualization of the insertional area of the plantar fascia revealed a mass inferior to, as well as infiltrated into, the plantar fascia. Surgical excision of the lesion resulted in complete elimination of the patient's pain. (J Am Podiatr Med Assoc 91(2): 89-92, 2001)

Lipomas and lipomatous variants make up 16.1% of all soft-tissue masses found in the body.[1, 2] Of these, 2.1% are found in the foot and ankle.[1] Lipomas are formed by a mass of mature adipose cells and may be surrounded by a thin capsule. Clinically, lipomas and lipomatous variants do not appear to cause pain themselves, but often pain occurs as a result of pressure on an adjacent structure.[3-6] In the English-language literature, lipomas and lipomatous variants have been described in the heel area.[1, 4, 6, 7] In these cases, the soft-tissue mass was clearly evident and the majority of the cases described were in pediatric patients. The type of soft-tissue masses that induced heel pain included lipomas, fibromas, hypertrophied bursae, neuromas, foreign body granulomas, ganglion cysts, and chronic fibrotic thickening of the plantar fascia.[1, 2, 8] The authors describe an atypical presentation of plantar fasciitis in an adult secondary to pressure from a fibrolipomatous mass inferior to the plantar fascia.

*Submitted during second-year residency, Harris County Podiatric Surgical Residency Program, 11231 Richmond Ave, Ste D101, Houston, TX 77082.

†Private practice, Richmond, TX.

‡Attending Physician, Greater Texas Education Foundation, Houston, TX.

Case Report

A 72-year-old woman presented to the office of the second author (T.B.) in Richmond, Texas, with a 6-month history of heel pain in the right foot. The pain was localized to the medial plantar aspect of the heel. The patient noted that her pain was more intense when rising from a seated position, and was markedly worse in the morning. The patient related that the pain had become progressively worse over the preceding few weeks. Her medical history was unremarkable; she stated that she was allergic to penicillin, sulfa drugs, and iodine. She denied use of any medications as well as any type of self-treatment.

Physical examination revealed palpable pulses bilaterally; the results of a gross neurologic examination were within normal limits. There was pain on palpation of the medial plantar heel and tightness of the plantar fascia with dorsiflexion of the right foot.

Mild edema was noted at the medial plantar aspect of the right heel. No palpable mass was identified.

Plain film radiographs of the right extremity did not reveal any calcaneal exostosis or osseous abnormalities. On the lateral radiograph, there was a slight increase in soft-tissue density at the area of the plantar fascial insertion (Fig. 1).

Conservative Treatment

From the information presented thus far, the authors made a diagnosis of plantar fasciitis. The initial course of treatment consisted of an injection of 1 mL of 1% lidocaine with epinephrine and 1 mL of betamethasone sodium phosphate and betamethasone acetate at the plantar fascial insertion area. The symptoms did not resolve, so two more injections were given to the patient over a period of 4 weeks. Other treatment modalities included ultrasound therapy, stretching exercises, over-the-counter orthoses, and nonsteroidal anti-inflammatory medications, which were prescribed at the initial visit and continued over the course of 2 months. During subsequent visits at 2, 3, 4, and 6 weeks, it was noted that the symptoms had improved by only 30%. At 6 weeks following the initial visit, the patient still noted significant pain in the right heel; at this time, because of the recalcitrant pain, magnetic resonance imaging (MRI) was ordered.

Magnetic resonance imaging revealed an increase in signal intensity on the T1-weighted sagittal view at the area inferior to the plantar fascia (Fig. 2A). The signal intensity was well differentiated from the normal anatomical structures. The area of increased signal intensity on the T1-weighted axial view coursed from the plantar aspect of the plantar fascial insertion to the medial aspect of the ankle, ending just inferior to the medial malleolus (Fig. 2B). The T2-weighted image did not reveal any significant increase in signal intensity at the medial plantar heel. Magnetic resonance imaging did reveal minimal infiltration of the mass into the plantar fascia. An initial diagnosis of a lipomatous mass as a cause of the plantar fascial symptoms was made. At this time, conservative treatment options had been exhausted

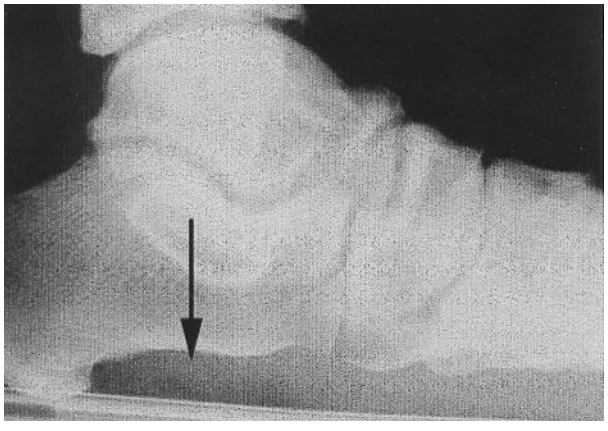

Figure 1. Lateral radiograph showing area of increased opacity from the soft-tissue mass (arrow).

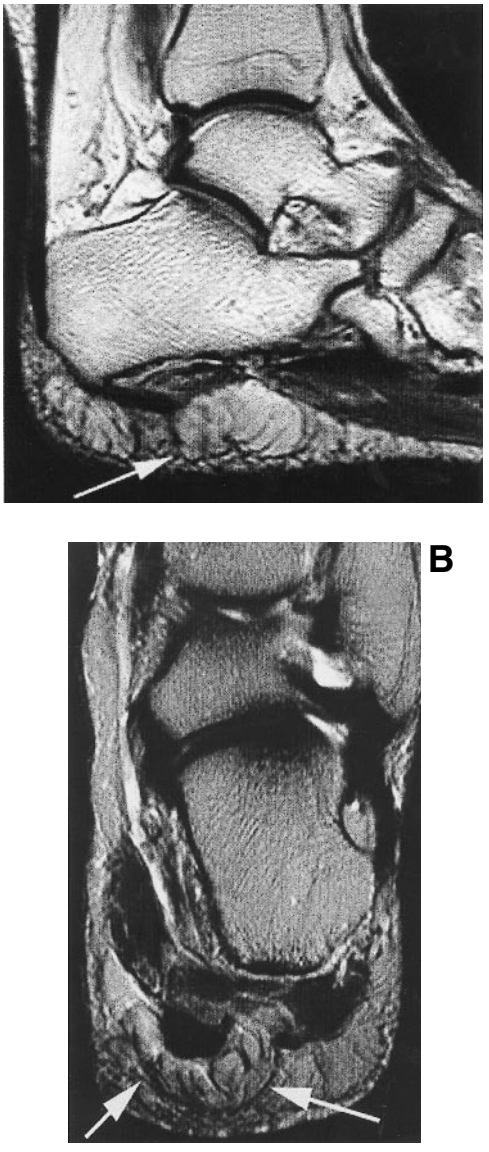

Figure 2. A, Sagittal T1-weighted MR image illustrating a well-demarcated mass with markedly increased signal intensity inferior to the plantar fascia (arrow). B, Axial T2-weighted MR image illustrating the medial extent of the mass (arrows).

and surgical excision of the soft-tissue mass was discussed with the patient. The patient was amenable to the surgical excision and was scheduled for surgery.

Surgical Treatment

With the patient under general anesthesia, an 8-cm transverse incision was made beginning at the plantar aspect of the right heel and coursing medially just inferior to the medial malleolus (Fig. 3). On deepening of the incision, an abnormal-appearing lipomatous type of mass was noted. A visual contrast was noted between the physiologic fat present in the heel and the lipomatous mass (Fig. 4). With the use of a blunt dissection technique, the soft-tissue mass was freed from all subcutaneous tissue. It was noted to course from the central band of the fascia medially up to the area just inferior to the medial malleolus. Further dissection of the mass from its inferior attachments revealed that the mass had become embedded between the fibers of the medial and central bands of the plantar fascia. In order to totally excise the mass, the medial and central bands of the plantar fascia were transected, and a portion of the plantar fascia was removed (Fig. 5). A Penrose drain was placed in the surgical site because of the dead space created by the removal of the soft-tissue mass. The wound was closed with 3-0 polyglycolic acid and 3-0 nylon suture and dressed with a mild compressive dressing.



Figure 3. Placement of the transverse incision over the medial plantar aspect of the foot.

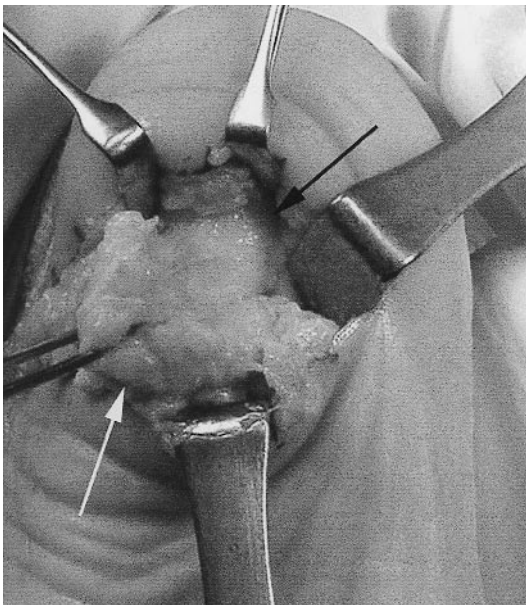

Figure 4. Intraoperative view showing the soft-tissue mass (white arrow) and the plantar fascia (black arrow).

Postoperative Results

The patient was placed in a removable walking cast and kept nonweightbearing for 3 weeks, subsequently progressing to weightbearing as tolerated. Five days postoperatively, the patient developed a hematoma at the medial aspect of the foot. The hematoma was aspirated and drained, which resulted in a significant decrease in pain.

The pathology report revealed the presence of benign fibroadipose connective tissue, consistent with

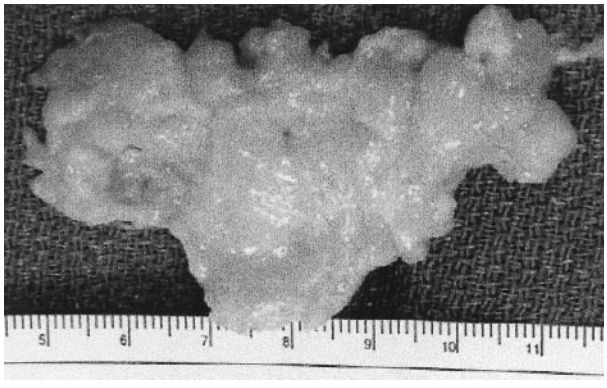

Figure 5. Excised mass, measuring 6 cm in length.

fibrolipoma. Gross examination of the mass revealed multiple fragments of fibrofatty tissue. The microscopic examination showed portions of fibroadipose connective tissue composed of broad, fibrous trabeculae that divided adult-type adipose tissue into well-defined areas (Fig. 6). No cytologic atypia was noted.

One month postoperatively the patient reported complete resolution of symptoms, and had no complaints of pain. At 8 weeks postoperatively, the wound was completely healed. At the 12-month follow-up examination, the patient remained symptom-free.

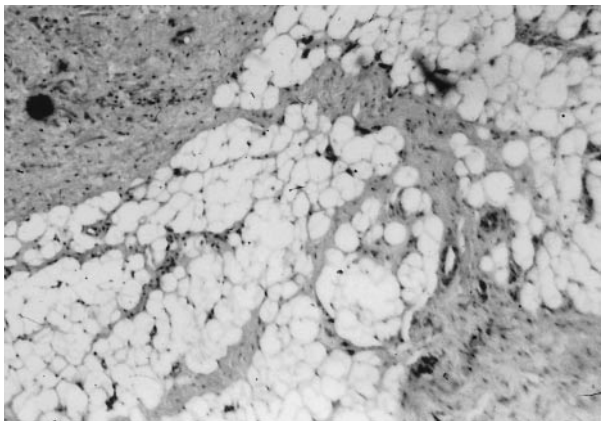

Figure 6. Photomicrograph of the fibrolipoma revealing physiologic adipose cells divided by fibroadipose connective tissue (H&E, ×40).

Conclusion

Plantar fasciitis is a common pathologic entity that is treated initially with conservative modalities.[1, 2, 4, 9] For patients with recalcitrant pain whose symptoms do not resolve with conservative treatment, surgical treatment is the option of last resort.[5] Conservative treatment will reduce pain in the majority of patients with typical plantar fasciitis. In the case presented here, conservative treatment showed minimal efficacy, prompting the physicians to investigate the symptoms further. Magnetic resonance imaging revealed an abnormal soft-tissue mass that was the underlying cause of the plantar fascial symptoms. Excision of the soft-tissue mass, which was later diagnosed as a fibrolipoma, resulted in complete resolution of symptoms.

Acknowledgment. Oscar Mangini, MD, and the West Houston Medical Center Pathology Department for preparing the photomicrograph and for analyzing the soft-tissue mass.

References

1. Kransdorf MJ: Benign soft-tissue tumors in a large referral population: distribution of specific diagnoses by age, sex, location. AJR Am J Roentgenol **164:** 395, 1995.
2. Kransdorf MJ, Moser RP, Meis JM, et al: Fat-containing soft-tissue masses of the extremities. Radiographics **11:** 81, 1991.
3. Tisdel CL, Donley BG, Sferra JJ: Diagnosing and treating plantar fasciitis: a conservative approach to plantar heel pain. Cleveland Clin J Med **66:** 231, 1999.
4. Kerman BL, Foster LS: Lipoma of the foot: a large and unusual case. J Foot Surg **24:** 345, 1985.
5. Milgram JW: Massive fibrolipoma of a toe. J Foot Ankle Surg **38:** 223, 1999.
6. Feldman M, Healy K, Nach W, et al: Plantar approach for excision of bilateral soft tissue masses in a child. J Foot Surg **28:** 60, 1989.
7. Elsahy NI, Lorimer A: Congenital fibrolipomata in both heels. Plast Reconstr Surg **59:** 434, 1977.
8. Berlin SJ, Mirkin GS, Tubridy SP: Tumors of the heel. Clin Podiatr Med Surg **7:** 301, 1990.
9. Kwong PK, Kay D, Voner RT, et al: Plantar fasciitis. Clin Sports Med **7:** 119, 1988.