Skin Grafting of Partial-Thickness Burns in the Diabetic Foot

To the Editor:

There are various maladies related to a diabetic foot wound that may lead to amputation,[1] but the triad of peripheral neuropathy, peripheral arterial disease, and infection is the harbinger of the final cataclysmic events of gangrene and amputation.

Extensive foot burn injuries occurring in patients with diabetes mellitus may present an added challenge to the clinician. Associated injuries, as well as acute and chronic medical conditions, increase morbidity and mortality of burned patients.[2] Deep burns of any part of an extremity may restrict circulation and lead to ischemia and limb loss.

The goals of immediate management of a burn wound are the same as those of management of any wound.[3] These goals are to limit infection by eliminating necrotic tissue, to provide a moist healing environment in order to promote epithelialization, and to protect the wound and the surrounding tissue from further trauma.

There are a variety of techniques used for cleansing burn wounds. Topical agents have significantly decreased the incidence of sepsis and have improved wound healing. The choice of dressings depends on many patient- and wound-related factors; synthetic, biologic, and biosynthetic dressings are used to treat burn wounds at different skin depths. Split-thickness skin grafts are the primary method of coverage used in reconstruction of the burned foot.[4] The successful use of skin grafts requires adequate blood supply to the underlying tissues.

Studies conducted by Boss and Arons in 1982 determined that although all burns of the feet do not necessarily have to be treated by debridement and skin grafting, this technique allows for early return to work with stable, well-healed wounds.[5] Early excision and skin grafting has become a popular method of burn treatment, although the procedure is limited by difficulty in diagnosing burn depth, limitation of donor sites, and the technical skills needed to excise three-dimensional areas.

There are few reports in the literature on the management of partial-thickness burns in the diabetic foot. The authors present an interesting case report on this subject.

Case Report

A 60-year-old man with diabetes mellitus presented to the emergency department at Staten Island University Hospital in Staten Island, New York, with the chief complaint of burns on the right foot of 1 week's duration. The patient reported that his foot was burned after he soaked it in water that did not feel hot to him. He was soaking his foot to clean a diabetic ulcer on the plantar aspect of his right heel (Fig. 1).

The patient's medical history was significant for insulin-dependent diabetes mellitus, peripheral neuropathy, and ulceration on the plantar aspect of the right heel. His only medication was insulin therapy, which maintained strict control of glycemia.

On initial presentation, the patient had fever and chills. Vascular examination revealed palpable dorsalis pedis pulses bilaterally. Neurologic examination indicated that vibratory, sharp/dull, and light-touch sensations were diminished in both feet.

On physical examination, partial-thickness burns were noted on the plantar medial aspect of the right foot (Fig. 1), the dorsal aspect of the right foot (Fig. 2), and the lateral aspect of the right heel. These wounds measured 2×3 cm, 5×4 cm, and 2×4 cm, respectively. There was evidence of infection at the dorsal foot burn, with surrounding erythema and edema. Also noted was a 1×1-cm partial-thickness ulcer on the plantar aspect of the right heel. This area showed signs of epithelialization and no signs of infection.



Figure 1. Ulcer and partial-thickness burn on the plantar aspect of the right foot.



Figure 2. Partial-thickness burn on the dorsum of the foot.

The patient was admitted because of cellulitis and was administered intravenous antibiotics. Local wound care included debridement of devitalized tissue, cleansing with soap and water, and application of silver sulfadiazine cream, followed by coverage with a nonadherent dressing and dry gauze.

After 1 week, the cellulitis disappeared; however, the foot burns located on the dorsum of the foot and the lateral aspect of the heel showed no evidence of re-epithelialization. The plantar foot burn did show signs of adequate re-epithelialization. The assessment was that the wound was a deep second-degree burn or a deep partial-thickness burn requiring debridement and skin grafting. The patient was brought to the operating room for debridement, irrigation, and skin grafting (Fig. 3). The skin graft was secured to the skin with staples. This process was followed by application of a nonadherent dressing and a bulky protective dressing, immobilizing the patient's leg. After 5 days, the skin graft was well adhered (Fig. 4). The donor site healed well. The patient was discharged on postoperative day 6.

Discussion

When factors such as peripheral vascular disease and infection have been ruled out in cases of nonhealing wounds and when conservative management has been unsuccessful, early debridement and grafting can be the mainstay of treatment. Generally, partial-thickness burns that show no signs of healing after 2 to 3 weeks can be treated with skin grafting.[2] Deeper injuries may require flap reconstruction with skin grafting. Burns on the feet of diabetic patients may be predisposed to infection. Early wound closure prevents the sequelae of infection, gangrene, and amputation.

JEAN V. ARCHER, DPM
Jamaica Hospital Medical Center
8900 Van Wyck Expressway
Jamaica, NY 11418

MICHAEL L. COOPER, MD
Burn Unit
Staten Island University Hospital
Staten Island, NY

References

1. LEVIN M: Diabetic foot wounds: pathogenesis and management. Adv Wound Care **10:** 24, 1997.
2. GORDON M, GOODWIN CW: Burn management: initial assessment, management, and stabilization. Nurs Clin



Figure 3. Intraoperative photograph of the wounds covered with skin grafts.



Figure 4. The skin grafts at postoperative day 5.

North Am **32:** 237, 1997.
3. Staley M, Richard R: Management of the acute burn wound: an overview. Adv Wound Care **10:** 39, 1997.
4. Kucan JO, Bash D: Reconstruction of the burned foot. Clin Plast Surg **19:** 705, 1992.
5. Boss WK, Arons MS: Cited by Leen ME, Feldman M, Schoenberger S, et al: Split-thickness skin graft of a pedal oil burn in an adolescent female. JAPMA **81:** 435, 1991.

Foot Deformities Associated with Apert Syndrome

To the Editor:

Apert syndrome, also known as acrocephalosyndactyly, is a rare variant of craniosynostosis. The premature fusion of the coronal sutures of the skull predisposes the person with Apert syndrome to display the most typical facial feature of the syndrome, namely, an elongated skull. Similar craniofacial features occur in other syndromes, but no other syndrome is associated with complex malformations of the hands and feet. The proximal portions of the limbs may be normal, with the most significant malformations resulting from Apert syndrome always located distally.

Approximately 350 cases of Apert syndrome have been reported in the medical literature, mainly as isolated cases or as short case series. The original description of the syndrome by Apert[1] included nine patients. Blank[2] emphasized the genetic aspects of the syndrome in 39 patients. Gruber[3] provided a lengthy description of the clinical aspects of the syndrome in a study of 24 patients. Hoover et al[4] reviewed 20 patients and provided useful information on the function and treatment of the malformations of the hands that were observed. Upton[5] described and classified the pathologic anatomy of the abnormalities of the limbs in 58 patients. Cohen and Kreiborg[6] performed an exhaustive study of 136 patients, analyzing them from clinical, dermatoglyphic, radiographic, anatomical, and histologic points of view.

Blauth and von Torne[7] reviewed 80 cases of Apert syndrome and found that the anomalies of the feet and the hands were similar in 75% of these cases and were commonly bilateral and symmetric. They classified syndactylism of the toes into three categories. Type I feet are characterized by fusion of the second, third, and fourth toes, with the first and fifth toes free. The great toe is broad and may be short or become progressively shorter over time, and often exhibits medial deviation. In the study by Blauth and von Torne, 12.5% of patients had type I feet; in the series reported on by Cohen and Kreiborg, 27% of the patients had type I feet. In type II feet, the second through fifth toes are fused, the forefoot is supinated, and the great toe is in a varus and dorsiflexed position. Thirty percent of the patients in the series reported on by Blauth and von Torne and 19% in the series reported on by Cohen and Kreiborg had type II feet. Type III feet have all toes fused, with the first toe possibly hyperextended. Blauth and von Torne reported 57.5% of their patients as having type III feet, and Cohen and Kreiborg reported 54% of their patients as being in the same category. Separation of the fifth toe may occur in some cases of type II and III feet, but only on the plantar surface.

Schauerte and St-Aubin[8] reported their findings of the progression of hindfoot and midfoot fusion. Calcaneocuboid synostosis often begins by age 2½ and progresses to fusion of the lateral cuneiform bone and the third metatarsal. As these patients get older, they develop synostosis of the navicular bone, the medial cuneiform bone, and usually the intermediate cuneiform bones as well. Beligere et al[9] observed calcaneocuboid fusion in only two of ten patients, but the full extent of the synostosis can be determined only after the attainment of skeletal maturity.

In the forefoot, the metatarsals often display disturbances of normal tubulation[8] with varying degrees of fusion between the first and second metatarsals[7, 8, 10, 11] or duplication of the first metatarsal.[2] Interphalangeal joint fusion has been commonly described, but the fusion of the phalanges or metatarsals of contiguous toes is a less frequent finding.[8, 12] The most consistently reported skeletal deformity is the triangular form of the proximal phalanx of the great toe[10, 13] or the widening of the great toe with phalangeal duplication.[10-12, 14]

As a person with Apert syndrome grows, the great toe becomes increasingly short in relation to the other toes, as well as deviated in a varus and dorsiflexed position.[7, 11] The bones of the midfoot and hindfoot progressively fuse as motion decreases and the foot becomes more supinated. With progressive shortening of the first ray, most of the weight distributed on the plantigrade foot is transferred to the second metatarsal, causing the development of plantar callosities.

Upton[5] made a radiographic distinction between two basic foot patterns of individuals with Apert syndrome. Type I feet are those in which the cuneiform bones and the first metatarsal are well segmented at birth. The proximal phalanx of the great toe is abnormal, causing medial deviation of an abnormally large

distal phalanx. With growth, the great toe becomes relatively shorter, but sufficient length is maintained by a relatively normal first metatarsal. These foot types are the least symptomatic. Type II feet display a bifid origin of a short first metatarsal from multiple cuneiform bones, with the first metatarsal commonly coalesced with the navicular bone. The duplication of the first metatarsal occurs proximally, but there is always a single metatarsal head. There is complete or partial side-to-side fusion with the second metatarsal. The complex triangular bone in the proximal phalangeal position may also form a side-to-side synostosis with the second ray. Growth of the first ray is more restricted, and there is greater medial deviation of the toe and the presence of more clinical symptoms.

Case Report

The authors examined a 9-year-old boy with Apert syndrome, as diagnosed elsewhere, who was brought for consultation because of pain and deformity in both feet that had not improved with the use of orthoses. The most remarkable findings of the clinical examination were gait with supination of both feet, syndactyly of all of the toes (Fig. 1), with separation of the fifth toe on the sole only, and excessive pressure on the middle metatarsals (Fig. 2).

Radiographic examination revealed calcaneocuboid and cuneonavicular fusion (Fig. 3), a short first metatarsal with medial deviation and duplication of the proximal phalanx, proximal interphalangeal joint fusion of the second through fifth toes, and fusion of the distal phalanges of the third and fourth toes (Fig. 4).

The patient was treated with a basal metatarsal osteotomy and placement of the bone in its normal position, which resulted in remarkable clinical and functional improvement.

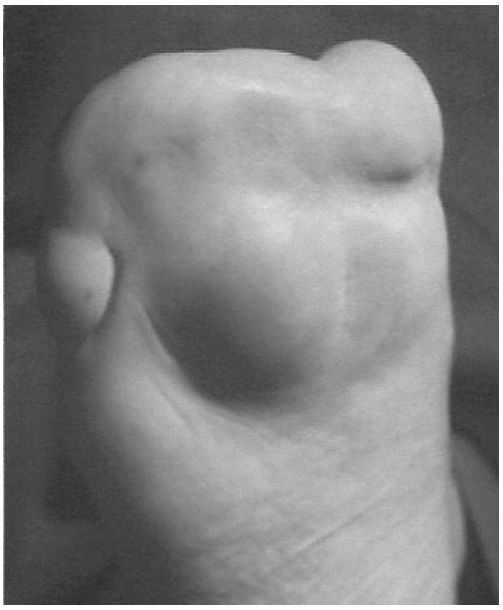

Figure 2. View of the plantar surface showing separation of the fifth digit and the results of excessive weightbearing by the middle metatarsals.

Discussion

The severe foot deformities associated with Apert syndrome have not been well documented in the literature. This seems to indicate that clinicians have not given adequate attention to foot deformities in general.

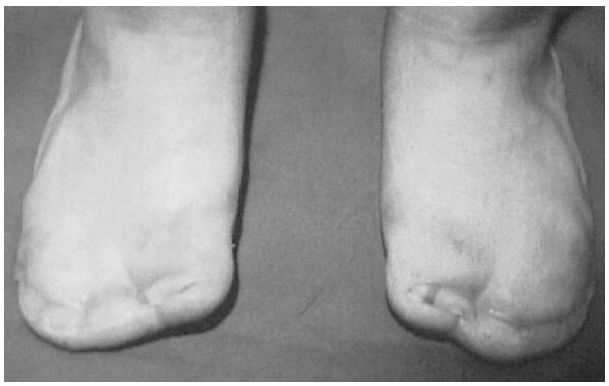

Figure 1. The forefoot is rigid and supinated, and there is syndactyly of all of the toes.

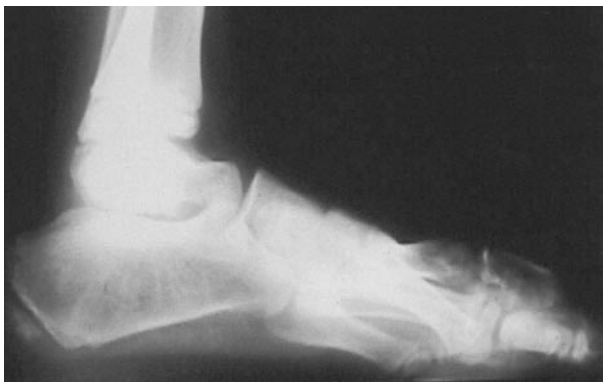

Figure 3. Weightbearing lateral radiograph reveals calcaneocuboid and cuneonavicular fusion.



Figure 4. Weightbearing dorsoplantar radiograph reveals the short first metatarsal, with medial deviation and duplication of the proximal phalanx, and fusion of the distal phalanges of the third and fourth toes.

The purpose of this article was to present an isolated case of Apert syndrome, concentrating on the associated deformities of the feet. The patient presented here displayed a type III foot, according to the classification system described by Blauth and von Torne,[7] with separation of the fifth toe only on the plantar surface. The patient also displayed a type II foot, as categorized by Upton,[5] with duplication of the proximal phalanx. Interphalangeal joint fusion of the toes has been commonly reported, but the fusion of phalanges of contiguous toes, as was found in this patient, is a less frequent finding.[8, 12]

Surgical treatment of deformities of the foot in patients with Apert syndrome is indicated only to relieve pain and to remedy difficulties with fitting and using footwear when all conservative methods of treatment have failed.[7] However, surgical treatment may provide a more permanent solution than orthotic treatment, especially in younger patients. Although syndactyly of the digits contributes to the deformities, it does not require treatment.

The specific surgical treatment of the foot for patients with Apert syndrome has been described for deformities of the metatarsal and the great toe. It consists of osteotomy of the proximal phalanx, resection of the intermetatarsal bony bridge, and basal metatarsal osteotomy and placement of the bone in its normal position.[7, 8, 10-12]

ANDRÉS CARRANZA-BENCANO, MD
JOSÉ ANTONIO GÓMEZ-ARROYO, MD
JOSÉ JUAN FERNÁNDEZ-TORRES, MD
FERNANDO MOYA CORRAL, MD
"Virgen del Rocío" University Hospital
c/o Santa Clara 16, 1, D
41002, Seville, Spain

References

1. APERT E: De l'acrocephalosyndact. Bull Mem Soc Med Hop Paris **23:** 1310, 1906.
2. BLANK CE: Apert's syndrome (a type of acrocephalosyndactyly): observation on a British series of thirty nine cases. Ann Hum Genet **24:** 151, 1960.
3. GRUBER GB: Beitrage zur Frage "gekoppelter" Missbildungen (Acrocephalosyndactyl und Dysenchaphlia splanenocystica). Beitr Pathol Anat **93:** 458, 1934.
4. HOOVER GH, FLATT AE, WEISS MW: The hand in Apert's syndrome. J Bone Joint Surg Am **52:** 878, 1970.
5. UPTON J: Apert syndrome: classification and pathologic anatomy of limb anomalies. Clin Plast Surg **18:** 321, 1991.
6. COHEN MM JR, KREIBORG S: Hands and feet in the Apert syndrome. Am J Med Genet **57:** 82, 1995.
7. BLAUTH W, VON TORNE O: "Apert-Fuss" ["Apert's foot" (in acrocephalo-syndactyly)]. Z Orthop **116:** 1, 1978.
8. SCHAUERTE EW, ST-AUBIN PM: Progressive synosteosis in Apert's syndrome (acrocephalosyndactyly) with a description of roentgenographic changes in the feet. Am J Roentgenol Radium Ther Nucl Med **97:** 67, 1966.
9. BELIGERE N, HARRIS V, PRUZANSKY S: Progressive bony dysplasia in Apert syndrome. Radiology **139:** 593, 1981.
10. DELL PC, SHEPPARD JE: Deformities of the great toe in Apert's syndrome. Clin Orthop **157:** 113, 1981.
11. MEYER JL: Apert's syndrome (acrocephalosyndactylism). J Foot Surg **20:** 210, 1981.
12. FEINSTEIN M, RUBIN L: The foot and Apert's syndrome: acrocephalosyndactyly. JAPA **68:** 748, 1978.
13. COHEN MM JR: An etiological and nosologic overview of craniosynostosis syndromes. Birth Defects Orig Artic Ser **11:** 137, 1975.
14. BADA JL, ALVAREZ F, VILADOT R: Lesiones del pie en el síndrome de Apert: a propósito de un caso. Revista de Medicina y Cirugía del Pie **9:** 59, 1995.

Use of a Clonidine Patch in the Treatment of Ischemic Ulcerations of the Foot

To the Editor:

Clonidine is indicated for the treatment of hypertension and may be used alone or in combination with other antihypertensive medications. Clonidine is a centrally acting α_2-agonist.

Clonidine was originally marketed as a nasal decongestant in 1962. At that time, clonidine was also

found to cause hypotension, sedation, and bradycardia. Taking advantage of its side effects, researchers began to use it to treat hypertension in the 1970s and also for Tourette's syndrome beginning in the 1980s. Recently it has been used for behavioral symptoms of attention-deficit hyperactivity disorder, hyperarousal syndromes associated with post-traumatic stress disorder, and aggression.[1]

Clonidine is available in patch form as the Catapres-TTS Transdermal Therapeutic System (Boehringer Ingelheim Pharmaceuticals, Ridgefield, Connecticut). Catapres-TTS is available in three strengths: 1, 2, and 3, which correspond to a clonidine content of 2.5 mg, 5.0 mg, and 7.5 mg, respectively. These patches deliver daily doses of 0.1 mg, 0.2 mg, and 0.3 mg, respectively. Catapres-TTS patches are available in boxes of four packets. Each packet consists of a patch on a plastic sheet and a round adhesive cover.[2]

Clonidine stimulates the α_2-adrenergic receptors in the brain stem. This causes a reduced sympathetic outflow from the central nervous system along with a decrease in peripheral resistance, renal vascular resistance, heart rate, and blood pressure. Renal blood flow and glomerular filtration rate remain largely unchanged. Normal postural reflexes remain intact; therefore, orthostatic hypotension is infrequently encountered.[2]

Catapres-TTS was developed to release clonidine at an approximately constant rate for 7 days. During long-term therapy, cardiac output tends to return to pretherapy levels while peripheral resistance remains low.

Sudden cessation of clonidine has in some cases resulted in nervousness, agitation, headache, and confusion accompanied or followed by a rapid rise in blood pressure and elevated catecholamine concentrations in the plasma. The likelihood of these reactions to discontinuation of clonidine therapy appears to be greater after administration of higher dosages or continuation of other β-blocker treatment.[2] Special caution, therefore, is recommended in such situations.

Clonidine may potentiate the depressive effects of alcohol, barbiturates, or other sedating drugs on the central nervous system. Owing to the potential for additive effects, such as bradycardia and atrioventricular block, caution is advised in patients receiving clonidine along with agents known to affect sinus node function or atrioventricular nodal conduction. Transdermal therapeutic systems may induce localized miliaria, microbial growth, and allergic contact dermatitis.[3]

Most adverse systemic effects during clonidine therapy are mild and tend to decrease with continued therapy. Reported systemic effects include dry mouth, drowsiness, fatigue, headache, lethargy, sedation, insomnia, dizziness, impotence or other sexual dysfunction, dry throat, constipation, nausea, change in taste, and nervousness. However, in a 3-month trial, 51 of 101 patients had localized skin reactions that included erythema, pruritus, or both. Allergic contact sensitization was also seen in five patients.[2] These reactions, however, subsided with subsequent treatments.

A study conducted in 1997 found that Catapres-TTS lowers both systolic and diastolic blood pressure within the first 24 hours of application. The antihypertensive effect persists at the end of the first week, as well as after 14 days. Clonidine seems to act as an antihypertensive agent rather than a hypotensive drug, as it normalizes blood pressure without lowering it below physiologic levels.[4]

Catapres-TTS has been shown to reduce the cardiovascular impact of hypertension in patients with diabetes mellitus. Clonidine significantly reduced systolic (153 *versus* 163 mm Hg) and diastolic (88 *versus* 98 mm Hg) blood pressure, left ventricular mass (94 *versus* 99 g/m^2), and fasting blood glucose levels. Urinary albumin excretion was also noted to decrease with the use of Catapres-TTS.[5]

Bathing appears to have a negligible effect on plasma concentration levels of clonidine. However, the plasma clonidine concentration was found to be greater in patients during the summer months than during the winter. It is theorized that the passage of an agent across the skin might be enhanced by greater hydration of the stratum corneum due to sweating.[6] Increased blood flow through the dermal vessels as well as higher relative humidity levels could also contribute to the higher plasma clonidine levels seen during the hot summer months.

Podiatric Applications

Podiatric applications include the administration of Catapres-TTS on the lower extremity as a means of increasing perfusion in vascularly compromised regions. The administration of clonidine results in a decreased sympathetic outflow from the central nervous system. This in turn produces a vasodilation response in the peripheral vessels, thereby decreasing peripheral resistance. The authors theorize that this results in an increase in oxygenation and blood tissue perfusion to previously ischemic areas. Distal lower-extremity ulcerations are often the consequence of chronic ischemic disease that cannot be treated with bypass surgery, such as frostbite, Mönckeberg's sclerosis, Buerger's disease, and Raynaud's phenomenon. In other circumstances, the patient may not be a candidate for a bypass of the diseased vessel. Catapres-

TTS thus offers the physician a viable alternative treatment.

Although the Catapres-TTS patch is available in formulations that deliver 0.1 mg, 0.2 mg, or 0.3 mg of clonidine per day, only the 0.1-mg system is used for lower-extremity applications. This low dose reduces the risks of possible systemic side effects that may result from stronger concentrations of the drug.

The Catapres-TTS patch therapy is used in cooperation with the patient's primary-care physician owing to the systemic effects of the drug. The patient applies the 0.1-mg patch once a week. Its placement depends on the location of the ulceration. When the ulceration is located on the rearfoot or midfoot, the patch is applied just proximal to the lesion. If the ulceration is located on a digit, the patch is applied at the proximal aspect of the affected digit. The patch is changed weekly, and the patient is permitted to get it wet. The authors stress that this treatment acts as an adjunct therapy and does not replace local wound care and supportive therapies.

Patients treated with Catapres-TTS by the authors were selected on the basis of their nonresponse or minimal response to local wound therapy and recommendations from vascular surgeons that bypass surgery would be ineffective. Patients were also chosen on the basis of their history of compliance with therapeutic regimens. Because this medication has potentially serious side effects, compliance and follow-up visits are important. Blood pressure readings were taken at each visit to ensure that no significant pressure problems developed during treatment. If it is necessary to discontinue the medication, the patient must be closely monitored, as sudden cessation can lead to serious systemic problems. As mentioned earlier, the use of clonidine patches to treat ischemic foot ulcerations should be avoided in patients taking medications that affect sinus node function or atrioventricular nodal conduction. It should also be avoided or closely monitored in patients who are taking sedatives or barbiturates.

The authors have used this therapeutic modality in 30 patients who were not considered candidates for surgery. Of these 30 patients, 18 had ischemic digital ulcerations. In 13 of these patients, healing of the ulcerations occurred with local wound care in conjunction with use of the 0.1-mg clonidine patch, while 4 patients underwent digital amputations and 1 had a transmetatarsal amputation. The remaining 12 patients had ulcerations on the midfoot or rearfoot. Of these, 8 went on to heal, while 2 had transmetatarsal amputations and 2 had below-the-knee amputations. In treating these 30 patients, the authors encountered minimal adverse reactions to the use of this medication, in part because the lowest concentration of clonidine available was used. Two patients experienced mild pruritus around the patch; one experienced headaches; and three experienced dry mouth. None of these reactions were severe enough to require discontinuation of the medication. However, patients need to receive thorough instructions on the proper application of the patch and its potential for side effects. The patch was applied for a period ranging from 10 weeks to 5 months, depending on the treating physician and the success or lack of success of the treatments rendered.

Conclusion

The authors have found that Catapres-TTS can be successfully used to increase local blood flow to vascularly compromised areas and may act as an adjunct in the treatment of ischemic ulcerations. Catapres-TTS does not replace current treatment modalities; rather, it serves to complement current wound-healing methodologies. When Catapres-TTS is used, a team approach by the internist and the podiatric physician is needed to monitor any possible systemic effects of the drug. A study should be conducted to fully evaluate the effect of Catapres-TTS on ischemic ulcers, but the authors believe that their findings are valuable and should prompt discussion. Catapres-TTS may offer the physician another alternative in the treatment of ischemic ulcerations of the lower extremity.

KEVIN J. O'CONNOR, DPM
JOHN F. GRADY, DPM
Department of Veterans Affairs
Chicago Healthcare System, Westside Division
Chicago, IL

Foot & Ankle Associates
4650 Southwest Hwy
Oak Lawn, IL 60453

CAROL J. MOORE, DPM
JIM LICANDRO, DPM
Department of Veterans Affairs
Chicago Healthcare System, Westside Division
Chicago, IL

LORI A. BRENNER, DPM
Foot & Ankle Associates
Oak Lawn, IL

References

1. OESTERHELD J, TERVO R: Clonidine: a practical guide for usage in children. S D J Med **49:** 234, 1996.

2. *Physicians' Desk Reference*, p 680, Medical Economics, Montvale, NJ, 1997.
3. CORAZZA M, MANTOVANI L: Allergic contact dermatitis from a clonidine transdermal delivery system. Contact Dermatitis **32:** 246, 1995.
4. GUAGNANO MT, PACE P: Transdermal clonidine therapy and blood pressure nocturnal fall in mild hypertensive male subjects. Clin Exp Hypertens **19:** 331, 1997.
5. GIUGLIANO D, ACAMPORA R: Hemodynamic and metabolic effects of transdermal clonidine in patients with hypertension and non-insulin-dependent diabetes mellitus. Am J Hypertens **11:** 184, 1998.
6. FUJIMURA A, SASAKI M: Influences of bathing and hot weather on the pharmacokinetics of a new transdermal clonidine. J Clin Pharmacol **36:** 892, 1996.

Acral-Lentiginous Melanoma

To the Editor:

Cutaneous malignant melanoma is a devastating disease with a potentially lethal course. There are five types of cutaneous malignant melanoma: superficial spreading, lentigo maligna, nodular, acral-lentiginous, and amelanotic.[1-3] A cutaneous malignant melanoma develops in one of two ways: a mole undergoes a malignant transformation, or a group of pigment cells in normal skin becomes malignant.[4] Clinical warning signs are often referred to by the letters A, B, C, and D: A represents asymmetry of the lesion; B, border irregularity; C, color variation; and D, diameter greater than 6 mm (approximately the diameter of a pencil eraser).[1]

Numerous studies demonstrate a high incidence of cutaneous malignant melanoma in the lower extremity.[1, 3, 5] Cosman et al[6] reported the lower extremity to be the most frequently affected site in cases of cutaneous malignant melanoma, accounting for 26.1% to 39.6% of all reviewed cases. In contrast to nonmelanoma skin cancers, in which 85% of lesions appear on the head and neck, malignant melanoma appears primarily in the trunk in men and the lower extremity in women.[1] Clark et al[7] reported that malignant melanoma on the thigh and lower leg is three times more common in women than in men.

Early recognition and surgical excision to prevent tumor spread are paramount for patient survival. There are three local classification systems designed to help determine the severity of a lesion. The Clark classification system is based on the level of tissue invasion.[1, 7, 8] The Breslow[9] and Day[10, 11] classification systems are based on the depth (in millimeters) of tissue invasion. Clark and colleagues[7, 8] defined five levels of microinvasion by melanoma: in level I, the tumor invades the epidermis; in level II, the tumor penetrates the papillary dermis; in level III, the tumor extends through the papillary dermis; in level IV, the tumor extends to the reticular dermis; and in level V, the tumor invades the subcutaneous tissue. The 10-year survival rates of 1,130 patients reported by the New York University Melanoma Clinical Cooperative Group (NYUMCCG) for levels I through V were 96%, 96%, 90%, 67%, and 26%, respectively.[1]

The Breslow[9] classification measures tumor thickness, in millimeters, from the top of the granular layer to the deepest penetration of the melanoma. There are three thickness levels: less than 0.75 mm, 0.75 mm to 1.50 mm, and greater than 1.50 mm. Day et al,[10, 11] using a multivariate mathematical technique, reported four statistically significant thickness ranges: less than or equal to 0.85 mm, 0.86 to 1.69 mm, 1.7 to 3.59 mm, and 3.60 mm or greater. NYUMCCG 10-year survival rates based on tissue thickness were 98%, 89%, 67%, and 43%, respectively.[1] Day et al[11] also reported that nearly all patients with melanoma of the hands and feet died of the disease if the primary tumor was more than 2.75 mm thick.

The NYUMCCG classified cutaneous malignant melanoma into three stages: stage I, localized; stage II, nodal involvement; and stage III, disseminated disease.[12] Acral-lentiginous melanoma, which occurs on the palms, soles, and subungual area, accounts for 4% to 8% of cases of cutaneous malignant melanoma.[1] Keyhani[13] reported on 228 cases occurring in the foot and 55 occurring in the hand; of melanomas of the foot, 45.4% were subungual and 50% affected the sole. Clark et al[7] reported a high frequency of pedal melanoma in blacks, with the heel, sole, and nail bed being the most commonly affected sites. Initially, melanoma of the sole appears as a brownish-black pigmented stain, which may or may not be related to a preexisting nevus.[14]

Acral-lentiginous melanoma has a very short *in situ* growth phase.[3] It usually has irregular borders and pigmentation on presentation. Nodular forms can supervene and rapidly metastasize. Cutaneous ulceration may occur with early invasion of neoplastic cells into the vessels and lymphatics of the dermis.[15]

At the palms, soles, and subungual areas, histologic examination of acral-lentiginous melanoma reveals lentiginous, or freckled, patterns at the dermal-epidermal junction. The epidermis is hyperplastic with rete ridge accentuations.[15] Acral-lentiginous melanoma has three tumor growth phases: the lentiginous phase, the radial phase or dysplastic precursor phase, and the vertical or nodular phase. The lentiginous phase is characterized by atypical melanocytic cells.[3]

In the radial phase, the cells are dysplastic and characterized by marked nuclear atypia with numerous mitotic figures. An immunologic response may occur during the radial phase with lymphocytic destruction of the atypical melanocytes. This process, termed regression, can last from months to years. Morphologically, evidence of regression is provided by the fibrosis and thickening of the papillary dermis.[14] One neoplastic cell lineage dominates the vertical growth phase. However, the radial and vertical phases may coexist. The vertical growth phase can feature two cell types, depending on the host's immune response: spindle cells indicate a poor immune response, and epithelioid cells represent a well-formed immune response and regression of tumor growth.[3]

Case Report

On January 6, 1999, an obese 58-year-old black woman presented to the Kern Hospital & Medical Center in Warren, Michigan, with an ulcerative, protuberant soft-tissue mass on the lateral aspect of her left heel. The patient had first noticed the lesion 4 months prior to presentation. There was a slight fullness to the area and she had developed a sore from scratching. The patient described the lesion as painful, and said that it had been increasing in size. She also stated that the mass had bled easily over the previous few days. She recalled no history of trauma.

The patient's medical history consisted of a tonsillectomy and adenoidectomy. Her current medications included amlodipine, nifedipine, propoxyphene, and cephalexin monohydrate. The patient had no known drug allergies. She had a family history of diabetes mellitus and stroke. She denied use of alcohol or tobacco. Physical examination revealed an obese woman (264 pounds; height, 5 feet 4 inches). Her blood pressure was 120/86 mm Hg, heart rate was 80 beats per minute, and respiration rate was 16 breaths per minute. A complete white blood cell count with differential, urinalysis, and electrocardiogram were ordered preoperatively. All laboratory values were within normal limits with the exception of the white blood cell count of $10.2 \times 10^3/\mu L$, and a mean corpuscular volume of 76 fL, consistent with microcytic anemia.

Clinically, the dermatologic examination revealed a 2×3-cm bulbous, purplish-red lesion on the lateral aspect of the left heel (Fig. 1). A moderate amount of malodorous yellow-green, serosanguineous exudate was present. The patient's neurovascular system was intact bilaterally. She had no biomechanical abnormality; her Achilles and patellar reflexes were normal and the musculoskeletal examination was unremarkable. No lymphadenopathy or lymphangitis was noted. Radiographs revealed soft-tissue swelling without bone involvement.



Figure 1. Lateral view of the patient's left foot at initial presentation depicting the lesion. Note the hyperplasia of the granulation tissue.

An excisional biopsy was performed. Intraoperatively, the lesion was noted to consist of protuberant granulation tissue extending 0.5 mm above the epidermis. The lesion had a hyperkeratotic rim and extended down to the periosteum of the calcaneus. The lesion was well demarcated and was easily freed from the surrounding soft tissue. Sharp and blunt dissection allowed the lesion to be extirpated *in toto* from the surgical site; it was sent for pathologic analysis. The hyperkeratotic rim superficially surrounding the lesion was also excised *in toto*, as was a 1-cm margin of normal tissue. The major factor influencing the surgical approach was the thickness of the lesion. Lesions less than 0.75 mm thick seldom metastasize and rarely recur after wide excision. Excision of a 2-cm margin, without elective lymph node dissection, has been suggested for such lesions. For lesions thicker than 0.75 mm, an excisional margin of 3 to 5 cm has been suggested.[11] The lesion in this patient was diagnosed as a stage III acral-lentiginous melanoma, Clark's level V (Figs. 2 and 3). The patient was referred for elective lymph node dissection of the popliteal region; the findings were positive for metastatic disease. The patient also underwent plastic surgery—wide excision with skin grafting—and chemotherapy with interferon. A computed tomographic scan of the chest, abdomen, and pelvis, with oral and intravenous contrast, demonstrated extensive metastatic disease of the lungs, liver, and spleen. The patient died 4 months after the initial surgical excision.

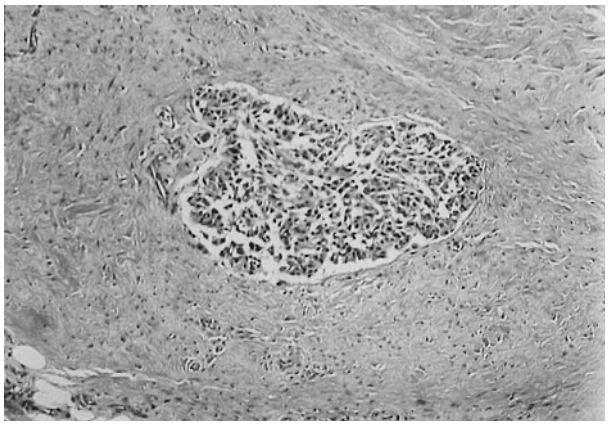

Figure 2. Photomicrograph demonstrating infiltration of the lesion into the subcutaneous tissue (H&E).

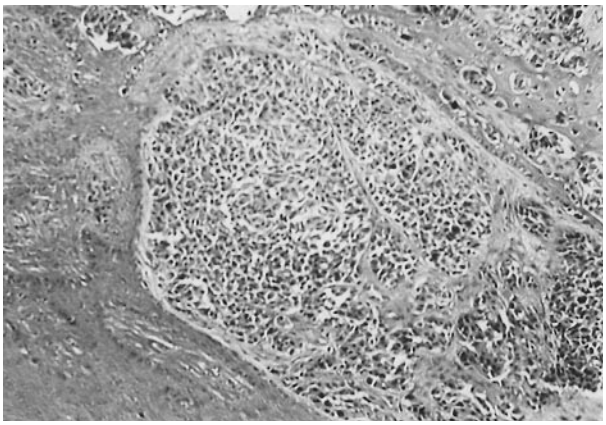

Figure 3. Photomicrograph demonstrating marked nuclear atypia with irregular nests of melanocytes (H&E).

Acral-lentiginous melanoma can have an abysmal prognosis depending on the thickness and size of the lesion. Early detection and surgical excision of the lesion will dramatically improve a patient's chance for survival. The podiatric physician can play an integral role in increasing the chance for survival in patients with acral-lentiginous melanoma through keen clinical observation and a high index of suspicion for this disorder. When such a lesion is detected, prompt excision and referrals to a plastic surgeon and an oncologist may considerably improve the prognosis.

PAUL E. GREGOLINE, DPM
STEVEN CLARK, DPM
STUART E. KIRSCHENBAUM, DPM
Kern Hospital & Medical Center
21230 Dequindre Rd
Warren, MI 48091

References

1. RIGEL DS, FREIDMAN RJ: "Benign and Malignant Tumors of Pigment-Producing Cells," in *Principles and Practice of Dermatology*, ed by WM Sams, PJ Lynch, p 243, Churchill Livingstone, New York, 1990.
2. CLARK WH, ELDER DE, VAN HORN M: The biologic forms of malignant melanoma. Hum Pathol **17:** 443, 1986.
3. REED RJ: "Neoplasms of the Skin," in *Principles and Practice of Surgical Pathology*, ed by SG Silverberg, Vol 1, p 230, Churchill Livingstone, New York, 1990.
4. BETTLEY FR, O'SHEA JA: The absorption of arsenic and its relation to carcinoma. Br J Dermatol **93:** 563, 1975.
5. BALCH CM, SOONG SJ, MIHM GW, ET AL: A comparison of prognostic factors and surgical results in 1786 patients with localized (Stage I) melanoma treated in Alabama, USA, and New South Wales, Australia. Ann Surg **196:** 677, 1982.
6. COSMAN B, HEDDLE SB, CRIKELAIN GF: The increasing incidence of melanoma. Plast Reconstr Surg **57:** 50, 1976.
7. CLARK WH, AINSWORTH AM, BERNARDINO EA, ET AL: The developmental biology of primary human malignant melanomas. Semin Oncol **2:** 83, 1975.
8. CLARK WH: The histogenesis and biological behavior of primary malignant melanomas of the skin. Cancer Res **29:** 705, 1969.
9. BRESLOW A: Thickness, cross-sectional areas and depth of invasion in the prognosis of cutaneous melanoma. Ann Surg **172:** 902, 1970.
10. DAY CL, LEW RA, MIHM M, ET AL: The natural breakpoints for primary tumor thickness in chemical stage I melanoma. N Engl J Med **305:** 1155, 1981.
11. DAY CL, MIHM MC, LEW RA, ET AL: Prognostic factors for patients with clinical stage I melanoma of intermediate thickness (1.51-3.39 mm): a conceptual model for tumor growth and metastasis. Ann Surg **195:** 35, 1982.
12. ROSES DF, HARRIS MN, ACKERMAN AB: "Clinical Evaluation of a Patient with a Malignant Melanoma," in *Diagnosis and Management of Cutaneous Malignant Melanoma*, ed by PA Ebert, p 121, WB Saunders, Philadelphia, 1983.
13. KEYHANI A: Comparison of clinical behavior of melanoma of the hands and feet: 283 patients. Cancer **40:** 3168, 1977.
14. CLARK WH: Clinical diagnosis of cutaneous malignant melanoma. JAMA **236:** 484, 1976.
15. ROSES DF, HARRIS MN, ACKERMAN AB: "Clinical and Histological Features in Malignant Melanoma," in *Diagnosis and Management of Cutaneous Malignant Melanoma*, ed by PA Ebert, p 3, WB Saunders, Philadelphia, 1983.

Additional References

ACKERMAN AB, DAVID KM: A unifying concept of malignant melanoma: biologic aspects. Hum Pathol **17:** 438, 1986.
BALCH CM, MURAD TM, SOONG S, ET AL: Tumor thickness as a guide to surgical management of clinical stage I melanoma patients. Cancer **43:** 883, 1979.

Bostwick J, Pendergast WJ, Vasconez LO: Marjolin's ulcer: an immunologically privileged tumor? Plast Reconstr Surg **57:** 66, 1976.

Brown SM, Freeman RG: Epithelioma cuniculatum. Arch Dermatol **112:** 1295, 1976.

Caro WA, Bronstein BR: "Tumors of the Skin," in *Dermatology*, ed by SL Moschella, HJ Hurley, Vol 2, p 1577, WB Saunders, Philadelphia, 1985.

Darnall TW, Mopper C: Eccrine poroma associated with Bowen's disease. Arch Dermatol **82:** 548, 1960.

Fine RM, Chernosky ME: Clinical recognition of clear cell acanthoma (Degos'). Arch Dermatol **100:** 559, 1969.

Sober AJ, Rhodes AR, Mihm MC: "Neoplasms: Malignant Melanoma," in *Dermatology in General Medicine*, 3rd Ed, ed by TB Fitzpatrick, AZ Eisen, K Wolff, et al, Vol 1, p 877, McGraw-Hill, New York, 1987.