Metastatic Breast Cancer Presenting as Heel Pain

M. JAY GROVES, DPM*
RICHARD G. STILES, MD†

The authors present a case of breast cancer metastasizing to the calcaneus that was confirmed by bone biopsy. The patient's complaint of heel pain provided the initial evidence of skeletal metastasis. Metastatic spread of cancer to the hand or foot (acrometastasis) is considered rare. However, the possibility of acrometastasis should be considered in any patient with a history of cancer presenting with skeletal pain, especially if the symptoms do not respond to therapy. (J Am Podiatr Med Assoc 88(8): 400-405, 1998)

One of the most common complications associated with carcinoma is skeletal metastasis. However, bony metastases occurring distal to the elbow and knee are unusual and dissemination of a primary tumor to the hand or foot (acrometastasis) is rare.[1] The purpose of this article is to report a case of biopsy-confirmed breast cancer that metastasized to the calcaneus and to review the literature on acrometastasis.

Metastatic cancer is the most common neoplasm of bone, more so than primary osseous lesions.[1, 2] The incidence of skeletal metastasis ranges from 16% to 73%, depending on the primary tumor type.[3-6] The primary malignancies responsible for bony metastases are cancers of the breast, lung, prostate, kidney, and gastrointestinal tract.[3] The most commonly affected bones are the vertebrae (69%), pelvis (41%), femur (25%), ribs (25%), and skull (14%).[5, 7]

The infrequency of distal skeletal metastasis was illustrated by Leeson et al.[1] They reviewed the hospital records of 827 cancer patients who underwent autopsy between 1948 and 1983. Metastatic involvement distal to the elbow and knee was confirmed by histopathologic examination in 7% (57 patients). The incidence of acrometastases was 0.6% (5 patients) to the hand and 1.7% (14 patients) to the foot.

*Submitted during second-year residency, Northlake Regional Medical Center, Tucker, GA. *Mailing address:* 4906 Highway 22, Park Place #4, Mandeville, LA 70471.

†Associate Professor, Department of Radiology, Emory University School of Medicine, Atlanta, GA.

Bloodgood[8] described the first case of metastatic spread to the osseous structures of the foot secondary to prostate cancer. Jacox and Tristan[9] reported the first case of breast cancer metastasizing to the foot in 1960. The calcaneus is the most common site for acrometastases to the foot. However, several other bones may be involved as well.[10]

In addition to bone, soft tissue may serve as the receptor site in distal extremities. Cohen and Buzdar[11] documented a case of metastatic breast carcinoma that presented as an acute hallux paronychia without radiographic change of the osseous structures.

In 1995, Freedman and Henderson[12] described a case similar to the one presented in this report. The diagnosis of breast cancer that spread to the skeletal system in both of these cases was made by evaluating heel pain. Both patients had biopsy-confirmed adenocarcinoma lesions involving the calcaneus. There were four main differences between the cases. In the case of Freedman and Henderson, the 47-year-old patient had recurrent breast cancer in the contralateral breast 9 years after the original tumor. She also had extraskeletal metastasis to her lung 6 months prior to the onset of heel pain. The left foot was the only skeletal region involved when skeletal metastasis was diagnosed by bone scan. The patient died quickly (3 months after the heel biopsy).

Interestingly, tumors originating superior to the diaphragm (head, neck, lung) tend to metastasize to the hand, whereas tumors inferior to the diaphragm

(uterine, renal, bladder, gastrointestinal) tend to involve the foot.[7, 11] Metastatic breast cancer demonstrates an equal affinity for the hand and foot.[11]

Breast cancer is one of the most common malignancies affecting women, surpassed only by skin cancer. Approximately 184,300 new diagnoses of breast cancer and 44,300 deaths were expected from this disease in 1996.[13, 14] The annual incidence of breast cancer in women is approximately 110 in 100,000.[13] However, this incidence increases with age, and approximately 77% of new diagnoses will be in women older than 50 years of age.[14, 15] The lifetime risk of developing breast cancer is 1:8, and the risk of fatal disease is 1:28.[14]

Carcinoma of the breast is a common cause of skeletal metastases, which have been reported to occur in 16% to 73% of patients with breast cancer.[3, 4, 6] Bony metastases usually occur several years after the initial diagnosis of malignancy. In one study, 3.2% of patients with metastatic disease had diagnoses of skeletal metastases concurrently with breast cancer.[16] Lombardi and Amadio[7] found that approximately 20% of acrometastatic lesions reported in the literature provided the initial evidence of visceral malignancy.

The reported prognosis for patients with acrometastatic lesions has been poor. Survival after diagnosis of metastatic spread to the foot has been reported by several authors to be less than 1 year.[1, 7, 8, 12, 17-19] Approximately 20% of these patients have survival beyond 2 years.[7] Critical evaluation of these reports reveals that 1) prior to 1960, the treatment was primarily observation[1]; 2) prognosis regarding cancer types and subtypes was not fully considered; and 3) at the time of acrometastatic diagnosis, the disease was often advanced so that prolonged survival was unlikely.

Breast cancer that spreads to the skeletal system exclusively is considered an indolent disease.[6] This population of patients represents a distinct subset associated with a remarkable response to treatment and increased survival. The 5-year survival rate for these patients has been documented as 33% after diagnosis of skeletal metastasis. In contrast, 13% were alive 5 years after extraskeletal metastatic diagnosis.[6] The most important prognostic factors associated with increased survival in patients with skeletal disease alone have been reported to be premenopausal status and an age of 50 years old or younger, and a disease-free period greater than 48 months from initial breast carcinoma diagnosis.[5]

Case Report

On December 21, 1994, a 58-year-old woman was referred by her primary-care physician for evaluation of progressive left heel pain. The patient had been walking 2 to 3 miles per day for several years, but had discontinued her walking following the onset of heel pain in November 1994. The pain was located at the plantar lateral foot and there were heightened symptoms in the morning and in the late evening. Another area of concern was the patient's left knee, which was sore and swollen. The referring physician had obtained pedal radiographs that were interpreted as negative, and he then prescribed flurbiprofen, which provided some relief of pain.

The patient's medical history was most remarkable for breast cancer previously treated with a right mastectomy in 1990, and previous cholecystectomy. She was taking levothyroxine for hypothyroidism, but had no other significant medical problems.

The lower-extremity examination revealed tenderness at the plantar central and lateral left heel with lesser symptoms at the sinus tarsi and subtalar joint regions. Hyperkeratosis was present at the medial left heel, and mild pes valgus was bilateral. Mild edema was present at the lateral ankle region. Radiographs were interpreted as normal (Fig. 1). The podiatric physician's initial diagnosis was plantar fasciitis and subtalar joint arthrosis of the left foot. Treatment included supportive strapping, 500 mg of nabumetone, and reevaluation 1 week later.

On December 29, 1994, the patient reported a 30% improvement in pain. However, she continued to experience pain and tenderness at the plantar lateral aspect of the left heel. An injection was administered to the plantar fascial insertion consisting of a mixture of local anesthetic with short- and long-acting steroids.

The patient missed subsequent appointments until February 9, 1995, when she reported some relief fol-



Figure 1. Lateral radiograph of the calcaneus shows no abnormality.

lowing the local injection. She had discontinued the nabumetone. She continued to complain of pain, and tenderness was present upon physical examination at the plantar heel laterally and along a portion of the peroneal tendons. The assessment now was that of continued inflammation at multiple sites. Treatment consisted of a below-the-knee immobilizer, an elastic compression brace, ice three times a day, 750 mg of salsalate, and reevaluation in 2 weeks.

On February 23, 1995, the patient reported continued pain without relief. Mild edema remained about the left hindfoot with acute pain at the sinus tarsi and along the peroneal tendons. This pain was accentuated with inversion and was consistent with acute subtalar joint arthrosis and peroneal tendinitis of the left foot. A local anesthetic and short-acting steroid mixture was injected about the peroneal tendons and sinus tarsi. Treatment consisted of 25 mg of indomethacin three times per day and continued immobilization. Blood was drawn for an arthritis profile, complete blood count, and blood chemistry profile. All laboratory reports were normal except alkaline phosphatase level, which was 198 IU/L.

Over the next few weeks, the patient's symptoms persisted and magnetic resonance imaging (MRI) and computed tomographic (CT) scans of the patient's left foot were obtained. The MRI examination performed on March 17, 1995, showed an abnormal area of replacement of normal fat signal in the lateral aspect of the calcaneus with apparent extension through the lateral wall of the calcaneus (Fig. 2). The MRI study was interpreted as a destructive lesion in the calcaneus and the differential diagnosis included osteomyelitis, septic arthritis, primary bone tumor, and metastatic disease. Discussions were held with the patient's oncologist, who thought that metastasis from the original cancer would be extremely unusual.

A CT scan showed a destructive mass involving the lateral aspect of the calcaneus, corresponding to the MRI study (Fig. 3). Compromise and expansion of the lateral calcaneal wall with destruction of the trabecular bone in the medullary space were noted. Because of the imaging findings, the differential diagnosis was narrowed to primary bone tumor or metastatic disease.

Because of the findings on MRI and CT, the patient underwent a calcaneal biopsy at Northlake Regional Medical Center in Tucker, Georgia, on March 20, 1995 (Fig. 4). The histopathologic examination revealed adenocarcinoma consistent with previously diagnosed adenocarcinoma metastatic to the left calcaneus (Fig. 5). The patient's postoperative course was uneventful. Additional staging workup, including CT scans of the abdomen and chest as well as a tech-

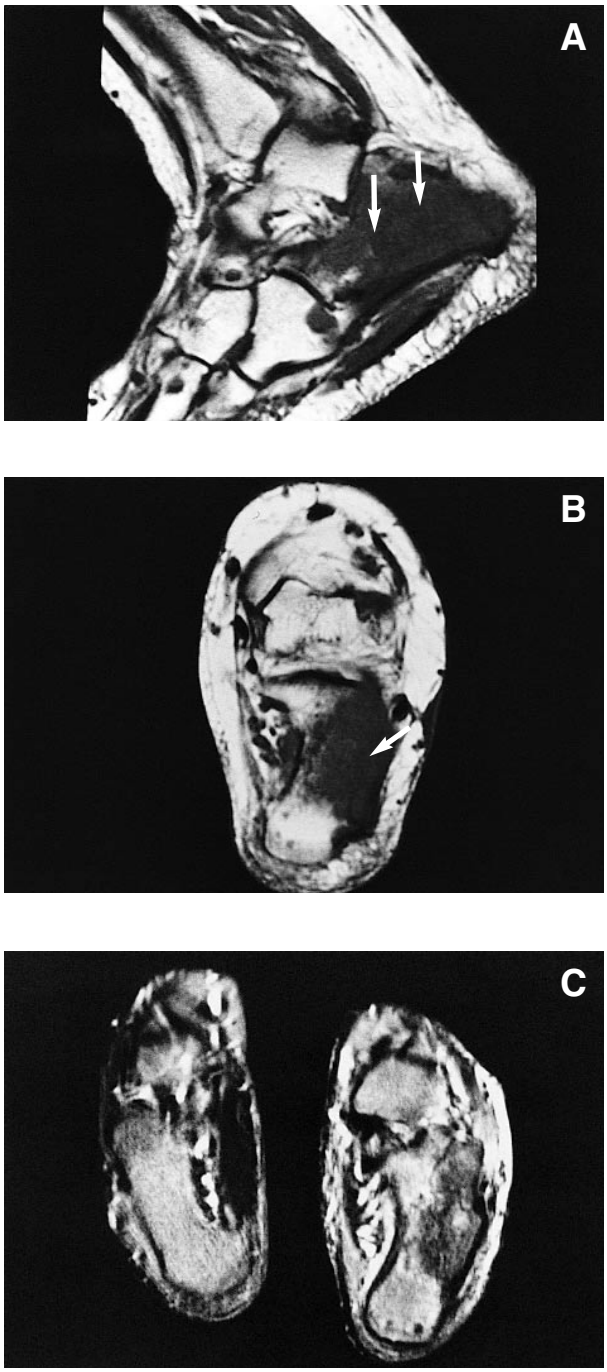

Figure 2. Magnetic resonance imaging scans of the calcaneus. A, Sagittal T1-weighted image of the left hindfoot shows low signal (dark) in the lateral aspect of the calcaneus (arrows). Small foci of low signal are also present in the cuboid, navicular, and fourth metatarsal. B, Axial (along the long axis of the calcaneus) T1-weighted image of the left calcaneus shows a low signal replacing the marrow fat (arrow). Marrow fat is usually of higher signal on T1-weighted images. C, Axial T2-weighted image of both feet shows a mixed bright and dark abnormal signal in the marrow fat of the left calcaneus at the site of a metastasis.

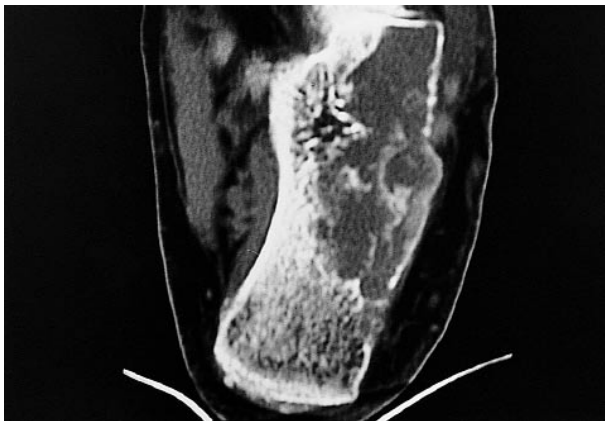

Figure 3. Computed tomographic scan of the left calcaneus, axial projection (long axis of the foot), shows a destructive lesion of the lateral aspect of the calcaneus with thinning and erosion of the lateral wall extending to the articular surface of the calcaneocuboid joint. There is destruction of the medullary trabecular bone.

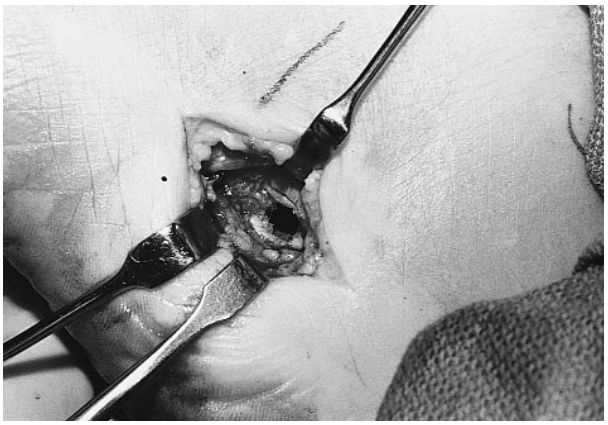

Figure 4. Operative view showing the core biopsy site through a lateral approach.

netium-99m bone scan, demonstrated metastatic disease confined to the skeletal system with involvement of the left calcaneus, left femoral condyles, and left 10th and 11th ribs.

Initially, the patient was treated with radiotherapy to local metastases to reduce pain and the risk of fracture. Under the direction of her oncologist, the patient was managed on chemotherapy from May 1995 through March 1996. Cyclophosphamide, methotrexate, and 5-fluorouracil (CMF) and salvage doxorubicin/vinblastine chemotherapy regimens were administered with a variable response and, ultimately, disease progression after 6 months of treatment. The patient was hospitalized in November 1995 for neutropenic fever. After discharge, the patient was started on paclitaxel salvage chemotherapy. Her cancer responded favorably to this regimen. At the completion of this therapy she was placed on tamoxifen. The oncologist anticipated a greater than 50% chance of 5-year survival, possibly extending to 10 years.

At a follow-up visit in May 1996, the patient remained partially weightbearing with a walker and below-the-knee immobilizer. She still experienced mild-to-moderate pain with inversion and with palpation at the lateral heel region. Stiffness of the digits and subtalar and ankle joints was also noted.

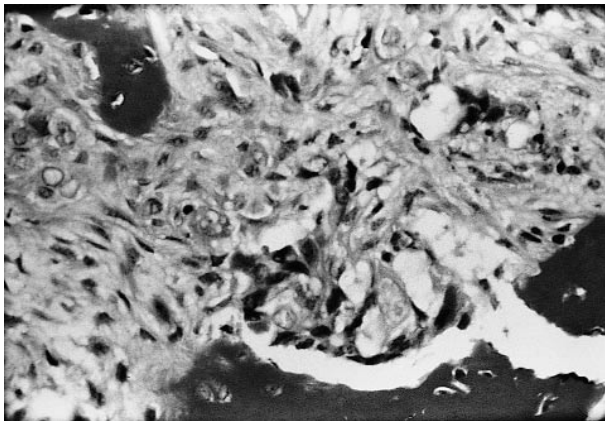

Figure 5. Photomicrograph showing histology consistent with adenocarcinoma secondary to breast carcinoma metastases.

Discussion

The diagnosis of skeletal metastasis requires a strong clinical suspicion with reliance on history, physical examination, laboratory reports, imaging, and ultimately biopsy for confirmation. Bone pain is the hallmark of cancerous spread to bone. Metastasis should always be considered in patients with pain and a history of (breast) cancer. The pain is usually insidious and nontraumatic; it may be clinically atypical and is usually unresponsive to traditional conservative measures.[8]

Imaging played a crucial role in clarifying the clinical problem for the patient presented here. Because of the patient's unrelenting symptoms despite a therapeutic regimen usually successful in the suspected

clinical diagnosis, an MRI study was requested. Magnetic resonance imaging is often useful for diagnosis in patients with recalcitrant foot pain. The MRI findings in this patient clearly showed an abnormality in the bone, thus directing attention away from the initial clinical diagnosis of plantar fasciitis and subtalar arthrosis. The MRI findings in the present case invoked a differential diagnosis of infection, tumor, or other space-occupying lesion of bone. Generally, the MRI findings in these situations are nonspecific and it is difficult to differentiate tumor from infection. However, some of the findings were more suggestive of tumor. Osteomyelitis and tumor generally show a low signal in the marrow space on T1-weighted images. It is beyond the scope of this article to fully explain MR pulse sequences. The important concept is that fat is bright (has a high signal) on T1-weighted images. Pathologic infiltration or replacement of the normal marrow fat has a dark signal on T1-weighted images. This dark signal pattern is nonspecific and may be from edema, infection, or tumor. However, edema and infection tend to have less well defined margins, whereas tumors may appear more rounded. However, this is not a reliable characteristic to differentiate tumor from infection.

On T2-weighted images, edema and infection tend to show brighter or higher signal than the normal marrow fat because of increased water content. Tumors are usually of high signal on T2-weighted images, but not necessarily so. The patient presented here is illustrative, showing mostly dark signal on the T2-weighted images. This would tend to argue against infection but is not specific. It is important to note that metastases may become isointense with surrounding fat on T2-weighted images and thus become imperceptible. Therefore, T1-weighted images are more sensitive for detection of metastases than T2-weighted images. This seems counterintuitive, as pathologic tissue tends to become very bright on T2-weighted images. However, the loss of sensitivity on T2-weighted images is due to those instances in which the metastatic focus becomes isointense with fat.[20] Recently, fat-suppression techniques have been used in the detection of metastases. By reducing the signal intensity from normal marrow fat, this technique may improve the visibility of metastases on T2-weighted images.

The CT scan was also helpful in this patient and allowed for a better appreciation of the bony destruction caused by this lesion. In general, CT is most helpful when bone structures need to be evaluated, and MRI is most helpful when soft-tissue structures need to be evaluated. The MRI technique provides the greatest soft-tissue contrast. Computed tomography allows excellent visualization of bone in cross-section, especially in areas of complex bony anatomy, such as the hindfoot (as in this case) or pelvis. The initial normal radiographs of this patient attest to the difficulty in seeing bone destruction in a bone such as the calcaneus where there is a high volume of trabecular bone. Much trabecular bone must be destroyed for it to become visible on standard radiographs. It is certainly possible that radiographs taken at the time of the MRI or CT study have become positive at that time. However, the cross-sectional studies still would have been required to fully characterize this lesion.

Summary

The patient reported in this case was a postmenopausal woman with heel pain and a medical history positive for infiltrating ductal breast cancer without nodal involvement. The patient had had a modified radical mastectomy of the right breast with lymph biopsy 54 months before the development of heel pain. The negative x-rays in December 1994 suggested soft-tissue injury with a presumptive diagnosis of plantar fasciitis. The chronic heel pain was not relieved by conservative measures and became increasingly atypical with involvement of the lateral calcaneal border, sinus tarsi, and peroneal tendons. Fortunately, metastatic disease was diagnosed early and timely treatment initiated.

There must be a strong clinical suspicion when evaluating bone pain in patients with a history of cancer. However, bony metastasis may be present at the time of initial visceral cancer diagnosis.[16] Atypical pain that is unresponsive to conservative treatment should increase suspicion. Special imaging studies are often indicated, as radiographic examination may be negative. Biopsy provides definitive diagnosis. An integrated team approach with medical, surgical, and psychosocial support provides the most favorable outcome.

Acknowledgment. Alan Banks, DPM, for his assistance and providing this case study.

References

1. Leeson MC, Makley JT, Carter JR: Metastatic skeletal disease distal to the elbow and knee. Clin Orthop **206:** 94, 1986.
2. Malawer MM, Delaney TF: "Treatment of Metastatic Cancer to Bone," in *Cancer: Principles and Practice of Oncology*, 4th Ed, ed by VT DeVita Jr, S Hellman, SA Rosenberg, p 2225, JB Lippincott, Philadelphia, 1993.
3. Abrams HL, Spiro R, Goldstein N: Metastases in carcinoma: analysis of 1000 autopsied cases. Cancer **3:** 74,

1950.
4. CLAIN A: Secondary malignant disease of bone. Br J Cancer **19:** 15, 1965.
5. SILVERBERG E, LUBERA J: Cancer statistics, 1987. CA Cancer J Clin **37:** 2, 1987.
6. SHERRY MM, GRECO FA, JOHNSON DH, ET AL: Metastatic breast cancer confined to the skeletal system: an indolent disease. Am J Med **81:** 381, 1986.
7. LOMBARDI RM, AMADIO P: "Acrometastases," in *Diagnosis and Management of Metastatic Bone Disease*, ed by FH Sim, p 237, Raven Press, New York, 1988.
8. BLOODGOOD JC: Bone tumors. Benign and malignant. A brief review of the salient features, based on a study of some 370 cases. Am J Surg **16:** 387, 1920.
9. JACOX RF, TRISTAN TA: Carcinoma of the breast metastatic to the bones of the foot: a case report. Arthritis Rheum **3:** 170, 1960.
10. LISBON E, BLOOM RA, HUSBAND JE, ET AL: Metastatic tumors of the hand and foot. Skeletal Radiol **16:** 387, 1987.
11. COHEN PR, BUZDAR AU: Metastatic breast carcinoma mimicking an acute paronychia of the great toe: case report and review of subungual metastases. Am J Clin Oncol **16:** 86, 1993.
12. FREEDMAN DM, HENDERSON RC: Metastatic breast carcinoma to the os calcis presenting as heel pain. South Med J **88:** 232, 1995.
13. AMERICAN CANCER SOCIETY: *Cancer Facts and Figures—1996*, American Cancer Society, Atlanta, 1996.
14. AMERICAN CANCER SOCIETY: *Breast Cancer Facts and Figures—1996*, American Cancer Society, Atlanta, 1995.
15. KOSARY CL, RIES LAG, MILLER BA, ET AL: *SEER Cancer Statistics Review, 1973-1992: Tables and Graphs*, NIH Publication No. 95-2789, National Cancer Institute, Bethesda, MD, 1995.
16. SHERRY MM, GRECO FA, JOHNSON DH, ET AL: Breast cancer with skeletal metastases at initial diagnosis: distinctive clinical characteristics and favorable prognosis. Cancer **58:** 178, 1986.
17. BLOOM RA, SULKES A, FREILICK G, ET AL: Breast metastases to bones of the extremities: simultaneous involvement of all four limbs. Clin Oncol (R Coll Radiol) **4:** 58, 1992.
18. WU KK, GUISE ER: Metastatic tumors of the hand: a report of six cases. J Hand Surg **3:** 271, 1978.
19. ZINDRICK MR, YOUNG MP, DALEY RJ, ET AL: Metastatic tumors of the foot: case report and literature review. Clin Orthop **170:** 219, 1982.
20. DAFFNER RH, LUPETIN AR, DASH N, ET AL: MRI in the detection of malignant infiltration of bone marrow. AJR Am J Roentgenol **146:** 353, 1986.

Additional References

GOLDMAN FD, DAYTON PD, HANSON CJ: Renal cell carcinoma and osseous metastases: case report and literature review. JAPMA **79:** 618, 1989.

JANIS LR, FELDMAN EP: Metastatic adenocarcinoma of the calcaneus: case report. J Foot Surg **15:** 28, 1976.

WU KK: Metastatic lesion of the foot. J Foot Surg **26:** 164, 1987.