Closed Rupture of the Anterior Tibial Tendon

A Case Report

ROBERT R. MILLER, DPM*
KIERAN T. MAHAN, DPM†

Closed subcutaneous rupture of the anterior tibial tendon is a relatively uncommon injury that requires a thorough clinical examination to diagnose correctly. The authors report a case of this disorder and provide a review of the relevant literature. A method of surgical repair not previously described in the literature is also presented. (J Am Podiatr Med Assoc 88(8): 394-399, 1998)

Tendon injuries are much less common than ligament strains and fractures.[1] The sudden application of a stretching force to a muscle that is contracting is the most common mechanism causing a tendon to rupture. McMaster[2] isolated rabbit femur–gastrocnemius–os calcis preparations and applied tensile force to the point of rupture. He noted that failure occurred at all sites except within the tendon. The important observation made was that normal tendon does not fail when subjected to severe strain.[2-4] However, a tendon showing pathologic changes may rupture following even slight trauma.[5, 6] McMaster[2] also tested specimens after an area of the Achilles tendon had been rendered ischemic by circumferential ligatures applied weeks before testing. The specimens failed between the ligatures, suggesting that ischemia had weakened the tendon.

Factors that predispose a tendon to rupture were described by Gilcreest[7] and include senility, fatigue, laceration, and pathologic conditions such as arthritis and myositis. Other factors include repeated stress or low-level injury, hypovascular zones, tendinitis, tenosynovitis, tendon calcifications, local anatomic conditions that promote ischemia and/or exaggerate local pressure, infection, collagen vascular diseases, and corticosteroid use.[3, 4, 8] Tendon ruptures have also been described in patients with systemic lupus erythematosus treated with steroid therapy,[9] chronic acidosis due to chronic lead nephropathy,[10] hyperparathyroidism,[11] and chronic renal failure with secondary hyperparathyroidism.[12]

Disruption of the anterior tibial tendon is an infrequent injury, usually the result of an open wound or laceration.[4] Most authors agree that acute closed subcutaneous rupture of the anterior tibial tendon is rare.[3, 5, 8, 13, 14] Hume[3] states that the straight course and minimal mechanical demands of the anterior tibial tendon are consistent with its rare involvement in rupture or inflammation. When rupture does occur, it generally involves older patients and symptoms may mimic radiculopathy with footdrop.[1, 3-5, 15] The presence of active function in other muscles innervated by the deep and superficial branches of the common peroneal nerve would ordinarily preclude the possibility of a peripheral neuropathy based on an ischemic process.[15] Electrodiagnostic evaluation would confirm it when necessary. Scheller et al[1] state that the injury athletes sustain from acute stress applied by the anterior tibial tendon is an avulsion fracture of the navicular bone,[1] although a fracture of the medial

*Submitted during fourth-year residency, University of Pennsylvania Health System/Presbyterian Medical Center, Philadelphia, PA.

†Diplomate, American Board of Podiatric Surgery; Fellow, American College of Foot and Ankle Surgeons; faculty member, The Podiatry Institute, Tucker, GA; Associate Dean for Academic Affairs and Professor, Department of Podiatric Surgery, Temple University School of Podiatric Medicine, Eighth at Race St, Philadelphia, PA 19107.

cuneiform seems more likely. A careful examination of the distal leg followed by gait observation should enable the physician to make the clinical diagnosis.

Bruning[14] was the first to describe acute closed subcutaneous rupture of the anterior tibial tendon. Since his original description, only 36 other cases have been reported in the literature (Table 1). Because relatively few cases have been reported, there is a general lack of awareness of the condition, and late diagnosis is common.

Anatomy

The muscles of the anterior compartment of the leg act primarily during the swing and early stance phases. This action allows the foot to clear the ground during the swing phase and then be placed gently on the ground after heel strike. The tibialis anterior muscle originates from the lateral tibial condyle and the proximal half or two-thirds of the lateral tibial shaft, anterior interosseous membrane, fascia cruris, and intermuscular septum between the muscle and extensor digitorum longus.[26] It descends vertically to a tendon in the distal third of the leg, traverses the superior and inferior extensor retinaculum, and is attached to the medial and inferior surfaces of the medial cuneiform and adjacent first metatarsal base.[26, 27] All of the anterior crural muscles are innervated by the deep peroneal nerve.

Clinical Evaluation

According to the literature, the symptoms of anterior tibial tendon rupture can be quite variable. Some patients are unable to recall any incident of trauma, whereas others relate a specific injury. Most patients who recall the injury relate a mechanism of forced plantarflexion. These patients may also relate experiencing a sharp pain in the foot or ankle and/or a snapping sensation in the upper part of the arch. Pain and weakness seem to be maximal within the first few hours of injury, often making ambulation difficult or impossible, but frequently become minimal or temporary, leaving the patient with a painless, flat-footed gait. The most common symptoms include an abnormal gait characterized by a variable degree of foot slap or tendency to stub the toes, generalized foot weakness and/or pain, and difficulty walking on the heels.

Complete rupture of the anterior tibial tendon is often marked by a palpable tendon defect and sometimes a visual depression in the skin at a point between the annular ligament and insertion of the tendon. Anterior tibial tendon ruptures usually occur 1 to 3 cm proximal to the insertion, with the proximal stump retracting and forming a bulbous enlargement above the anteromedial ankle.[5, 15, 17-19, 28]

With acute or recent injury, ecchymosis, edema, and tenderness are noted over the site of rupture. Generally, active dorsiflexion cannot be carried out past the ankle and subtalar joints neutral position. Resistive muscle testing reveals an inability to resist modest forces. Gait analysis reveals a variable degree of footdrop or a steppage-type gait. Pain is often minimal and temporary,[16, 18, 20] resulting in a delay between the time of injury and initial clinical presentation.[13, 25, 29]

In chronic cases signs may be subtle. The active range of motion of the ankle joint may be decreased by 10° to 15° from normal,[5] with a variable degree of footdrop. Chronic cases may also cause a feeling of ankle instability and weakness[4, 5] and an abnormal, painless, flat-footed, slapping gait.

Case Presentation

A 70-year-old woman presented to the Foot and Ankle Institute at the Pennsylvania College of Podiatric Medicine on September 29, 1993, with a chief complaint of pain in the top part of the arch of her right foot. The previous night she had experienced a "knife-like" pain and a "popping sensation" in her arch while pushing off of the right foot while getting into bed. Her history was complicated by a previous injury to the right foot that occurred 1 year earlier (while attempting to run across the street, she experienced a severe "stabbing sensation" in her arch). After the initial injury she noted difficulty ascending and descending stairs and sensitivity in her arch, but these symptoms shortly resolved without treatment.

Her medical history was significant for osteoarthritis, restless leg syndrome, and a hysterectomy in 1966. Her medications included carbidopa-levodopa and piroxicam. A penicillin allergy was noted. Her social history was unremarkable.

During examination of the right lower extremity, a palpable defect along with point tenderness was noted near the insertion of the anterior tibial tendon. Weakness and pain were noted with attempted ankle dorsiflexion and inversion. A moderate amount of localized edema was present in the arch. A diagnosis of acute subcutaneous rupture of the anterior tibial tendon was made.

On October 4, 1993, the patient was taken to the operating room at the Presbyterian Medical Center for exploration of the anterior tibial tendon. An incision was made over the dorsomedial aspect of the arch along the course of the anterior tibial tendon. It was noted that the tendon had ruptured just proximal

Table 1. Reported Cases of Anterior Tibial Tendon Rupture

Author(s)	Age	Sex	Injury	Treatment
Bruning,[14] 1905	45	M	Fell skiing	Operative (primary repair)
Els, 1910	25	M	Violent trauma	Nonoperative (orthotic)
Burman,[16] 1934	69	M	No obvious trauma (auto ran over foot 1 year previously)	Nonoperative (casted)
	48	M	Kicked an object	Operative (primary repair)
Lapidus,[17] 1941	46	M	Sprained ankle	Operative (anterior tibial tendon free graft)
	46	M	Fell down stairs	Operative (free tendon graft from extensor digitorum longus to fifth toe)
Moberg,[18] 1947	46	M	No obvious trauma (trauma 8 years prior to injury)	Nonoperative (casted)
	50	M	No obvious trauma (trauma 7 and 4 weeks prior to injury)	Nonoperative (casted)
	46	M	Caught heel on staircase and fell	Operative (primary repair)
	62	M	Fell going down stairs	Operative (primary repair)
Mensor and Ordway,[5] 1953	59	M	Fell backward with foot caught in a pipe	Operative (tendon sutured to navicular with steel)
	59	M	Fell down stairs	Operative (primary repair)
Moskowitz,[15] 1971	69	M	Tripped over a stone	Nonoperative (orthotic)
	70	M	Tripped over a door saddle	Nonoperative (not specified)
Meyn,[4] 1975	69	M	Tendon ruptured during examination	Operative (primary repair)
Dooley et al,[19] 1980	45	F	2-year history of prior trauma	Nonoperative (treatment not recommended)
	67	M	Tripped over a steel girder	Operative (proximal slide tendon lengthening; distal end of tendon sutured to periosteum of medial cuneiform)
	64	M	Tripped and fell	Operative (anterior tibial tendon sutured to extensor hallucis longus; extensor hallucis longus sutured to posterior tibial tendon insertion)
	67	M	Tripped	Operative (anterior tibial tendon sutured into drill hole in medial cuneiform and sutured over a button on the plantar aspect of the foot)
Kashyap and Prince,[20] 1987	65	M	Insidious onset	Operative (proximal slide tendon lengthening with primary repair of tendon ends)
Benzakein et al,[21] 1988	57	M	No obvious trauma	Nonoperative
Rimoldi et al,[13] 1991	51	M	Misjudged step coming off elevator	Operative (primary repair)
Barnett and Hammond,[22] 1991	84	M	Slipped in bathroom	Operative
Stuart,[23] 1992	72	M	Tip of cross-country ski caught in snow	Operative (proximal tendon sutured into drill holes in medial cuneiform and first metatarsal)
Bernstein,[24] 1995	68	M	Playing tennis	Nonoperative (strengthening exercises)
Ouzounian and Anderson,[25] 1995	73	M	Brisk walking	Nonoperative (ankle-foot orthosis)
	65	M	Ankle sprain	Nonoperative (ankle-foot orthosis)
	67	M	Acute myoclonus	Operative (proximal tendon lengthened and reattached to bone)
	69	M	Contusion of anterior ankle	Operative (extensor hallucis longus transfer)
	18	M	Contusion of anterior ankle	Operative (extensor hallucis longus transfer; proximal slide lengthening of anterior tibial tendon)
	83	F	No obvious trauma	Nonoperative (ankle-foot orthosis)
	69	F	No obvious trauma	Nonoperative (ankle-foot orthosis)
	62	M	Brisk walking	Operative (primary repair)
	63	M	Arose from chair	Operative (tendon reinserted into navicular)
	37	M	Log fell on foot	Operative (extensor digitorum longus interposition graft)
	74	F	No obvious trauma	Nonoperative (ankle-foot orthosis)
	51	M	Running	Operative (extensor digitorum longus interposition graft)

to its insertion, and it was found to be hemorrhagic and inflamed (Fig. 1). The ruptured portion of the tendon was then resected (Fig. 2) and sent for pathologic examination. The anterior portion of the tendon was split longitudinally in the frontal plane, and it was turned down and advanced distally (Fig. 3). The medial cuneiform was identified and sharply dissected of periosteal and capsular tissue on the medial aspect. A Mitek Quickanchor®[1] bone-anchoring system was then placed into the medial aspect of the medial cuneiform, and the anchor was used to suture the tendon back to its insertion (Fig. 4). The repair was reinforced with 2-0 polyglactin 910 suture. The proximal portion of the tendon was reinforced with 2-0 polyglactin 910 suture (Fig. 5). The deep fascia, superficial fascia, and skin were then closed in the usual fashion and a short leg cast was applied.

The patient remained nonweightbearing in the cast for 6 weeks and had protected weightbearing ambulation for an additional 2 weeks. One year after surgery, she had full normal strength of the tibialis anterior, with no deficits noted during clinical gait analysis. She had no pain, swelling, or other symptoms at the surgical site or elsewhere.

[1] ® Mitek Surgical Products, Inc, Norwood, MA.

Discussion

A review of the literature reveals several recurrent themes with respect to rupture of the anterior tibial



Figure 1. Tendon rupture with edema and hemorrhage.

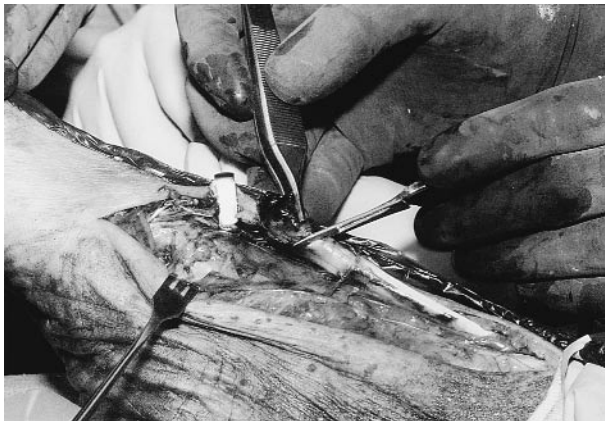

Figure 2. Resection of ruptured portion of the tendon.

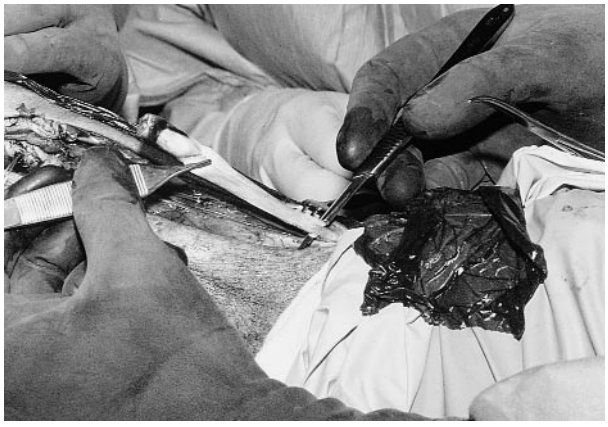

Figure 3. Longitudinal sectioning of the tendon in the frontal plane to prepare for distal turndown and advancement.



Figure 4. Placement of Mitek bone anchor to secure attachment of the anterior tibial tendon to the medial cuneiform.



Figure 5. Final result with tendon reattached to the medial cuneiform and repair oversewn.

tendon. Nearly 80% of the cases occurred between the fourth and sixth decades, with over half of these cases occurring in the sixth decade of life. Kannus and Józsa[6] noted that degenerative changes in tendons may be common in people older than 35 years, and it seems likely that these changes predispose to spontaneous rupture. Several authors have described both gross and histologic findings after repairing anterior tibial tendon ruptures that seemed consistent with prior tendon pathology.[5, 14, 17-19] Microscopic evaluation of the tendon in the presented patient revealed interstitial hemorrhage and vascular ectasia.

The most common mechanism of injury associated with anterior tibial tendon rupture is a fall resulting in a plantarflexion injury to the foot,[5, 13, 14, 17-19] although several authors have described this condition with a history of minimal or no trauma.[4, 15, 18-21, 25] This was supported by Ouzounian and Anderson,[25] who stated that there are two distinctly different clinical presentations of anterior tibial tendon rupture: the first is the atraumatic presentation in low-functioning elderly patients; the second is a traumatic presentation in elderly patients whose functional level is generally higher, but in which the severity of the traumatic event is minimal.[25]

Of all cases of anterior tibial tendon rupture reported, only 10% involved female patients. Similar data exist with respect to rupture of the Achilles tendon. The possibility of a protective effect of estrogen levels in females has been addressed.[24]

As with the posterior tibial and Achilles tendons, the existence of a hypovascular zone has been proposed. This theory was disproved after examination of 12 fresh-frozen cadaveric specimens revealed no hypovascular zones at the common site of rupture, 1 to 3 cm proximal to the site of insertion.[30]

Treatment of anterior tibial tendon ruptures is controversial. Most authors agree that operative repair of acute ruptures is the optimal method of treatment, although several different procedures have been described. Immediate surgical repair seems to improve the prospects for a rapid and effective full recovery, especially in the active patient.[18, 24] Surgical repair of the tendon generally precedes 4 to 6 weeks of casting and rehabilitation for tendon strengthening.

Four basic methods for the surgical repair of anterior tibial tendon ruptures have been described (Table 2). Primary repair (end-to-end reapproximation) of tendons is generally reserved for acute injuries. Cases that display evidence of marked pathology of the tendon or evidence of chronic rupture may not be amenable to primary repair. Since many of these injuries occur near the insertion of the tendon, primary repair may not be possible.

Reattachment of the proximal portion of the tendon may be accomplished through several different methods (screws with polyacetyl washers, bone anchors, drill holes with suture reattachment, or suturing the tendon into periosteum).

Interpositional tendon grafts and tendon transfers are used for cases in which the tendon is substantially shortened or the tendon interface reveals severe pathologic degeneration. These methods may require the sacrifice of other tendons, with potential loss of function of that tendon or deformity.

Finally, the proximal intact portion of the tendon can be lengthened and reinserted into a new site.

Nonoperative treatment is generally reserved for older, less active patients who may not be good candidates for surgery. The results of nonoperative treatment are difficult to analyze. There are no criteria described by authors to determine what constitutes a good or bad result. Most reports appear to confirm that some degree of abnormality persists after conservative treatment, such as the following: foot slap; difficulty with ambulation on uneven surfaces; mild, intermittent pain; late ankle strain; and difficulties

Table 2. Surgical Methods of Repairing Anterior Tibial Tendon Ruptures

Primary repair (end-to-end anastomosis)
Proximal tendon reinsertion
Proximal tendon lengthening and reattachment
Interpositional tendon grafting or tendon transfers

with activities of daily living.[14, 15, 23, 25] Although clinical abnormalities may be present, not all patients had subjective complaints.[15, 24] It does seem that most patients benefit from the use of bracing (ie, ankle-foot orthoses) or orthoses if conservative treatment is required for this injury.[16, 25]

The treatment of chronic rupture is even more controversial. Ouzounian and Anderson[25] noted that atraumatic ruptures with late clinical presentation may respond to bracing. Nonoperative treatment is frequently satisfactory, but some untreated patients develop mild intermittent pain and pes planus.[16] Rimoldi et al[13] also noted that treatment of the chronic lesion is controversial because surgical repair is more apt to yield unpredictable results.

Conclusion

Although rupture of the anterior tibial tendon is a rare injury, it can be disabling in the active patient. Accurate diagnosis requires a high index of suspicion for this injury along with a thorough clinical examination. Aggressive treatment of prodromal stages with orthoses or braces may prevent tendon rupture. Surgical repair of acute injuries seems to provide satisfactory results in active, healthy patients. Treatment of the chronic or neglected rupture remains controversial.

References

1. Scheller AD, Kasser JR, Quigley TB: Tendon injuries about the ankle. Orthop Clin North Am **2:** 809, 1980.
2. McMaster PE: Tendon and muscle ruptures. J Bone Joint Surg Br **15:** 705, 1933.
3. Hume EL: "Overuse Syndromes," in *Traumatic Disorders of the Ankle*, ed by WC Hamilton, p 55, Springer-Verlag, New York, 1984.
4. Meyn MA: Closed rupture of the anterior tibial tendon. Clin Orthop **113:** 154, 1975.
5. Mensor MC, Ordway GL: Traumatic subcutaneous rupture of the tibialis anterior tendon. J Bone Joint Surg Am **35:** 675, 1953.
6. Kannus P, Józsa L: Histopathologic changes preceding spontaneous rupture of a tendon. J Bone Joint Surg Am **73:** 1507, 1991.
7. Gilcreest EL: Ruptures and tears of muscles and tendons of the lower extremity: report of fifteen cases. JAMA **100:** 153, 1933.
8. Sheinberg R, Bayne O: "General Concepts in the Management of Tendon Trauma to the Foot and Ankle," in *Foot and Ankle Trauma*, ed by BL Scurran, p 167, Churchill Livingstone, New York, 1989.
9. Wener JA, Schein AJ: Simultaneous bilateral rupture of the patellar tendon and quadriceps expansions in systemic lupus erythematosus. J Bone Joint Surg Am **56:** 823, 1974.
10. Murphy KJ, McPhee I: Tears of major tendons in chronic acidosis with elastosis. J Bone Joint Surg Am **57:** 823, 1974.
11. Preston FS, Adicoff A: Hyperparathyroidism with avulsion of three major tendons: report of a case. N Engl J Med **266:** 968, 1962.
12. Cirincione RJ, Baker BE: Tendon ruptures with secondary hyperparathyroidism. J Bone Joint Surg Am **57:** 852, 1975.
13. Rimoldi RL, Oberlander MA, Waldrop JI, et al: Acute rupture of the tibialis anterior tendon: a case report. Foot Ankle **12:** 176, 1991.
14. Bruning E: Zwei Seltene Fälle von Subkutaner Sehnenzerreißung. Munchen Med Wchnschr **52:** 1928, 1905.
15. Moskowitz E: Rupture of the anterior tibial tendon simulating peroneal nerve palsy. Arch Phys Med Rehabil **52:** 431, 1971.
16. Burman MS: Subcutaneous rupture of the tendon of the tibialis anticus. Ann Surg **100:** 368, 1934.
17. Lapidus PW: Indirect subcutaneous rupture of the anterior tibial tendon: report of two cases. Bull Hosp Joint Dis **2:** 119, 1941.
18. Moberg E: Subcutaneous rupture of the tibialis anterior muscle. Acta Chir Scand **95:** 455, 1947.
19. Dooley BJ, Kudelka P, Menelaus MB: Subcutaneous rupture of the tibialis anterior tendon. J Bone Joint Surg Br **62:** 471, 1980.
20. Kashyap S, Prince R: Spontaneous rupture of the tibialis anterior tendon: a case report. Clin Orthop **216:** 159, 1987.
21. Benzakein R, Wakim WA, DeLauro TM, et al: Neglected rupture of the tibialis anterior tendon. JAPMA **78:** 529, 1988.
22. Barnett T, Hammond NL III: Anterior tibial tendon rupture. Contemp Orthop **23:** 365, 1991.
23. Stuart MJ: Traumatic disruption of the anterior tibial tendon while cross-country skiing: a case report. Clin Orthop **281:** 193, 1992.
24. Bernstein RM: Spontaneous rupture of the tibialis anterior tendon. Am J Orthop **24:** 354, 1995.
25. Ouzounian TJ, Anderson R: Anterior tibial tendon rupture. Foot Ankle **16:** 406, 1995.
26. Gray H: "Myology," in *Gray's Anatomy*, 37th Ed, ed by PL Williams, R Warwick, M Dyson, et al, p 545, Churchill Livingstone, New York, 1989.
27. Sarrafian SK: "Myology," in *Anatomy of the Foot and Ankle: Descriptive, Topographic, Functional*, p 218, JB Lippincott, Philadelphia, 1983.
28. Silvani S: "Management of Acute Tendon Trauma," in *Comprehensive Textbook of Foot Surgery*, Vol 2, 2nd Ed, ed by ED McGlamry, AS Banks, MS Downey, p 1450, Williams & Wilkins, Baltimore, 1992.
29. Elstrom JA, Pankovich AM: "Muscle and Tendon Surgery of the Leg," in *Surgery of the Musculoskeletal System*, Vol 4, 2nd Ed, ed by CM Evarts, p 171, Churchill Livingstone, New York, 1990.
30. Geppert MJ, Sobel M, Hannafin JA: Microvasculature of the tibialis anterior tendon. Foot Ankle **14:** 261, 1993.