Magnetic Resonance Imaging of Ankle Ligament Injuries Correlated with Time

JONATHAN M. LABOVITZ, DPM*
MARK E. SCHWEITZER, MD†
ULLA-BRITT LARKA, DPM‡
MARSHALL G. SOLOMON, DPM§

Ankle sprain is one of the most commonly treated injuries of the lower extremity. The treatment depends on the severity of the injury and the time at which it occurred. The physician must rely on the history as related by the patient to determine the age of the injury. Magnetic resonance imaging has been proven to help determine the severity of the injury but has not been used to determine the age of the injury. The present study was conducted to identify the typical findings of acute and chronic ankle sprains as a means of dating an ankle sprain based on its appearance on magnetic resonance imaging. (J Am Podiatr Med Assoc 88(8): 387-393, 1998)

Ankle sprain is one of the most common injuries encountered in the practice of foot and ankle medicine. In cases of ankle sprain, the patient is not always able to relate the time of injury. This can be troublesome, as treatment is partially dependent on when the insult occurred. An acute sprain is usually treated with early mobilization alone, early mobilization following a short period of partial or total immobilization, or surgical correction. A chronic injury is treated somewhat differently: It is frequently treated with proprioception and functional physical therapy, with or without bracing, but may undergo surgical correction.

Clinical assessment of a patient to determine the treatment of choice can be broken down into three stages: 1) making the diagnosis, 2) gauging the severity of the complaint, and 3) dating the injury. Magnetic resonance imaging (MRI) has assisted in the first and second stages by enabling the clinician to visualize the ankle sprain and to determine the extent of the injury; this has helped direct the clinician to the proper treatment. This diagnostic study, however, is best reserved for patients with inconclusive clinical examination and stress radiograph findings. Magnetic resonance imaging may also be used to evaluate the extent of the injury in competitive athletes undergoing immediate surgical repair.[1] Magnetic resonance imaging has not yet been used to help the treating physician by determining the third main influence on the treatment of choice, the age of the injury. The authors have attempted to identify the characteristic findings of acute, subacute, and remote ankle ligament injuries on the basis of their appearance on MRI.

Materials and Methods

One hundred nine MRI studies of 108 subjects over a 5-year period were reviewed retrospectively. All patients had known ligamentous injuries of the ankle. One patient underwent imaging of both ankles. Of the 108 subjects, 51 were male and 57 were female.

*Submitted during first-year residency, Department of Podiatry, Botsford General Hospital, 28050 Grand River, Farmington Hills, MI 48336-5933.

†Fellow, American College of Radiology; Professor of Radiology and Orthopedic Surgery, Thomas Jefferson University, Philadelphia, PA.

‡Submitted during fourth year, Temple University School of Podiatric Medicine, Philadelphia, PA.

§Fellow, American College of Foot and Ankle Surgery; Director of Podiatric Residency Training, Botsford General Hospital, Farmington Hills, MI.

They ranged in age from 13 to 67 years, with a mean of 37 years. A review of medical records was performed to determine the date of the injury in each case. The date of the injury was obtained for 84 patients; the remaining 24 patients were excluded from the analysis.

Imaging was performed with a 1.5-T unit (Signa®[1]) utilizing an extremity coil. The following sequences were typically used: 1) sagittal T1-weighted image (500/10); 2) sagittal fast–short tau inversion recovery (STIR) image (6000/40/150, echo train length [ETL] = 8); 3) axial proton density image (4000/48, ETL = 4); 4) axial T2-weighted image (6000/90, fat-suppressed, ETL = 8); and 5) coronal fast-STIR image (6000/40/150, ETL = 8). The field of view was 16 cm, the matrix was 256 × 256 (except for sequence 3, which was 512 × 256), the slice thickness was 4 mm, and the interslice gap was 1 mm. The band width was 16 MHz.

Two independent observers (M.E.S. and J.M.L.) separately assessed the images for 1) the morphology of the anterior talofibular ligament (ATFL): whether it was normal, thick or thin, had a defect, or was apparently absent; 2) the distinctness of the ATFL external margins on the intermediate weighted images: whether they showed poor definition, compromised definition, or sharp definition; 3) the presence of periarticular edema on the T2-weighted images; 4) the morphology of the calcaneofibular ligament (CFL); 5) the presence of fluid within the peroneal tendon sheath; and 6) the morphology of the superficial and deep components of the deltoid ligament. Each parameter was then evaluated with respect to the time of the initial injury to determine the timing of the appearance of each characteristic on MRI.

Results

Ligament injuries were observed on MRI in 108 patients. Of the 84 patients with known medical history, 3 (3.6%) had "normal"-appearing ankle ligaments, while 81 (96.4%) had some degree of ATFL injury. Fifty-four (66.7%) of these ATFL injuries were isolated, while 27 involved multiple lateral ankle ligaments. There were 25 injuries involving both the ATFL and CFL, and only 2 of the 81 (2.5%) patients experienced an injury involving the ATFL, CFL, and posterior talofibular ligament (PTFL). All CFL sprains were in association with ATFL sprains, and no PTFL sprains occurred without injury to the ATFL and the CFL. The deltoid ligament was injured in 12 of the 84 patients (14.3%). Three deltoid ligament injuries presented alone (25%), while 9 occurred in association with lateral ligament injuries (75%).

[1] GE Medical Systems, Milwaukee, WI.

Of the 81 ATFL injuries observed, 23 (28.4%) were observed within 2 weeks of the initial injury. From 3 weeks to 7 weeks after the injury, there were 22 ATFL sprains (27.2%), and there were 36 injuries (44.4%) noted more than 7 weeks after the ATFL injury occurred. The morphology of the ATFL following a sprain is displayed in Figure 1. The chart shows that the MR appearance within 2 weeks of the injury was thin in 11 of 23 sprains (47.8%) and was also thin in 17 of 36 patients (47.2%) more than 7 weeks after the injury. In 12 of 23 patients (52.2%) the ATFL had a defect within 2 weeks of the injury, while only 4 of 36 patients (11.1%) had a noticeable defect more than 7 weeks after the injury occurred. The number of patients with a thickened appearance of the ATFL increased from none in the first 2 weeks of the injury to 14 of 36 patients (38.9%) more than 7 weeks after the injury.

Figure 2 shows the definition of the external margins of the ATFL following the injury. The ligament margins improved over time, with poorly defined margins seen in 11 of 23 (47.8%) of the patients within 2 weeks of the injury and in 10 of 36 (27.8%) of the patients more than 7 weeks after the injury occurred. The percentage of patients with sharply defined external ATFL margins increased with time. In 5 of 23 (21.7%) patients, sharply defined margins were noted within the first 2 weeks of the injury; 21 of 36 (58.3%) patients had sharply defined margins more than 7 weeks after the injury.

Periarticular edema was seen consistently throughout the first 6 months following the injury. Within 2

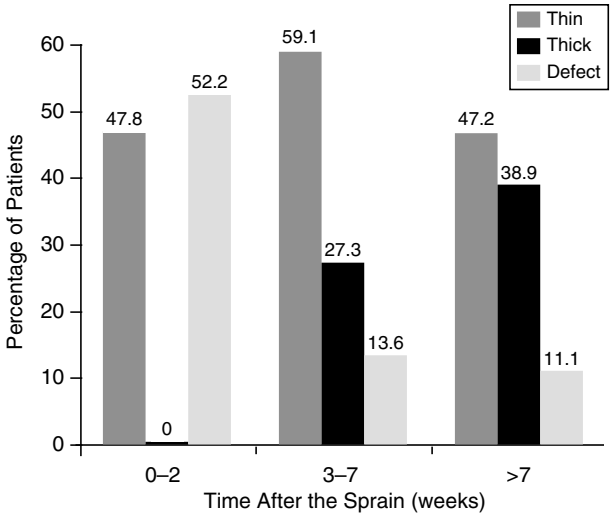

Figure 1. Time-dependent MRI appearance of the anterior talofibular ligament following ankle sprain.

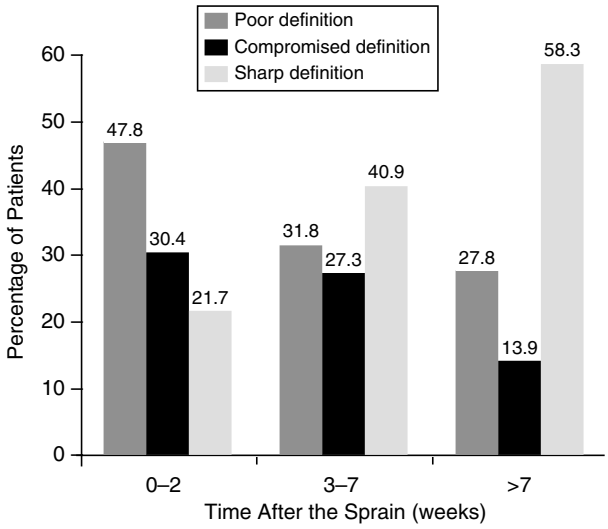

Figure 2. Time-dependent MRI appearance of the anterior talofibular ligament margins following ankle sprain.

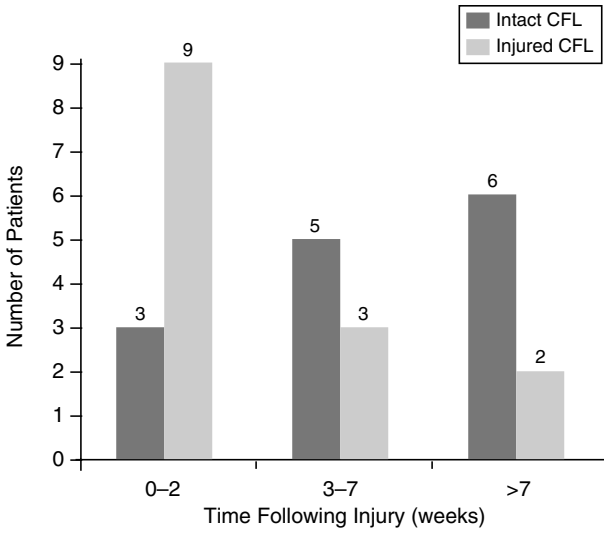

Figure 3. Fluid within the peroneal tendon sheath associated with the integrity of the calcaneofibular ligament.

weeks of the injury, 18 of 23 (78.3%) patients had edema adjacent to the injured ligament. Between 3 and 7 weeks after the injury, 14 of 23 (60.9%) patients had edema, while 13 of 38 (34.2%) patients experienced edema after 7 weeks.

Of 27 patients who experienced a CFL injury, the CFL was found to be irregular with poorly defined margins in 11 patients (40.7%) within 2 weeks of the injury. Six of 27 (22.2%) patients displayed a poorly defined, irregular CFL between 3 weeks and 7 weeks after the CFL injury, and 10 of 27 (37.0%) patients had poor definition of the CFL 7 weeks after the CFL sprain.

Fluid within the peroneal tendon sheath adjacent to the CFL was present in 12 of 23 (52.2%) patients within 2 weeks of the injury, in 8 of 23 (34.8%) patients between 3 weeks and 7 weeks, and in 8 of 38 (21.0%) patients after 7 weeks. Figure 3 shows that some of the patients experiencing fluid in the peroneal tendon sheath had an intact CFL. Three of 12 (25%) patients displayed this finding within 2 weeks of the injury. Between 3 weeks and 7 weeks, 5 of 8 (62.5%) patients had an intact CFL, and after 7 weeks 6 of 8 (75%) patients had an intact CFL (Fig. 3).

Sprains involving the PTFL occurred in only 2 patients. One patient of the 23 patients (4.3%) having MRI within 2 weeks of the injury had an irregular, poorly defined PTFL, no patients had a PTFL injury between 3 weeks and 7 weeks, and 1 patient of 38 (2.6%) had an irregular, poorly defined PTFL evident after 7 weeks. The deltoid ligament was poorly defined and was irregular in 2 of 23 (8.7%) patients within 2 weeks of the sprain. Between 3 weeks and 7 weeks, 5 of 23 (21.7%) patients experienced ligamentous injury, while 5 of 38 (13.2%) patients demonstrated a deltoid injury more than 7 weeks after the injury.

Discussion

Ankle sprain is one of the most common injuries treated in the emergency room and in private practice. The clinical findings of edema and pain are frequently utilized to gauge the severity of the ankle sprain; however, the age of the sprain is often unknown. The extent of the injury and the date of the injury are determining factors in decisions regarding treatment approach.

The deltoid ligament, or medial collateral ligament, is rarely injured; sprains involving the deltoid ligament have been reported to make up only 15% of all ankle sprains.[2] The findings of the present study are consistent with that report; 14% of the cases reviewed involved medial collateral ligament sprains. Of the deltoid ligament sprains observed, 75% had MRI findings consistent with lateral ligament injuries as well. It has been reported that deltoid ligament sprains occur in conjunction with inversion sprains involving the lateral ligaments.[3] Hergenroeder[4] found that the deltoid was affected in 4% of all inversion sprains. However, the present study may demon-

strate that deltoid ligament sprains are superimposed on presumed chronic lateral ligament sprains.[4] The chronic nature of lateral ligament injuries was determined on the basis of the MRI appearance of the lateral ankle joint. This finding is consistent with the patient overcompensating to avoid repetitive lateral ligament sprains, as the risk of acute lateral sprain is increased with chronic instability.[5]

The more commonly injured lateral ankle ligaments are typically injured sequentially as a result of a plantarflexion-inversion force. The plantarflexory force induces an increased tensile force on the ATFL, causing this to be the most frequently injured lateral ligament. While the CFL becomes taut when the ankle is dorsiflexed, it also experiences a tensile force under extreme plantarflexion. The CFL injury then occurs following injury to the ATFL. Calcaneofibular ligament tears rarely occur without injuries to the ATFL and are observed in 25% to 40% of all ATFL tears[6]; 32% of the patients in this study experienced CFL sprains, all in conjunction with ATFL sprains. The least frequently injured ligament is the PTFL. This ligament is the strongest of the three lateral ligaments and is rarely sprained. It is injured only under extreme inversion forces.[7]

The appearance of the ligament and the clarity of the margins of the ligament can help in the evaluation of ligament healing. Ligaments typically heal through filling of the defect with a fibrous scar, which begins to form via fibroblastic proliferation as early as 7 days after the injury.[8] The repaired ligament is not as strong as the ligament was prior to injury, and when untreated may reach only 40% of its normal strength.[9] A number of factors may be involved in the timing of the scar formation and the strength of the scar. Scar formation is typically ligament-specific. It also depends on the location of the sprain: the closer to the bony attachment that the ligament injury occurs, the greater the chance of delayed healing of the ligament.[9, 10]

The authors found that the ATFL demonstrated a defect in nearly half of the patients within 2 weeks of the injury (Figs. 4 and 5), while the remaining ligaments appeared hypoplastic. Between 3 weeks and 7 weeks, there were more thin ligaments and fewer defects. Also noted were thickened ATFLs (Fig. 6). After 7 weeks, the ATFL was predominantly thin or thick compared with the normal appearance. Only 11% displayed a defect. The thin and thick ligament appearance relates to the process of scar formation as the ligament heals. The ligament progresses from an obvious defect to a hypoplastic ligament and eventually to the hyperplastic appearance as it attempts to strengthen to accommodate the forces through the

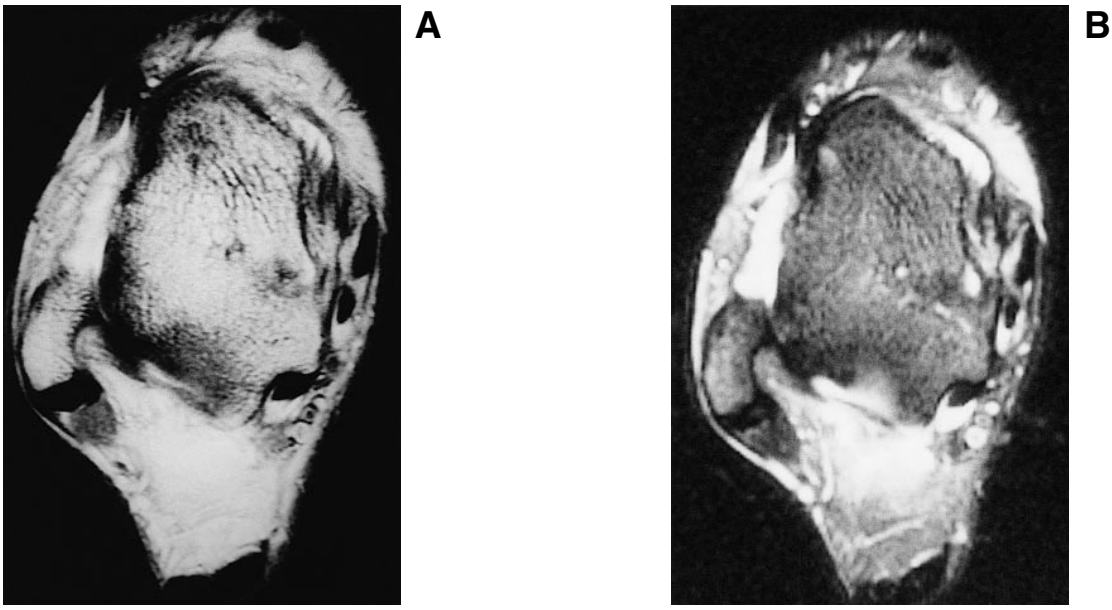

Figure 4. Transverse section of a fast-STIR image (A) and a T2-weighted image (B) shows a rupture of the anterior talofibular ligament from its attachment to the talus. The effusion crossing the ankle joint capsule demonstrates the acute nature of the injury. Note the tenosynovitis of the tibialis posterior, flexor digitorum longus, and flexor hallucis longus tendons.



Figure 5. Transverse section demonstrating an anterior talofibular ligament rupture from the lateral malleolus with ill-defined margins. Note the fluid accumulation at the site of the rupture in this fast-STIR image.

ligament. The thin ligament remained evident in approximately 50% of the imaged ATFL injuries after 7 weeks. This may have been seen because the repaired ligament undergoes repetitive stress while attempting to stabilize the joint, which may cause the ligament to stretch at the site of the fibrous scar. The "stretching out" of the ligament occurs because of the altered biochemical and mechanical properties of the healed ligament.[9, 10]

The margins of the ATFL through these different time periods also demonstrate the process of the development of the fibrous scar as the ligament heals. Poorly defined margins decreased in prevalence as the time period increased, as did compromised definition of the ATFL margins, which was indicated by a wavy appearance of the ligament. This wavy appearance has been previously described as representing the granulation tissue and redundancy of the ligament secondary to the injury.[11] Irregular ligament margins were still seen 8 weeks after the sprain occurred, albeit less frequently. Finally, sharply defined margins were most prevalent more than 7 weeks after the injury. The margins of the less frequently injured CFL and PTFL also demonstrated sharper definition with time. This improvement of ligament definition may be attributed to the ongoing remodeling of the fibrous scar as the resolving hematoma and

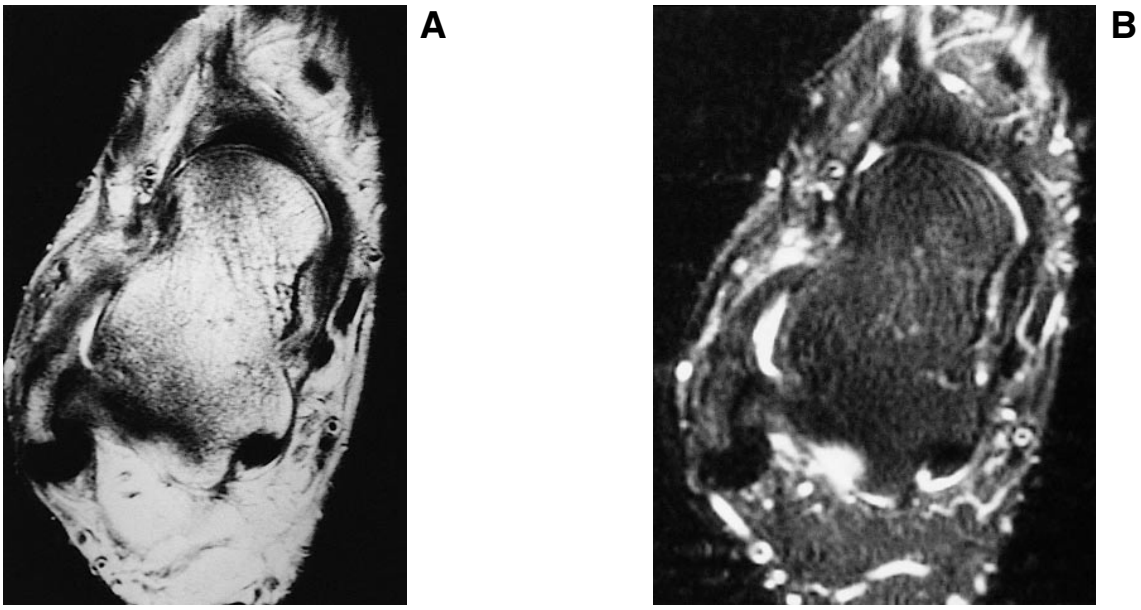

Figure 6. A, T1-weighted image of a sagittal section displays a resolved anterior talofibular ligament injury that has developed a thickened fibrous scar and well-defined margins. Note the presence of fluid within the ankle joint abutting the anterior talofibular ligament. B, Fast-STIR image also demonstrates the edema within the margins of the ankle joint.

the collagen become more organized.[3] It has been reported that these changes have been observed as late as 40 weeks after the injury, and may still not be complete at that time.[10] Therefore, the definition and morphology of the ligament appear to be dependent on the progression of the fibrous scar over time. The poorly defined margins along with the hypoplastic, stretched ligament observed on MRI scans may contribute to the developing ligamentous laxity and chronic instability seen clinically.

Pain and edema are among the clinical symptoms most often used to determine the severity of the injury. These findings are known to be time-dependent. Edema can be present immediately after the injury if the sprain is severe; it can also be slow to progress. The edema may be localized to the lateral ankle; however, as time progresses, the edema may spread through the fascial planes into the foot.[5, 12] The authors found that periarticular edema was commonly present into the seventh week. In contrast, edema associated with acute injuries to the ATFL and CFL has been observed exclusively within the acute period of 0 to 4 weeks.[11] The long-standing edema may have persisted because of the severity of the injury, as it is reliable as a gross indicator of the magnitude of the sprain[5] or the treatment administered.

Fluid found within the peroneal sheath following an ankle ligament injury is typically associated with an acute injury to the CFL. In the present study, more than 50% of the patients with CFL injuries who had MRI studies within 2 weeks experienced fluid within the peroneal sheath (Fig. 7). Fluid within the peroneal sheath was also seen in 21% of the patients after 7 weeks. As the time progressed from the date of the injury, however, the fluid was present without an injury to the CFL at an increasing rate (Fig. 8). For lateral ligament sprains with MRI studies after 7 weeks, 75% of the patients with peroneal sheath fluid demonstrated an intact CFL. This fluid may represent tenosynovitis of the peroneal tendons resulting from the added forces applied to the tendons in an attempt to stabilize the joint laterally in the presence of chronic laxity of the lateral ankle joint.[13]

One limitation of this study is the population bias. Patients with ankle sprains were not prospectively sent to have MRI studies. Rather, only patients with ankle sprains who had MRI studies performed were included. The patient population may have been too small to accurately determine a pattern of the MRI findings evaluated and to perform statistical analysis. Finally, the treatments that these patients underwent varied and were not taken into consideration when analyzing the time of healing of the ligament. The different treatment regimens allow different forces to affect the ligaments during the healing period, which may in turn alter the normal healing process.

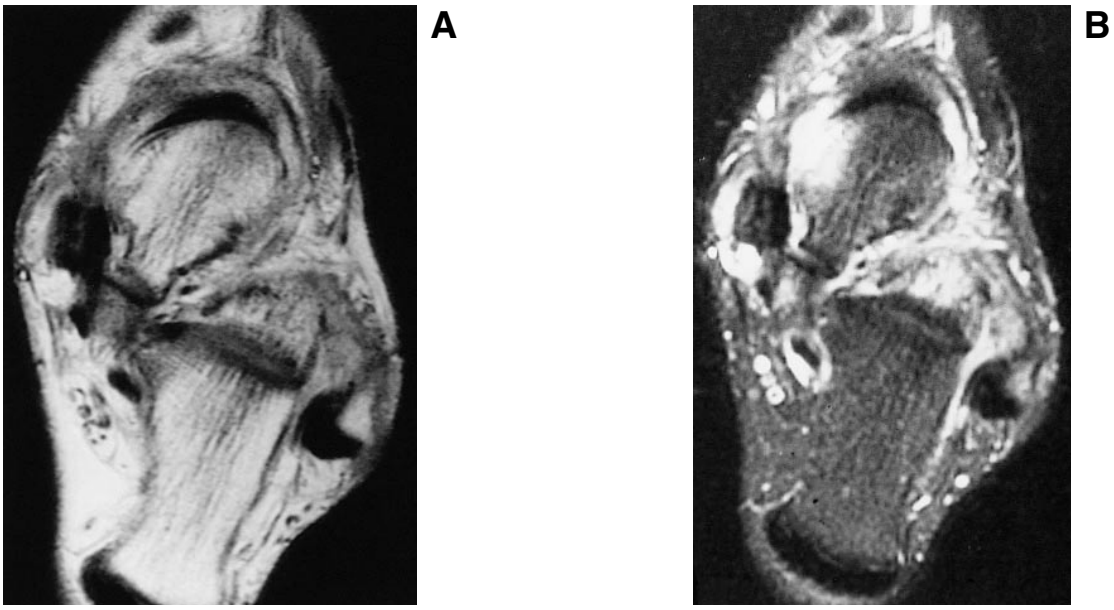

Figure 7. A, Fast-STIR image shows an acute calcaneofibular ligament rupture with a visible defect in the ligament. B, T2-weighted image shows fluid crossing the normal course of the calcaneofibular ligament and some fluid accumulation within the peroneal sheath.

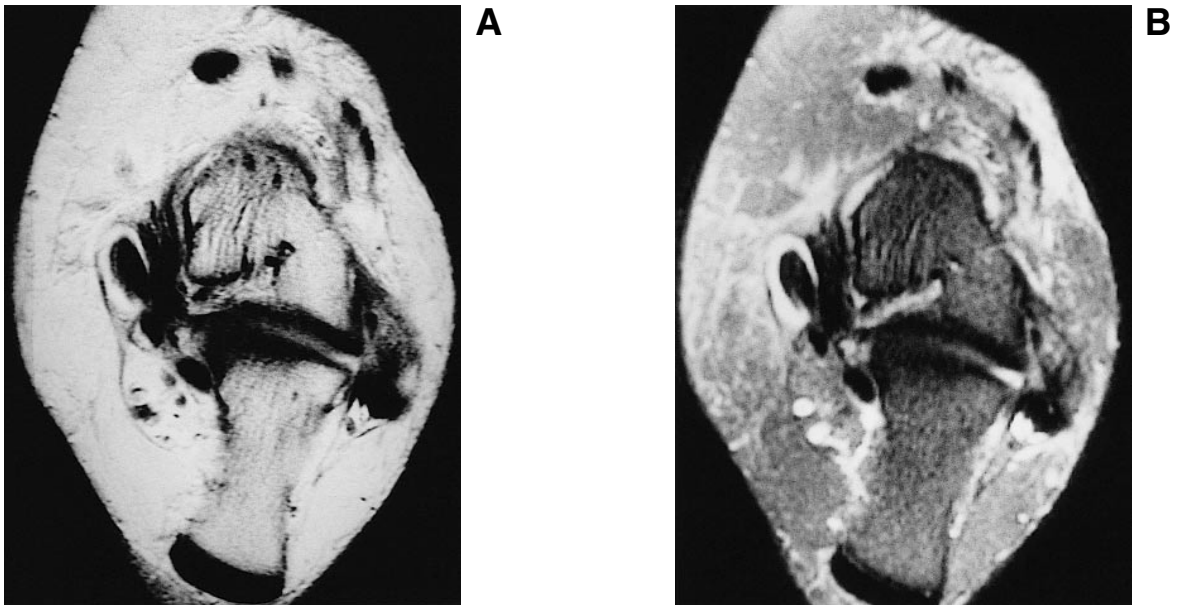

Figure 8. T1-weighted image (A) and fast-STIR image (B) of a coronal section showing fluid within the peroneal sheath and a poorly defined calcaneofibular ligament. Note the tenosynovitis of the posterior tibial tendon.

Conclusion

Acknowledging the limitations of the study, the authors conclude that an acute lateral ligament injury may demonstrate a visible ligamentous defect or a hypoplastic ligament with poor definition of the external margins. Periarticular edema and edema within the peroneal tendon sheath may also be present. A subacute injury may also demonstrate periarticular edema, and the ligaments may present with any stage of ligamentous healing. Finally, a chronic ligamentous injury may involve a fibrous, hyperplastic ligament or chronic laxity from a hypoplastic, stretched ligament with more sharply defined margins. There may be fluid within the peroneal tendon sheath, although there is usually an absence of periarticular edema. Deltoid ligament injuries appear similar to the sprains of lateral ankle ligaments on MRI and may present secondary to compensation for chronic lateral ligament laxity.

References

1. Frey C, Bell J, Teresi L, et al: A comparison of MRI and clinical examination of acute lateral ankle sprains. Foot Ankle Int **17:** 533, 1996.
2. Strong WB, Stanitski CL, Smith RE, et al: Diagnosis and treatment of ankle sprains. Sports Med **144:** 809, 1990.
3. Schneck CD, Mesgarzadeh M, Bonakdarpour A: MR imaging of the most commonly injured ankle ligaments: part II. ligament injuries. Radiology **184:** 507, 1992.
4. Hergenroeder AC: Diagnosis and treatment of ankle sprains. Am J Dis Child **144:** 809, 1990.
5. Perlman M, Leveille D, DeLeonibus J, et al: Inversion lateral ankle trauma: differential diagnosis, review of the literature, and prospective study. J Foot Surg **26:** 95, 1987.
6. Cardone BW, Erickson SJ, Den Hartog BD, et al: MRI of injury to the lateral ligamentous complex of the ankle. J Comput Assist Tomogr **17:** 102, 1993.
7. Boruta PM, Bishop JO, Braly WG: Acute lateral ankle ligament injuries: a literature review. Foot Ankle **11:** 107, 1990.
8. Brostrom L, Sundelin P: Sprained ankles: IV. histologic changes in recent and "chronic" ligament ruptures. Acta Chir Scand **132:** 248, 1966.
9. Frank C, Amiel D, Woo SL, et al: Normal ligament properties and ligament healing. Clin Orthop **196:** 15, 1985.
10. Frank C, Woo SL, Amiel D, et al: Medial collateral ligament healing: a multidisciplinary assessment in rabbits. Am J Sports Med **11:** 379, 1983.
11. Rijke AM, Goitz HT, McCue FC, et al: Magnetic resonance imaging of injury to the lateral ankle ligaments. Am J Sports Med **21:** 528, 1993.
12. Vitale TD, Fallat LM: Lateral ankle sprains: evaluation and treatment. J Foot Surg **27:** 248, 1988.
13. Geppert MJ, Sobel M, Bohne WH: Lateral ankle instability as a cause of superior peroneal retinacular laxity: an anatomic and biomechanical study of cadaveric feet. Foot Ankle **14:** 330, 1993.