Foreign-body Reaction to Absorbable Fixation Devices

To the Editor:

Biodegradable fixation is becoming a viable alternative to traditional fixation techniques. In recent medical literature, a degree of success has been reported in several clinical trials involving long-term follow-up care of patients with absorbable fixation.[1-10] The most common absorbable materials in use are polyglycolide (Biofix®[1]) and poly-p-dioxanon (Orthosorb®[2]). There are, however, complications involved in the use of these types of absorbable fixation devices, as evidenced by the following case report.

Biofix absorbable fixation products consisting of polyglycolide have a well documented foreign-body reaction profile. Sterile sinus formation at approximately 3 months postoperatively occurs at a rate of 3% to 8%.[1, 2] Osteolytic changes in the pin tract of the implant occur in up to 50% of cases.[3] These complications generally have little effect on the healing process after surgery.[4]

Orthosorb products consisting of poly-p-dioxanon, however, have only one previously documented foreign-body reaction in the literature.[5]

The patient in this case was diagnosed with a delayed union caused by foreign-body reaction to Orthosorb pins. This was based on the histologic, radiographic, and clinical findings. Osteomyelitis was ruled out because of a negative histologic examination for infection and negative intraoperative cultures. Displacement caused by partial weight-bearing could contribute to the clinical picture; however, a more significant bony callus and greater deviation of the fourth metatarsal head would be expected if this were the only etiology involved.

Case Report

A 40-year-old female with no pertinent medical history sought treatment for a longstanding tender callus under the fourth metatarsal head of the right foot. The patient had repeated debridements with accommodative padding with little or no relief. After several months of unsuccessful conservative therapy, the patient underwent an elevating V-osteotomy of the fourth metatarsal head. Fixation was accomplished with two 1.3-mm Orthosorb pins. These pins were placed in a crosswise fashion through the osteotomy site. Postoperative radiographs revealed adequate approximation of the osteotomy. No gapping or deviation of the capital fragment was seen. The patient was placed in a below the knee cast with a cane with partial weight-bearing.

At the first postoperative visit 6 days later, slight erythema of the operative site was seen. No drainage or dehiscence was noted. The patient began empiric oral antibiotic therapy for a possible postoperative infection. Plain film radiographs revealed adequate apposition of the osteotomy with no lucency present (Fig. 1). A below the knee cast was reapplied and the patient continued partial weight-bearing with a cane. Two weeks postoperatively, the incision site had persisting local erythema with maceration present. No significant drainage was seen. The sutures were removed and a surgical shoe was dispensed. The patient continued the oral antibiotics.

Five weeks postoperatively, the incision area was ulcerated with increased erythema. Serous drainage was noted from a superficial sinus that did not track to deep tissues. The patient related



Figure 1. Anteroposterior radiograph of the right foot 6 days after surgery. Note the adequate apposition of the fourth metatarsal osteotomy fixated with Orthosorb pins.

®[1]Acufex Microsurgical, Inc, Norwood, MA.

®[2]Johnson & Johnson Orthopaedic, Inc, New Brunswick, NJ.

increased pain on ambulation in the area of the fourth metatarsal head of the right foot for the past several days. Cultures of the drainage revealed no growth.

Seven weeks postoperatively, the incision was dry without sinus, local edema, or erythema. The patient related continued pain in the location of the osteotomy during cane-assisted ambulation. Radiographs at this time revealed a transverse area of lucency at the osteotomy site of the fourth metatarsal (Fig. 2). No significant displacement or rotation of the fourth metatarsal head was present. No apparent bony callus formation was noted. The patient was continued on the current treatment plan with suspicion of foreign-body reaction as the cause of symptoms and radiographic changes the patient was experiencing.

One month later, in the eleventh week after surgery, the patient related gradually increasing levels of pain at the operative site aggravated by ambulation. Significant pain could be elicited on palpation of the plantar aspect of the metatarsal head, which was not previously present. The incision area appeared to be healed without drainage, erythema, or any sign of inflammation. Radiographs revealed increased area of lucency at the osteotomy site in comparison to the previous films (Fig. 3). The osteotomy edges were separated by an approximately 5-mm gap, constituting a delayed union of the fourth metatarsal. No gross angulational or rotational deformities of the fourth metatarsal head were noted, however. An open reduction with internal fixation and a biopsy of the fourth metatarsal of the right foot were performed.



Figure 2. Anteroposterior radiograph of the right foot 7 weeks after surgery. Note the lucent area in the fourth metatarsal osteotomy site.



Figure 3. Anteroposterior radiograph of the right foot 11 weeks after surgery. Note the increased size of the lucent area in the fourth metatarsal caused by the foreign-body reaction.

Intraoperatively, the affected metatarsal neck area was seen with hypertrophied fibrous tissue surrounding the delayed union site. The capital fragment was noted to have significant mobility against the shaft of the fourth metatarsal. Using a combination of blunt and sharp instrumentation, this tissue was removed and a serous exudate with multiple small, apparently osseus fragments was noted. Also, several small, transparent fragments of foreign-body material were observed in the delayed union site. Bony gapping consistent with previous radiographic measurements was present. The osteotomy edges appeared without necrosis which would be expected if infection were present.

An osteotome and mallet were used to resect the edges of the osteotomy site. This bone and fibrous tissue were sent for histopathology and culture and sensitivity. The gap between the osteotomy edges was evacuated of all debris and fibrous tissue. The osteotomy was then approximated, impacted, and fixated with 0.045 Kirschner wire. The patient was placed in a nonweightbearing below the knee cast.

The results of the surgical pathology report indicated that a focus of foreign-body reaction to a basophilic, suture-like material was present with bone, cartilage, and fibrous tissue. Multinucleated

giant cells were noted with the presence of clear, refractile matter consistent with partially absorbed internal fixation material (Fig. 4). No polymorphonuclear leukocytes were present. Cultures intraoperatively were negative, which in light of the histopathologic findings, ruled out infection as an etiology for the delayed union of the fourth metatarsal.

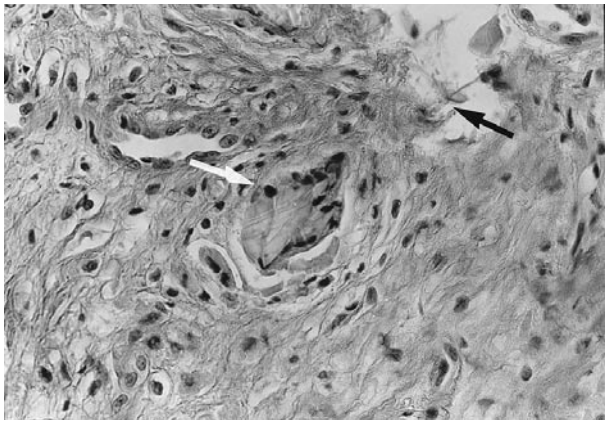

Figure 4. Light photomicrograph of focal tissue reaction. Note the presence of a multinucleated giant cell (white arrow) and clear, basophilic, suture-like Orthosorb material (black arrow) (H&E × 200).

Summary

While it is evident that poly-p-dioxanon is less reactive than polyglycolide, recent studies, including the case above, have shown that Orthosorb pins are not exempt from the same type of foreign-body reaction as the Biofix products.

JEFFREY FREDERICK, DPM
TIMOTHY J. HULST, DPM
ALISTAIR S. SUNDARESON, MD
Wayne State University
Hutzel Hospital
4707 St Antoine Blvd
Detroit, MI 48201

References

1. HIRVENSALO E, BOSTMAN O, TORMALA P, ET AL: Chevron osteotomy fixed with absorbable polyglycolide pins. Foot Ankle **11:** 212, 1991.
2. BOSTMAN O, HIRVENSALO E, VAINIONPAA S, ET AL: Degradable polyglycolic rods for the internal fixation of displaced bimalleolar fractures. Int Orthop **14:** 1, 1990.
3. BOSTMAN O: Osteolytic changes accompanying degradation of absorbable fracture fixation implants. J Bone Joint Surg **73B:** 679, 1991.
4. GERBERT J: Effectiveness of absorbable fixation devices in Austin bunionectomies. JAPMA **82:** 189, 1992.
5. KALLA TP, JANZEN DL: Orthosorb: a case of foreign-body reaction. J Foot Ankle Surg **34:** 366, 1995.
6. STRYCKER ML: Biodegradable internal fixation. J Foot Ankle Surg **34:** 82, 1995.
7. LAVERY LA, PETERSON JD, POLLACK R, ET AL: Risk of complications of first metatarsal head osteotomies with biodegradable pin fixation: Biofix *versus* Orthosorb. J Foot Ankle Surg **33:** 334, 1994.
8. BRUNETTI VA, TREPAL MJ, JULES KT: Fixation of the Austin osteotomy with bioresorbable pins. J Foot Surg **30:** 56, 1991.
9. FRIEND GJ, GRACE KS, STONE HA: Cortical screws *versus* absorbable pins for fixation of short z-bunionectomy. J Foot Ankle Surg **33:** 411, 1994.
10. HETHERINGTON VJ, SHIELDS SL, WILHELM KR, ET AL: Absorbable fixation of first ray osteotomies. J Foot Ankle Surg **33:** 290, 1994.

Ectrodactyly
A Unique Case Presentation

To the Editor:

Cleft foot, lobster foot, claw foot, and ostrich foot are synonyms for a rare pedal deformity occurring in 1:90,000 births. The defect is characterized by the absence of the central digits and metatarsals. The first and fifth digits, with their respective metatarsals, are frequently present, along with a concomitant hypertrophy of the first ray. A common presentation of the malformation is a concomitant cleft foot and hand.

Early references to ectrodactyly are rare. Such occurrences were merely regarded as "monsters." However, an early clinical reference to the hand and foot ectrodactyly was made by Pare in 1573.[1] Far from an association with monsters, the malformation is believed to be transmitted in an autosomal dominant inheritance pattern. Males are more frequently affected than females.[2, 3]

Cleft foot may exist as a unilateral or bilateral pedal deformity in many combinations with other deformities. It may present as an isolated deformity or simultaneously with similar defects in the hand. It most frequently presents as part of a defect syndrome, including defects of the eye, palate, audition, and abnormalities of the kidneys.[4] The cleft foot, absent of similar upper extremity deficits, occurs in 10% to 50% of cases of trisomy 18.[5] Severe mental retardation, seizures, microcephaly, abnormal facies, and vertebral anomalies are frequently present as a result of a 7q chromosomal deletion.[6] Few reports exist of ectrodactyly that is bilateral and of isolated, spontaneous origin.

Case Presentation

A 15-month-old male was presented by his parents, who were distressed at the child's abnormality. Except for the presence of bilateral cleft hands and feet, the child was typical for a child his age. The parents feared that they had done "something wrong" which had manifested as the child's deformity.

According to the parents, the pregnancy and delivery were unremarkable, with the child carried to full term. Both parents denied exposure to mutagenic agents or knowledge of other family members with the deformity. Neither parent used tobacco, drank alcoholic beverages, or used recreational drugs. A consanguineous marriage was also denied. There were no other children as a result of the marriage and both parents presented with normal extremities and were free of other congenital anomalies.

Physical examination of the patient was unremarkable, except for the deformities of the upper and lower extremities. The facies were entirely normal and there was no evidence of cleft palate or lip. The child was alert and showed normal developmental skills for his age. While the child had not yet attempted bipedal ambulation, he showed an interest in attempting to place his feet under his body. The child also made an active effort to grasp objects with his "pincer-like" hands. The feet had normal sensory capabilities and the child responded to manipulation of his feet during the examination.

A radiographic examination of the feet was performed (Figs. 1 and 2). An expected and obvious finding was a bony agenesis of the central lesser digits. The greater tarsal bones were present. However, the osseous structures normally associated with the second and third digits were absent. The halluces were skeletally complete and were bilaterally hypertrophic. The metatarsals of the fourth and fifth digits were complete and independent. The proximal, intermediate, and distal phalanxes were present as independent structures, forming a single digit. This digit was supported by the fully formed fourth and fifth metatarsals.

Accommodation of the deformity was recommended until further development of the distal extremity had taken place. The parents strongly desired an early heroic effort to provide the child with more "normal appearing" hands and feet. Attempts to guide the parents into a supportive network failed and the patient was eventually lost for follow-up care.

According to the information from the history and physical examination, the patient represented a purely spontaneous occurrence of isolated, bilateral cleft hands and feet. However, the child had achieved all expected developmental milestones and appeared mentally capable to achieve skills later such as walking.



Figure 1. View of the dorsoplantar aspect of bilateral cleft foot. Note the claw-like appearance of the feet and agenesis of the second and third metatarsals.

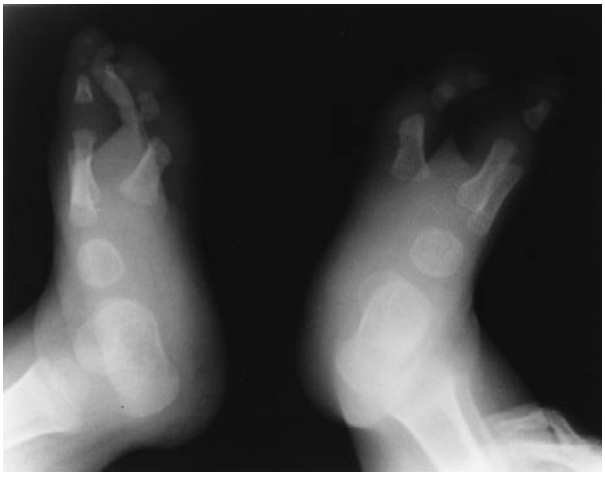

Figure 2. An oblique view of bilateral cleft foot showing only two digits along with agenesis of the central phalanges.

Conclusion

Ectrodactyly is extremely rare and is often associated with other deformities. The authors' case presentation, however, was of a spontaneous origin and without other abnormalities. Otherwise, the clinical presentation of the hands and feet were consistent with the literature.

JOHN C. LIBBIE, DPM
FRANCIS F. DERK, DPM
ANTHONY J. NARDOZZA, DPM
Podiatric Medicine Residency Training Program
The Waco Veterans Affairs Medical Center
4800 Memorial Dr, 112-B
Waco, TX 76711

Acknowledgment. The views and opinions expressed in this study are those of the authors and do not expressly reflect the views of the Department of Veterans Affairs.

References

1. BARSKY AJ: Cleft hand: classification, incidence and treatment. J Bone Joint Surg **46A:** 1707, 196.
2. WALLACE GF, HEALY KM: "Miscellaneous Conditions," in *The Textbook of Podiatric Medical and Surgical Practice*, ed by DE Marcinko, Williams & Wilkins, Baltimore, 1992.
3. BOUCHARD JL: "Congenital Deformities of the Foot," in *Comprehensive Textbook of Foot Surgery*, 2nd Ed, Vol 2, ed by ED McGlamry, AS Banks, MS Downey, Williams & Wilkins, Baltimore, 1992.
4. CASELLI MA, RUBENSTEIN D: Pedal ectrodactyly: a biomechanical approach to management. J Foot Ankle Surg **34:** 215, 1995.
5. CASTLE D, BERNSTEIN R: Trisomy 18 syndrome with cleft foot. J Med Genet **25:** 568, 1988.
6. MCELVEEN C, CARVAJAL MV, MOSCATELLO D, ET AL: Ectrodactyly and proximal/intermediate interstitial deletion 7q. Am J Med Genet **56:** 1, 1995.

Pedal Manifestations of Milroy's Disease

To the Editor:

Milroy's disease, initially described by Letessier in 1865, is a rare congenital lymphedema characterized by familial occurrences of painless swelling in one or both lower extremities. The incidence of this disease is approximately one per million live births.[1] The pathogenesis of the disorder is unclear, but it is thought to be secondary to dysplasia and abiogenesis of the lymphatic channels. Associated features typically include an autosomal dominant inheritance, multiple ocular abnormalities, and vertebral and spinal cord anomalies.[1] The authors present a case of an adult male patient with Milroy's disease to clarify the difficult management of the soft tissue complications of this disease.

Case Report

A 43-year-old male was referred by his primary care physician for preoperative evaluation prior to surgical debridement and skin grafting of the right and left feet.

The patient had suffered from idiopathic congenital lymphedema since birth, and according to the patient, had undergone approximately 198 reconstructive surgeries of the lower extremities. The patient had suffered from chronic infections of the feet bilaterally, particularly of the left foot, and has had multiple episodes of cellulitis complicating his lymphedema. He had a transmetatarsal amputation of his right foot (Fig. 1).

On his left foot, the great toe had suffered repeated bouts of cellulitis and subsequent eschar in the hyperkeratotic areas. The patient had been conservatively treated for 8 months using whirlpools, dressings, and multiple courses of antibiotics.

The patient had continued to have recurrent infections on the dorsal aspect of the left great toe and a recurrent pressure ulceration on the dorsal aspect of the right foot. Multiple soft tissue cultures were taken intermittently from the foot and toes, revealing heavy *Staphylococcus aureus* and β-hemolytic *Streptococcus* group G growth, organisms typical of lymphedema. These organisms were sensitive to cephalosporins. There was no anaerobic growth.

Medical history is significant for heart disease with no known family history of Milroy's disease. A



Figure 1. Dorsal view of the right foot.

review of systems revealed no evidence of any lung, kidney, liver, or bleeding problems.

The physical examination showed that the patient was a well developed, well nourished male. There was bilateral congenital lymphedema and evidence of surgeries and skin grafts extending proximal to the inferior abdominal area and involving the scrotum.

The left great toe had hyperkeratotic areas on the dorsum from previous skin grafts, with fissuring and recurrent infections. The left pedal skin was indurated and bound with multiple fissuring and pitting, with the largest pits extending to a depth of approximately 1 cm. The induration extended proximally to include the ankle areas (Fig. 2).

The right foot was also indurated, and exhibited a 4-cm ulceration at the dorsal aspect proximal to the metatarsal heads, which was caused by pressure from the tongue of the shoe. This ulcer was treated with antibiotic and felted foam therapy for approximately 3 weeks prior to skin grafting. The dorsal skin on both feet was from previous skin grafts. The skin on the plantar aspect was normal bilaterally.

Surgery

The procedure began with debridement of the ulcers on the right dorsal foot, and the left great toe, and the space between the great toe and small toe where the toes had been amputated. This was excised down to bleeding dermis to remove all necrotic buildup. A split thickness skin graft was harvested from the right thigh. This was meshed 1.5 to 1 and applied to the open areas.

At the 1-month postoperative visit, the skin graft and donor sites had healed without complications. Approximately 2 months after the surgery, the patient was back at work, however not yet wearing shoes. There was recurrent breakdown of the skin graft of the left great toe (Fig. 3). After discussion with the patient, both the patient and surgeons believed that the patient would probably be better served by a transmetatarsal amputation.



Figure 2. Note deep fissuring of the left foot.



Figure 3. Two months after surgery on left foot.

Discussion

The management of lymphedema is difficult and often unrewarding.[2] Recurrent attacks of cellulitis caused by β-hemolytic *Streptococcus* are common and should be vigorously treated. Debridement, dressings, and cephalosporin-type antibiotics ought to be administered to avoid further lymphatic destruction, septic arthritis, or systemic infections.[1] Prophylactic antibiotics for prevention should be considered. Surgery or excision of edematous tissue is reserved for severe cases where the swelling is marked, irreversible, and extremely disfiguring. Microlymphatic surgery, as described by Puckett[3], has also been attempted to manage lymphedema, but with little success.

Summary

A pedal complication of Milroy's disease has been presented. With a history of multiple debridement procedures as in this case, there is the risk of recurrent infections and the possibility of permanent

vascular compromise, particularly with respect to the thin pedal skin on the dorsal aspect. When the toes are recurrently involved with infection, a patient may be best served with a transmetatarsal amputation using a skin flap on the plantar aspect.

SUNIL D. MEHTA, BS
RICHARD J. ROBINSON, DPM
SAMUEL A. BERN, MD
138 N Tenth St
Santa Paula, CA 93060

References

1. ALBORNOZ MA, MYERS AR: Recurrent septic arthritis, and Milroy's disease. J Rheumatol **15:** 1726, 1988.
2. HARRISON TR: "Lymphatic Disorders: Lymphedema," in *Harrison's Principles of Internal Medicine*, 13th Ed, Vol 1, ed by KI Isselbacher, McGraw-Hill, New York, 1994.
3. PUCKETT CL: "Microlymphatic Surgery for Lymphedema," in *Symposium on Clinical Microvascular Surgery*, ed by WW Shaw. Clin Plas Surg **10(1):** 133, 1983.

Dysfunctional Posterior Tibial Tendon

To the Editor:

Injuries to the posterior tibial tendon that commonly cause instability to the foot and ankle and allow it to twist and give way are often overlooked.

One injury is a partial rupture of the posterior tibial tendon at the insertion into the navicular, usually causing pain along the arch area and also underneath and behind the medial malleolus. The pain can become so intense that patients cannot bear weight. In adolescents, this injury can lead to a complete rupture.

In adolescents, it is common to see a secondary cause in which an extra bone is found on the navicular (os navicularis). When this extra bone is present, the tendon can be attached on this extra bone. This leaves the tendon weak so that the posterior tibial attachment will not be strong enough to resist the pressure when adolescents reach a certain point in their growth. Most of the time, the presence of an os navicularis can be dealt with by the use of an orthosis to help stabilize the foot.

A second possibility is a complete or near-complete rupture of the posterior tibial tendon. This means that the tendon loses its ability to stabilize the foot. The only muscle left to invert the foot is the anterior tibial muscle, and it pulls the foot only as far as the midline. When this happens, the arch of the foot will start to collapse dramatically.

If this goes untreated for several months or more, the forefoot drifts laterally into an abductus position. The patient loses the ability to propel off of the ball of the foot. Arthritic degeneration begins in the midtarsal joints. Once the forefoot abductus has taken place, the process will not be able to be completely reversed with the attachment of the posterior tibial tendon to its correct position. Arthritic degeneration of joints and tearing of other ligaments caused by abnormal pressure result in severe pain and irreversible subluxation of the forefoot joints. If the repair is not done, further insidious degeneration of most joints in the foot will occur. The foot becomes so painful the patient cannot use it. A complete rupture or near-complete rupture would require surgery to reattach it. If the repair is made early enough, there is no permanent damage done to the area.

A tear to the posterior tibial tendon needs a below the knee walking cast to take the pressure off of the tendon so it will heal in its correct physiologic length without excessive scar tissue to weaken its attachment. Without the cast, most will progress to a more complete rupture because the muscle would continue to pull at the weak attachment, not allowing it time to heal. An elastic bandage and most ankle braces are inadequate.

Figure 1 shows the patient's foot before tendon detachment occurred. Figure 2 shows the patient's



Figure 1. The patient's left foot before the tendon detached.



Figure 2. The patient's forefoot approximately 6 months after detachment.

forefoot after approximately 6 months of tendon detachment. If intervention had not occurred, the foot would have drifted further into an abductus position.

The author has seen many cases in which the forefoot was beginning to abduct on the rearfoot. In each case, the patient had sought care because of the pain.

The patient had been seen in the emergency department and x-rays had been taken. No fracture was seen on the x-ray so the injury was not detected. The patient was instructed to wear an elastic bandage and had no follow-up visits. He had been subsequently seen by a primary care physician but was informed it would require some time to heal. The patient had continued to limp until he could see his foot literally start to shift out of position.

When a patient has an ankle injury, a muscle strength test should be done to determine if damage has been done to the muscles or tendons. A patient with proper muscle strength should be able to invert the foot easily. In the case of a ruptured posterior tibial tendon, the patient could easily be overpowered.

In either a partial or complete rupture, muscles will have been injured in the process. It has been shown that normal walking or other forms of activity do not strengthen either the inverters or the everters of the foot. Once they have been weakened, they will remain weak unless specific exercises are given that rebuild these muscles.

It should be noted that children can have a rupture almost spontaneously without a severe injury because of an abnormal attachment of tendon. This is not as common as the acute injuries.

JAMES I. JEFFERY, DPM
450 N 300 West
Provo, UT 84601