1996 William J. Stickel Gold Award

Closed Kinetic Chain Tarsal Mechanics of Subtalar Joint Arthroereisis

JEFFREY C. CHRISTENSEN, DPM*
NEIL CAMPBELL, DPM†
KRIS DiNUCCI, DPM†

The weightbearing biomechanics of the tarsus with and without subtalar joint arthroereisis was investigated in 11 fresh frozen cadaver specimens using a three-dimensional (3-D) radiowave tracking system. Specimens, consisting of the distal half of the tibia and fibula and the intact ankle and foot, were mounted on a nonmetallic loading frame test system that allowed positioning of the foot to simulate midstance position of gait. The tibia was axially loaded to 756 N (one bodyweight) with 15% of the total load diverted through the fibula. Receiving transducers were attached to the talus, navicular, calcaneus, and cuboid bones. Tarsal movements were monitored as the specimen was loaded with and without subtalar joint arthroereisis. Three-dimensional data sets of osseous positions and orientations were collected and analyzed. Significant rotational differences were detected with and without subtalar joint arthroereisis for all four tarsal bones ($p \leq 0.05$). Tarsal translational position changes were small and not statistically significant.

The function of the human foot has long been a subject of interest. Many in-depth biomechanical and kinematical investigations and discussions concerning the normal function of the foot have been published.[1-14] While important fundamental concepts regarding normal weightbearing mechanics have evolved, similar theories concerning pathologic foot conditions and their associated treatments remain undefined.

Flexible flatfoot is a pathologic condition characterized by dorsal and lateral peritalar subluxation of the forefoot, medial arch collapse, medial talar bulging, and calcaneal eversion. It is a well recognized clinical entity with a spectrum of severity from mild to disabling.[15-24] Conservative treatments for milder cases have included orthotic devices and shoe modifications.[20-24] The resistant and disabling flatfoot have traditionally been treated with various surgical techniques that include tendon transfers,[15, 25-27] tarsal arthrodeses,[28-31] calcaneal osteotomies,[32-42] and motion-blocking procedures of the subtalar joint.[16, 43-53] The lack of laboratory studies has limited the evaluation of flexible flatfoot and its surgical treatments to subjective interpretation of radiographs and clinical examination.

Subtalar joint arthroereisis is one type of motion-blocking procedure that has been reported in the podiatric and orthopedic literature.[43-53] The precise biomechanical effects of this procedure are unknown. However, clinical and radiographic data have

*Diplomate, American Board of Podiatric Surgery; Fellow, American College of Foot and Ankle Surgeons; Director of Research, Northwest Podiatric Foundation, Everett, WA; Attending podiatric surgeon, Washington Center for Specialty Surgery, Seattle. *Mailing address*: 4027 Hoyt Ave, Ste 104, Everett, WA 98201.

†Submitted during second year residency, Waldo Surgical Residency Program, Washington Center for Specialty Surgery, Seattle.

documented an improved weightbearing foot position.[45-47, 50, 52, 53] While subtalar joint arthroereisis apparently functions by blocking end-range pronatory rotation of the talus, the kinematic effects on individual tarsal segments remain undefined. The purpose of this investigation was to measure rotational and translational positions of the tarsus in a global coordinate system using a weightbearing cadaver model with and without subtalar joint arthroereisis.

Materials and Methods

Specimen Preparation

Twenty fresh cadaver lower-limb specimens were transsected 15 to 20 cm above the plafond, wrapped in saline-soaked towels, and deep frozen to -20°C. Screening was performed using radiography for abnormal joint space narrowing, alignment disorders, subchondral bone density, and by visual inspection for degeneration of the joint surfaces. From the total obtained, seven specimens were eliminated and two were used in preliminary testing, leaving 11 for the current study. The mean age of the tested donors was 67 years (range 34 to 86 years).

Before testing, each specimen was completely thawed at room temperature. The skin, muscle, and other soft tissues were removed from the tibia and from around the joint capsules. Care was taken to preserve the medial and lateral ligaments of the ankle, as were the interosseous membrane, plantar soft tissues, and joints of the foot.

Threaded nonmetallic rods were placed into the tibial and fibular medullary canals to act as vertical load transfer devices to the specimen. Both rods passed through a plastic instrumented plate that allowed variable load distribution to the fibula (Fig. 1). The transfer device attached to a vertical rod on the load frame to facilitate specimen loading.

Load Frame

The specimens were mounted on the lower portion of a custom loading frame (Fig. 2). The lower portion of the frame was constructed of nonmetallic materials, to prevent signal interference of the radiowave tracking system. The upper portion, which was 5 feet above the load platform, permitted mounting of a pneumatic load cylinder to apply axial load to the specimens. The cylinder was regulated and transferred applied load through a polycarbonate rod to the leg. The system was calibrated using a load cell to ensure reproducible load application between specimens.

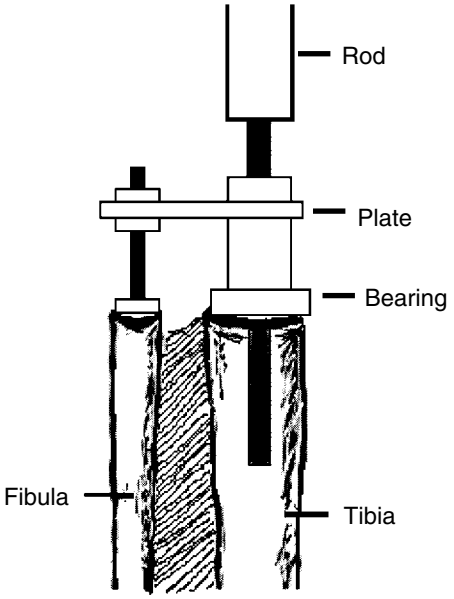

Figure 1. Schematic diagram of load-distributing plate that generated differential loading of the fibula to 15% of load applied to tibia. Additionally, as load is applied to the leg, a bearing surface permitted unconstrained transverse tibial rotation to prevent restriction of talar motion.



Figure 2. Custom load frame with specimen in place. The lower portion of the load frame is made of nonmetallic materials to prevent signal interference of the electromagnetic system. The upper portion of the frame is 5 feet above the load platform and permits mounting of a pneumatic load cylinder to transfer force through a polycarbonate rod to apply load to the tibia.

The axial load shaft was connected to the leg through the load-distributing plate. This allowed the leg to be maintained in a vertical position throughout the testing session. The plantar aspect of the foot was placed on nonskid material on the load frame platform, perpendicular to the leg.

Three-dimensional Tracking System

An electromagnetic system was used to perform three-dimensional (3-D) tracking of multiple osseous segments simultaneously. The system is based on generating low frequency, magnetic field vectors from three collocated, stationary antennas in a single transmitter assembly mounted to the platform base (Fig. 3). Detection of the field vectors was through four remote receiving antennas that were transfixed to the tarsal segments. The signal data were put into a mathematical algorithm that computed the receiver's position and orientation relative to the transmitter. This allowed tracking of a defined point in a global coordinate system with 6° of freedom for each receiver. The signals were collected at a rate of 30 Hz and converted to 3-D data points that were stored on computer files. The system has a resolution of 0.0005 cms/cm of range and 0.025° of rotation and accuracy within 0.08 cm root mean square and 0.15° root mean square.[54] The tracking system was pretested and verified to design specifications on a calibrated platform.

Attaching and Aligning the 3-D Motion-tracking System

The signal receivers were attached to milled acrylic plates that were attached to carbon-fiber rods. The receivers and carbon-fiber rod assemblies were small and did not interfere with joint motion, yet were stiff enough to resist bending from the attached transducer (Fig. 3). The carbon-fiber rods were cut to 6.350 (± 0.005) cm and cemented into drill holes in each respective tarsal bone being tested. The transmitter component was attached to the load frame platform posterior to the specimen with the x-axis projecting through the center of the calcaneus and the second metatarsal. The transmitter served as the reference point in the global coordinate system. This configuration allowed the receiving transducers to track the exact movements of each bone.

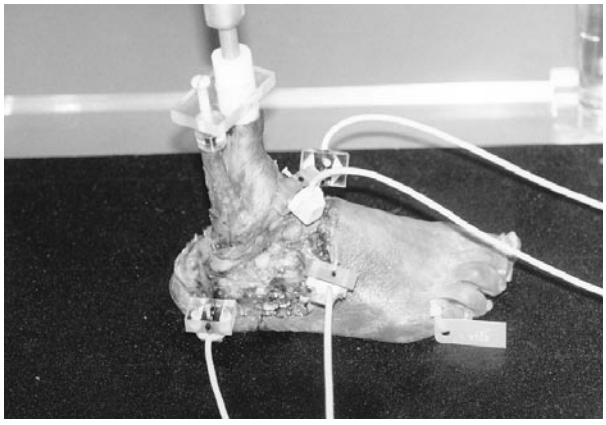

Figure 3. Photograph of foot specimen in testing position. Note four 3-D signal-receiving transducers mounted to corresponding tarsal bones through cemented graphite rods. The reference transducer (black box) is mounted on the platform posterior to the specimen.

Load-distributing Plate

The load-distributing plate was fabricated from nonmetallic materials (Fig. 1). It is held by threaded fasteners placed on the tibial shaft above and below the plate. It engaged the tibia in a manner that facilitated vertical load transfer while allowing unconstrained transverse plane tibial rotation. The plate extended over the fibular shaft and a threaded screw through the plate engaged an acrylic cap on the end of the fibula. It functions by advancing the screw that applies a load to the fibula. This fibular load was calibrated with a load cell prior to application on the specimen. Fibular load was applied at 15% of the total applied load.[55, 56]

Experimental Sequence

The testing procedure was undertaken at room temperature. The specimen was kept moist with frequent saline misting. Baseline 3-D osseous positions and orientations were recorded after several load cycles were applied to condition the specimen. Axial loading to 756 N (one bodyweight) was applied to the specimen during 30 sec and held constant for 15 sec. The first recorded load cycle measured tarsal positions and orientations without subtalar joint arthroereisis. Without changing the position of the specimen on the frame, a medium-size, ultrahigh molecular weight polyethylene endoprosthesis, which was angulated at 8°, was inserted in standard fashion and the foot was again peak loaded to 756 N.[46]

Data Processing

Raw data were collected on a personal computer and then processed to translate sensor data from each osseous segment to a global coordinate system.

Statistical Analysis

Nonparametric statistical analysis was performed using Wilcoxon's signed rank for each plane of motion for all tarsal segments. Differences with confidence levels of $p < 0.05$ were considered statistically significant.

Results

Navicular Positional Changes (Fig. 4). Navicular rotational orientations of loaded foot specimens with and without subtalar joint arthroereisis were recorded in all three cardinal planes. After subtalar joint arthroereisis, the implant effectively inverted and slightly dorsiflexed the navicular from its normal resting position. Mean frontal plane rotational differences (inversion around x-axis) measured 6.75° (SD = 4.54) ($p = 0.0006$). Differences in mean sagittal plane rotation (dorsiflexion around y-axis) measured 1.64° (SD = 1.59) ($p = 0.0066$). Differences in transverse plane rotation (z-axis) and positional displacements of the navicular with and without subtalar joint arthroereisis were not significant.

Talar Positional Changes (Fig. 5). Talar rotational orientations of loaded foot specimens with and without subtalar joint arthroereisis were recorded in all three cardinal planes. After subtalar joint arthroereisis, the implant effectively abducted and dorsiflexed the talus from its normal resting position. Mean differences, which were significant in transverse plane rotation (abduction around z-axis), measured 4.63° (SD = 3.86) ($p = 0.0026$). Mean differences, which were significant in sagittal plane rotation (dorsiflexion around y-axis), measured 4.35° (SD = 2.90) ($p = 0.0066$). Frontal plane rotational differences (x-axis) and positional displacements of the talus, with and without subtalar joint arthroereisis, were not significant.

Cuboid Positional Changes (Fig. 6). Cuboid rotational orientations of loaded foot specimens, with and without subtalar joint arthroereisis, were recorded for all three cardinal planes. After subtalar joint arthroereisis, the implant inverted the cuboid from its normal resting position. Mean differences, which were significant in frontal plane rotation, (inversion around x-axis), measured 4.90° (SD = 2.81) ($p = 0.0002$). Mean transverse (z-axis), sagittal (y-axis) plane differences and positional displacements of the cuboid, with and without subtalar joint arthroereisis, were not significant.

Calcaneal Positional Changes (Fig. 7). Calcaneal rotational orientations of loaded foot specimens, with and without subtalar joint arthroereisis, were recorded for all three cardinal planes. After subtalar joint arthroereisis, the implant effectively inverted the calcaneus from its normal resting position. Mean differences, which were significant in frontal plane rotation (inversion around x-axis), measured 5.30° (SD = 2.96) ($p = 0.0001$). Mean transverse (z-axis), sagittal (y-axis) plane differences, and positional displacements of the calcaneus, with and without subtalar joint arthroereisis, were not significant.

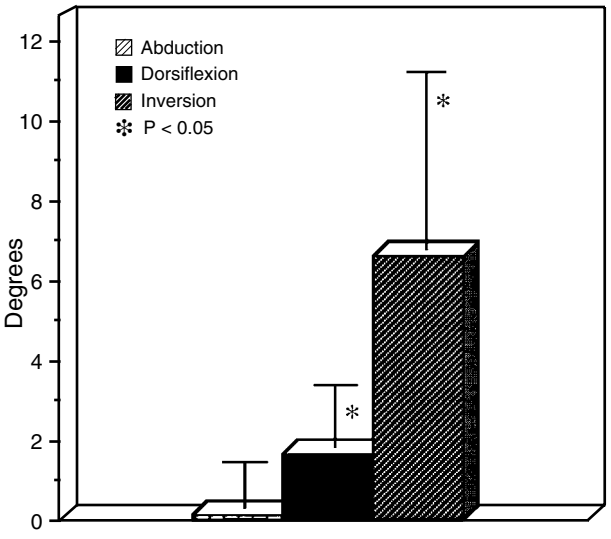

Figure 4. Navicular rotational displacement differences between loaded foot specimens with and without subtalar joint arthroereisis (n = 11) (error bar = one standard deviation).

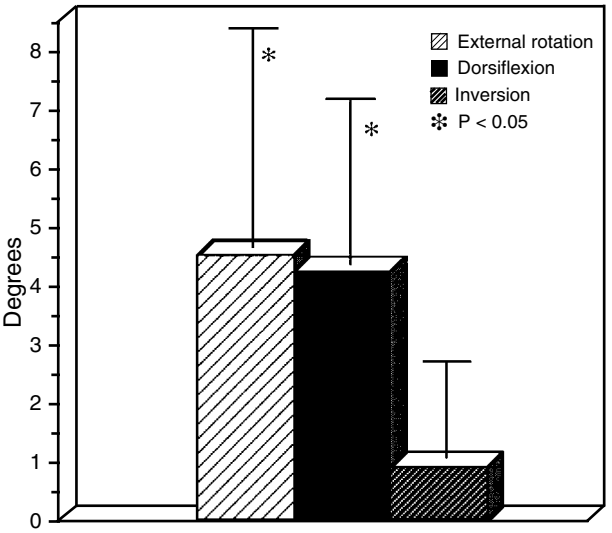

Figure 5. Talar rotational displacement differences between loaded foot specimens with and without subtalar joint arthroereisis (n = 11) (error bar = one standard deviation).

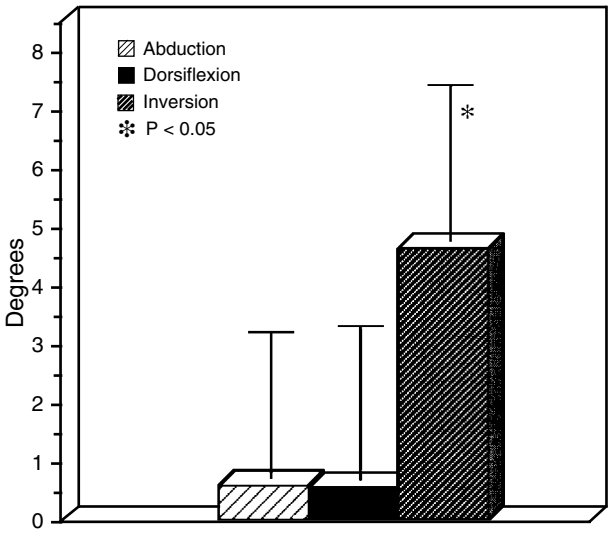

Figure 6. Cuboid rotational displacements differences between loaded foot specimens with and without subtalar joint arthroereisis (n = 11) (error bar = one standard deviation).

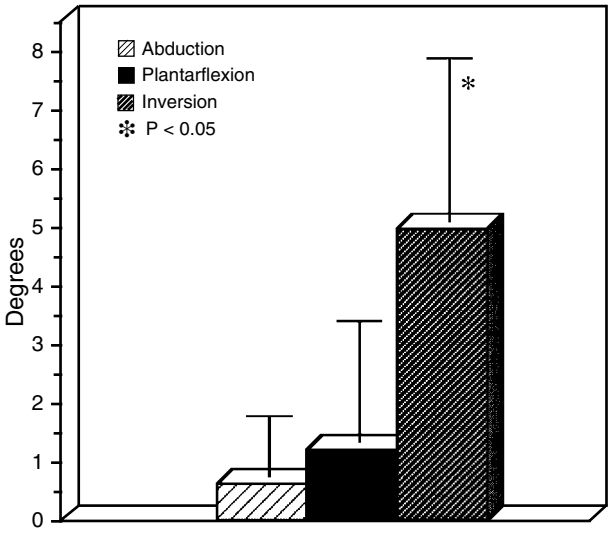

Figure 7. Calcaneal rotational displacements differences between loaded foot specimens with and without subtalar joint arthroereisis (n = 11) (error bar = one standard deviation).

Discussion

The pathologic condition of flatfoot is the most common foot deformity.[18] In severe cases, the foot is functionally inefficient and the deformity can lead to degenerative arthritis. The painful symptoms of those feet resistant to conservative care cause the individual to restrict certain physical activities. These feet often require surgical correction to improve foot function. However, determining the most effective procedure to correct the problem can be difficult for the surgeon given the complexity and variability of the deformity. Procedure selection is commonly based on the collective clinical experience of the surgeon. While imprecise clinical evidence through serial radiographs indicates that these procedures alter static foot position, investigations that more accurately define the kinematic effects of these treatments are not available[42, 45-47, 50, 52, 53] This investigation was undertaken to facilitate comprehension of the biomechanical effects of subtalar joint arthroereisis on the tarsus. The authors measured relative tarsal position and rotation changes in a cadaver foot model with and without subtalar joint arthroereisis. Testing was performed simulating a weightbearing foot in midstance phase of gait.

The results of this investigation revealed that there are distinct independent rotations for each tarsal bone during closed kinetic chain loading of the foot with subtalar joint arthroereisis. In individual specimens, small translational displacements after subtalar joint arthroereisis were detected and determined to be statistically insignificant. The concept of larger rotational movements combined with very small translational motion correlated well with kinematic investigations of the normal foot.[9-14] With the exception of the talus, each osseous segment measured appeared to have its own dominant plane of motion. In this sample series, the calcaneus primarily inverted while the talus dorsiflexed and externally rotated. These described motions are also consistent with descriptions of normal subtalar joint motion in a closed kinetic chain that involves frontal plane motion of the calcaneus with transverse and sagittal plane rotation of the talus.[9, 21] This investigation showed that with subtalar joint arthroereisis, the corrective movement of the tarsus occurs along the same directional parameters as published data on normal joints.[9-14] Additionally, the biomechanical influences of the implant did not appear to block independent movements across the subtalar joint.

Although the implant had direct contact with the talus and calcaneus, the remaining tarsal segments were also affected by this procedure through joint coupling. This caused a significant effect at the midtarsal joint. The navicular and cuboid bones inverted with subtalar joint arthroereisis. Additionally, navicular inversion was significantly greater ($p = 0.033$) and was coupled with dorsiflexory movement that was lacking in the cuboid. The dorsiflexory movement of the navicular that occurred with the supinatory action of the subtalar joint arthroereisis may appear to be contradictory to older, less precise investiga-

tions of midtarsal joint mechanics.[2, 5] However, it is consistent with more recent kinematical investigations.[9, 13] It must be reiterated that the measured rotations are in reference to the transmitter (ground) in a global coordinate system. While the navicular had a small amount of absolute dorsiflexion, a greater amount of dorsiflexion of the talus occurred simultaneously. This would explain the raising of the medial arch during supination while at the same time allowing for the relative plantar flexion at the talonavicular joint with subtalar joint arthroereisis. In this study, relative motion at the talonavicular joint after subtalar joint arthroereisis was greater than motion at other tarsal joints. This corresponded to previous publications that described similar findings with supination of normal feet.[9, 10, 13]

The navicular inverted in relation to the cuboid. This effect contradicted the assumption by Elftman[5] that the cuboid and navicular do not move independently. However, it is consistent with van Langelaan[9] and Lundberg[11] who observed small amounts of independent frontal plane motion between these two bones.

Inversion of the calcaneus, navicular, and cuboid relative to the talus placed a torsional effect across the midtarsal and subtalar joints. These movements, combined with intertarsal rotation between the navicular and cuboid, may apply tensile loads to adjacent ligaments and, in turn, place increasing compressive loads across joints of the rearfoot. These ligament-induced loads could alter the biomechanical properties of the midtarsal joint complex and may contribute to the "locking mechanism" of the midtarsal joint that results in midfoot stability in a less pronated position.

This investigation examined the effects of subtalar joint arthroereisis on the intact foot. Since flexible flatfeet have more deformity in the direction of pronation, it would be expected that the effect of subtalar joint arthroereisis would have similar directional findings with larger magnitudes. This has been confirmed clinically by various authors who reported large magnitude radiographic changes in talar declination angles.[45-47, 50, 53] However, additional investigation is warranted to fully understand these biomechanical relationships.

While surgical intervention of flexible flatfoot is commonly performed in children, the availability of anatomical specimens for this investigation restricted testing to adult feet. Notwithstanding, the closed kinetic chain mechanics with and without subtalar joint arthroereisis were consistent between both large and small feet. Based on these findings, the authors believe that similar mechanical relationships would be observed in the child's foot with a greater magnitude of change noted with the same size implant.

This investigation showed that subtalar joint arthroereisis has a physiologic supinatory influence on the tarsus during weightbearing, affecting triplane mechanics of the subtalar and midtarsal joint complexes. The resultant motions imparted by the implant on the tarsus are consistent with normal supinatory motions established by previous investgations. Therefore, based on kinematical data, the use of subtalar joint arthroereisis appears to be appropriately indicated in pathologic levels of flexible flatfoot.

Conclusion

These results confirm the supinatory effects of subtalar joint arthroereisis in a cadaver model. The normal closed kinetic chain mechanics appear to be intact. With subtalar joint arthroereisis, individual tarsal movements occurred as follows: 1) the talus externally rotated and dorsiflexed; 2) the navicular inverted and slightly dorsiflexed; 3) the cuboid and calcaneus inverted; and 4) the navicular inverted relative to the cuboid.

Acknowledgment. This investigation was supported by funds from Podiatric Medicine's Research Grant Program, American Podiatric Medical Association.

References

1. Fick R: "Spezielle Gelenk und Muskelmechanik," in *Handbuch der Anatomie und Mechanik der Gelenke*, Gustav Fischer, Jena, Germany, 1911.
2. Manter JT: Movements of the subtalar and transverse tarsal joints. Anat Rec **80:** 397, 1941.
3. Jones RL: The functional significance of the declination of the axis of the subtalar joint. Anat Rec **93:** 151, 1945.
4. Hicks JH: The mechanics of the foot: I. the joints. J Anat **87:** 345, 1953.
5. Elftman H: The transverse tarsal joint and its control. Clin Orthop **16:** 41, 1960.
6. Close JR, Inman VT, Poor PM, et al: The function of the subtalar joint. Clin Orthop **52:** 159, 1967.
7. Isman RE, Inman VT: Anthropometric studies of the human foot and ankle. Bull Pros Res **10:** 97, 1969.
8. Inman VT: *Joints of the Ankle*, Williams & Wilkins, Baltimore, 1976.
9. Van Langelaan EJ: A kinematical analysis to the tarsal joints. Acta Orthop Scand **54 (suppl 204):** 85, 1983.
10. Benink RJ: The constraint mechanism of the human tarsus. Acta Orthop Scand **56 (suppl 215):** 9, 1985.
11. Lundberg A: Kinematics of the ankle and foot: *In vivo* roentgen sterophotogrammetry. Acta Orthop Scand **60 (suppl 233):** 1, 1989.

12. LUNDBERG A, SVENSSON OK, BYLUND C, ET AL: Kinematics of the ankle/foot complex: part 1. plantarflexion and dorsiflexion. Foot Ankle **9:** 194, 1989.
13. LUNDBERG A, SVENSSON OK, BYLUND C, ET AL: Kinematics of the ankle/foot complex: part 2. pronation and supination. Foot Ankle **9:** 248, 1989.
14. LUNDBERG A, SVENSSON OK, BYLUND C, ET AL: Kinematics of the ankle/foot complex: part 3. influence of leg rotation. Foot Ankle **9:** 304, 1989.
15. YOUNG CS: Operative treatment of pes planus. Surg Gynecol Obstet **68:** 1099, 1939.
16. CHAMBERS EFS: An operation for the correction of flexible flatfoot of adolescents. West J Surg Obstet Gynecol **54:** 77, 1946.
17. HARRIS RI, BEATH T: Hypermobile flat-foot with short tendo achillis. J Bone Joint Surg **30A:** 116, 1948.
18. CREGO CH, FORD LT: An end-result study of various operative procedures for correcting flatfeet in children. J Bone Joint Surg **34A:** 183, 1952.
19. PRESSMAN MM: Biomechanics and surgical criteria for flexible pes valgus deformity. JAPA **63:** 582, 1973.
20. GANLEY JV: Calcaneo valgus deformity in infants. JAPA **65:** 405, 1975.
21. ROOT M, ORIEN W, WEED J: "Abnormal Function of the Foot," in *Normal and Abnormal Function of the Foot*, Clinical Biomechanics, Vol 2, Los Angeles, 1977.
22. BORDELON RL: Correction of hypermobile flatfoot in children by molded inserts. Foot Ankle **1:** 143, 1980.
23. BORDELON RL: Hypermobile flatfoot in children: comprehension, evaluation, and treatment. Clin Orthop **181:** 7, 1983.
24. MEREDAY C, DOLAN CME, LUSSKIN R: Evaluation of the University of California biomechanics laboratory shoe insert in "flexible" pes planus. Clin Orthop **82:** 45, 1972.
25. KIDNER FC: The prehallux (accessory scaphoid) in its relation to flatfeet. J Bone Joint Surg **11:** 831, 1929.
26. BECK EL, MCGLAMRY ED: Modified Young tendosuspension technique for flexible flatfoot: analysis of rationale and results. a preliminary report. JAPA **63:** 582, 1973.
27. SCHMIED HR: Spätresultate der knicksfußbehandlung durch die navikulare-umschlingung. Z Orthop Ihre Grenzgeb **104:** 309, 1968.
28. MILLER OL: A plastic flatfoot operation. J Bone Joint Surg **9:** 84, 1927.
29. HOKE M: An operation for the correction of extremely relaxed flat feet. J Bone Joint Surg **13:** 772, 1931.
30. GRICE DS: An extra-articular arthrodesis of the subastragalar joint for correction of paralytic flat feet in children. J Bone Joint Surg **34A:** 927, 1952.
31. JACK EA: Naviculo-cuneiform fusion in the treatment of flat foot. J Bone Joint Surg **35B:** 75, 1953.
32. GLEICH A: Beitrag zur operativen plattfußbehandlung. Arch Klin Chir **46:** 358, 1893.
33. LORD JP: Correction of extreme flatfoot. JAMA **81:** 1502, 1923.
34. EVANS D: Relapsed club foot. J Bone Joint Surg **43B:** 722, 1961.
35. SILVER CM, SIMON SD, LITCHMAN HM: Long-term follow-up observations on calcaneal osteotomy. Clin Orthop **99:** 181, 1974.
36. EVANS D: Calcaneo-valgus deformity. J Bone Joint Surg **57B:** 270, 1975.
37. JACOBS AM, OLOFF L, VISSER HJ: Calcaneal osteotomy in the management of flexible and nonflexible flatfoot deformity: a preliminary report. J Foot Surg **20:** 57, 1981.
38. ANDERSON AF, FOWLER SB: Anterior calcaneal osteotomy for symptomatic juvenile pes planus. Foot Ankle **4:** 274, 1984.
39. PHILLIPS GE: A review of elongation of os calcis for flat feet. J Bone Joint Surg **65B:** 1515, 1983.
40. DOLLARD MD, MARCINKO DE, LAZERSON A, ET AL: The Evans calcaneal osteotomy for correction of flexible flatfoot syndrome. J Foot Surg **23:** 291, 1984.
41. MAHAN KT, MCGLAMRY ED: Evans calcaneal osteotomy for flexible pes valgus deformity. Clin Podiatr Med Surg **4:** 137, 1987.
42. SANGEORZAN BJ, MOSCA V, HANSEN ST: Effect of calcaneal lengthening on relationships among the hindfoot, midfoot, and forefoot. Foot Ankle **14:** 136, 1993.
43. SUBOTNIK SI: The subtalar joint lateral extra-articular arthroereisis: a preliminary report. JAPA **64:** 701, 1974.
44. SUBOTNIK SI: The subtalar joint lateral extra-articular arthroereisis: a follow-up report. JAPA **67:** 150, 1977.
45. SMITH RD, RAPPAPORT MJ: Subtalar arthroereisis: a four-year follow-up study. JAPA **73:** 356, 1983.
46. SMITH SD, MILLAR EA: Arthrorisis by means of a subtalar polyethylene peg implant for correction of hindfoot pronation in children. Clin Orthop **181:** 15, 1983.
47. SMITH SD, WAGREICH CR: Review of postoperative results of the subtalar arthroeresis operation: a preliminary study. J Foot Surg **23:** 253, 1984.
48. CHIAPPARA P, VERRINA F, DAGNINO G, ET AL: The surgical treatment of mobile valgus flat foot in children. Ital J Orthop Traumatol **10:** 469, 1984.
49. GIANNINI S, GIROLAMI M, CECCARELLI F: The surgical treatment of infantile flat foot: a new expanding endo-orthotic implant. Ital J Orthop Traumatol **11:** 315, 1985.
50. LUNDEEN RO: The Smith STA-Peg operation for hypermobile pes planovalgus in children. JAPMA **75:** 177, 1985.
51. DOCKERY GL: Surgical treatment of the symptomatic juvenile flexible flatfoot condition. Clin Podiatr Med Surg **4:** 99, 1987.
52. VILADOT A: Surgical treatment of the child's flatfoot. Clin Orthop **283:** 34, 1992.
53. TOMPKINS MH, NIGRO JS, MENDICINO S: The Smith STA-Peg: a 7-year retrospective study. J Foot Ankle Surg **32:** 27, 1993.
54. *Polhemus Fastrack 3Space Manual*, Polhemus Inc, Colchester, VT, 1992.
55. LAMBERT KL: The weight-bearing function of the fibula: a strain gauge study. J Bone Joint Surg **53A:** 507, 1971.
56. TAKABE K, NAKAGAWA A, MINAMI H, ET AL: Role of the fibula in weight-bearing. Clin Orthop **189:** 289, 1984.