Slipped Capital Femoral Epiphysis in a 12-Year-Old Male

To the Editor:

The etiology of slipped capital femoral epiphysis is not fully understood and has been reported to include trauma, arthritis deformans, rickets, surgical trauma, mechanical stress, coxa vara, rapid growth, imbalance of hormones, loosening of the epiphysis caused by trauma, and osteomalacia.[1] It is widely accepted that the basic etiologic process weakens the epiphyseal plate and makes it more vulnerable to the shearing forces present during walking and running.[2]

One common way to classify slipping of the capital femoral epiphysis is by the degree of slipping evident on the radiographs. Mild slipping, moderate slipping, severe slipping, and the late or residual stage is a classification that aids in diagnosis and treatment.[3] A similar classification, acute, acute-on-chronic, or chronic slip, is based on the duration of symptoms before treatment.

Treatment of slipped capital femoral epiphysis has many variations with the basic purpose to favor healing of the lesion, correct displacement, maintain satisfactory position of the epiphysis, correct residual deformity, or to salvage a bad hip. The wide array of treatment consists of endocrine therapy, bed rest, traction, various types of immobilization with crutches and braces, open reduction with internal fixation, and various osteotomies.[4]

Untreated, the condition may result in severe restriction of motion caused by aseptic necrosis of the femoral head, chondrolysis, and degenerative joint disease.

Clinical Presentation

Slipped capital femoral epiphysis presents in individuals from 14 to 18 years of age. The condition is 2 to 4 times more prevalent in boys than girls and appears to occur in children who are heavier than others of the same age.[3] There occurs, without special cause or the result of any preceding painful trauma of the hip, a limp, weariness, and gradual shortening of the affected limb.[5] The symptoms develop gradually and attain no special intensity that might confine the individual to extended bed rest.[5] The patient is otherwise healthy and may present to the podiatric physician with vague complaints of hip or inguinal pain that is usually aggravated by activity and relieved with rest.

It is important that the podiatric physician be aware of such conditions and to differentiate the many possible etiologies of generalized hip pain in young individuals. Clinically, there is no swelling; instead, with further progress, atrophy sets in.[5] The limb, in addition, outwardly rotates to a limited degree with some contraction at the hip; movement at the hip, especially flexion, is but little diminished, and rotation and abduction are somewhat restricted.[5]

Roentgenologic examination for confirmatory purposes consists of an anteroposterior, abduction-external rotation and lateral radiographs.[6] Bilateral hip views are used for comparison, to rule out bilateral disease or preslip of the contralateral hip.

Case Presentation

A 12-year-old active male presented to the orthopedic clinic of the Foot and Ankle Institute in August 1993. The patient presented with his parents who were concerned with limping and a concurrent pain of the child's groin and entire right lower extremity of approximately 1 year's duration. The patient described the pain as an aching pain aggravated by continued walking and physical activity, inhibiting the patient from participating in sports and physical activity. Pain was relieved with rest. The patient did not relate any trauma to the area.

The patient's medical history was unremarkable for any major illness or injury. He had been hospitalized for hypospadias surgery to correct the developmental anomaly in which the urethra opens on the underside of the penis. Previous injury consisted of a fracture of his nose when he was kicked by a horse.

Physical examination revealed a healthy, well nourished, 12-year-old male. Orthopedic examination revealed limited internal range of motion at the right hip. External range of motion at the right hip was within normal limits. The left hip was within normal limits for both internal and external range of motion. A gastrocnemius soleus equinus was evident in the right lower extremity. A limb length discrepancy was noted with the right extremity measuring 93.5 cm and the left extremity measuring 92.5 cm. Biomechanically, the patient presented with a Trendelenburg gait to the right. He walked with his right foot externally rotated.

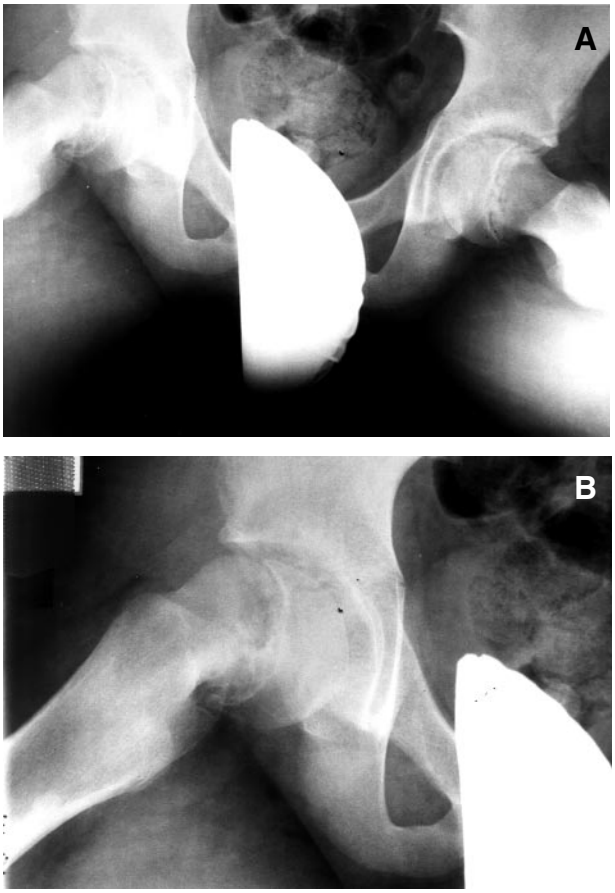

Figure 1. A, Slippage of the left epiphysis with femoral neck, remodeling. B, Close-up view of right hip.

A differential diagnosis of hip dyspalsia, aseptic necrosis of the femoral head, soft tissue deformity consisting of inguinal hernia, and slipped capital femoral epiphysis was postulated. At this time, the patient was referred to a sports orthopedist for evaluation. On September 8, 1993, the patient was evaluated by a sports orthopedist and a diagnosis of slipped capital femoral epiphysis was made.

Based on radiographs, it was noted that a chronic slippage had been going on and there was some remodeling of his neck (Fig. 1). The slippage was mostly posterior and there was little inferior component to it. The other hip appeared normal. One treatment recommendation consisted of having the hip percutaneously pinned. He would then be on crutches for 6 weeks with partial weightbearing. After that, he would be allowed to walk, but not run or jump, until fusion across the area of his growth plate was visible. The patient was put on crutches nonweightbearing on his right leg until his surgery.

Surgery was performed September 16, 1993, without complication. Two cannulated screws were used to fix his right femoral head to the neck (Fig. 2).



Figure 2. Fixation of right femoral head to the neck with two cannulated screws.

At 1 week postoperatively, the patient had limited hip motion and some soreness about his hip. He continued walking on crutches and was allowed to put partial weight on his leg.

At 1 month postoperatively, the patient continued to do well. He regained his hip motion and had full hip flexion and no hip flexion contracture.

Two weeks later, he was removed from his crutches and allowed to walk around normally, ride his bike, and swim.

The screw fixation was unremarkable 9 months later. The examination of his left hip was unchanged. At this time, it was suggested that the screws be removed as the epiphysis had healed around the screws, so the growth plate should be stable. It should be noted that there was suspected pre-slip of the contralateral epiphysis, at which time it was recommended to monitor the epiphysis for abnormal changes. The patient was able to return to full activity with no pain or disability.

HOWARD J. PALAMARCHUK, DPM
SCOTT M. ARONSON, DPM
Pennsylvania College of
Podiatric Medicine
Eighth at Race St
Philadelphia, PA 19107

References

1. HOWORTH B: Etiology: slipping of the capital epiphysis. Clin Orthop **48**: 49, 1966.

2. KORN MW, STATES JD: Slipping of the capital femoral epiphysis: a long term follow-up and review of cases in Rochester, New York. Clin Orthop **48**: 119, 1966.
3. BIANCO A: Treatment of slipping of the capital femoral epiphysis: Clin Orthop **48**: 103, 1966.
4. HOWORTH B: Treatment: slipping of the capital femoral epiphysis. Clin Orthop **48**: 53, 1966.
5. MULLER E: The classic: on the deflection of the femoral neck in childhood. Clin Orthop **48**: 7, 1966.
6. COWELL H: The significance of early diagnosis and treatment of slipping of the capital femoral epiphysis. Clin Orthop **48**: 89, 1966.