Role of the Plantar Fascia in Digital Stabilization

A Case Report

JANE PONTIOUS, DPM*
K. PAUL FLANIGAN, BA†
HOWARD J. HILLSTROM, PhD‡

The plantar aponeurosis is a ligamentous structure that extends from the calcaneus to the proximal phalanges. Under tension, it functions to support the longitudinal arch, supinate the rearfoot, and stabilize the digits against the ground. The anatomy and biomechanics of the plantar fascia and plantar aponeurosis, particularly their role in digital stabilization, are reviewed. A case is presented showing a patient who developed hammer toes as a postoperative complication after having a portion of the plantar aponeurosis removed.

The plantar aponeurosis is an important functional ligament spanning the length of the foot. It plays an essential role in foot stability and arch morphology and contributes to many pathologies and syndromes common in podiatric medical practice. It can be likened to a tie rod maintaining the beams of an arch. Lapidus[1] introduced this concept when he compared the foot with a truss, with the rearfoot (talus and calcaneus) acting as the posterior strut and the metatarsals as the anterior strut. When the apex of the truss is loaded, the struts are under compression and the tie rod is under tension resisting collapse.[1,2]

The stability of the longitudinal arch in static stance is primarily achieved through bony and ligamentous structures. Electromyographic studies have shown that muscles do not contribute significantly to supporting the arch.[3] In a recent study, Huang et al[4] evaluated the specific role that the plantar fascia has in longitudinal arch stability. They measured the vertical and horizontal dimensions of the arch under talotibial loading after sectioning the plantar fascia, plantar ligaments, and the spring ligament in cadaveric feet. The greatest displacement in arch height was found after sectioning the plantar fascia. Therefore, they concluded that the plantar fascia is the most important factor in maintenance of the medial longitudinal arch.

Surgical disruption of the aponeurosis is often performed to relieve intractable plantar fasciitis or heel spur syndrome, or to remove soft tissue masses. A thorough understanding of the anatomy and function of the structure is imperative. The surgeon should be aware that sectioning the plantar fascia may lead to collapse of the arch, pes planus, and associated pathology.

Anatomical Considerations

The plantar fascia is a dense band of predominantly longitudinally arranged fibers that extend from the calcaneus to the forefoot. It consists of medial, central, and lateral bands corresponding to the three compartments of the foot. These compartments are separated from one another by extensions of the plantar fascia (the medial and lateral longitudinal septa) that run deep and connect

*Assistant Professor, Department of Surgery, Pennsylvania College of Podiatric Medicine, Philadelphia.

†Submitted during fourth year, Pennsylvania College of Podiatric Medicine, Philadelphia.

‡Director, Gait Study Center, and Associate Professor, Department of Orthopedics and Community Health and Aging, Pennsylvania College of Podiatric Medicine, Philadelphia.

Mailing address: Eighth at Race St, Philadelphia, PA 19107.

to bones. The medial and lateral bands are simply fascial coverings of the abductor hallucis and abductor digiti minimi muscles, respectively. The central portion is the most prominent and lies superficial to the flexor digitorum brevis. It is the central portion that is considered to be the true plantar aponeurosis.[5, 6]

The plantar aponeurosis is roughly triangular shaped with its base distal and apex proximal. It is thickest proximally where it bears a strong attachment to the plantar medial aspect of the medial calcaneal tubercle. Bøjsen-Möller and Flagstad[7] have described this structure extensively. The plantar aponeurosis divides distally into five longitudinally oriented tracts, with each tract further dividing into superficial and deep tracts just proximal to the metatarsal heads. The most medial and lateral superficial tracts course to the medial and lateral margins of the foot. The three central superficial tracts extend in the direction of the toes and reach the space between the first and second toes, base of the third toe, and space between the fourth and fifth toes. Here most of these fibers course plantarly and insert into the skin, while others deviate and run transversely. None of the fibers reaches as far as the skin crease between the ball of the foot and the toes.

Bøjsen-Möller and Flagstad further describe each deep tract as dividing into pairs of sagittal septa. There are two sagittal septa for each toe. The septa pass on the tibial and fibular sides of the flexor tendons, creating a sheath through a series of small crisscrossing arches. These fibers insert into the interosseous fascia, the fascia of the transverse head of adductor hallucis, and the deep transverse metatarsal ligament. Fibers then combine with the plantar capsules and ligaments of the metatarsophalangeal joints to form the plantar plate, providing a firm attachment to the base of the proximal phalanges (Fig. 1).[7, 8]

Biomechanical Function

The windlass mechanism accurately describes the function of the plantar aponeurosis. The proximal phalanx represents the handle that wraps the plantar aponeurosis around the metatarsal head corresponding to the drum or pulley. Hicks[9] developed this concept when he noticed that passive extension of the proximal phalanx tightens the plantar fascia, supinates the rearfoot, externally rotates the leg, and increases the height of the arch. He analyzed this mechanism in living and cadaveric specimens and noticed this function to be lost when the plantar aponeurosis was sectioned.

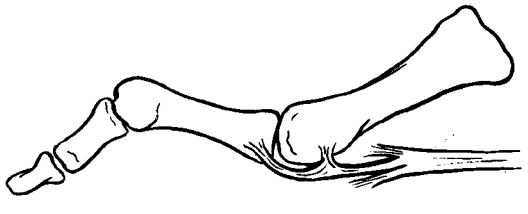

Figure 1. Attachments of the plantar aponeurosis and plantar plate to the base of the proximal phalanx.

A working knowledge of the anatomical attachments of the plantar fascia is essential in understanding this mechanism. With hyperextension of the proximal phalanx, the plantar aponeurosis attempts to draw the calcaneus forward. This action shortens the distance between the drum (metatarsal head) and calcaneus. The calcaneus, however, does not move forward in static stance. Instead, the metatarsal head plantarflexes and moves proximally, thereby increasing the arch height. Additionally, because of the proximal attachment to the plantar medial calcaneal tubercle, any increase in tension to the plantar aponeurosis will act to assist in supination by inverting the rearfoot. This effect is most profound with extension of the great toe, because the first metatarsal head creates a pulley that is of larger diameter than the lesser metatarsals.

In the gait cycle, the windlass functions during the propulsive period. As the heel lifts off the supporting surface, the toes remain fixed and are passively extended. Just prior to toe-off, the proximal phalanx maximally extends on the metatarsal head and the plantar aponeurosis is under its greatest tension during the gait cycle. The arch rising and supinatory effects of this mechanism contribute in changing the foot from a mobile adaptor at heel contact to a more stable rigid lever in propulsion.

The windlass mechanism works also in reverse. On weightbearing, the arch tends to flatten as the foot elongates. This generates increased tension in the plantar aponeurosis, which unwinds the windlass, transmitting a plantarflexory force to the proximal phalanx. Hicks[9] noticed that this also disappeared when the plantar aponeurosis was divided (Fig. 2).[8]

Scheck[10] analyzed the reverse effect of the windlass by isolating the plantar aponeurosis in cadaver specimens after eliminating all of the insertions of the intrinsic and extrinsic flexors. Applying a proximal tension to the plantar aponeurosis, he discovered the proximal phalanx reduces and flexes. Scheck cites Fick as having observed that weightbearing tenses the plantar aponeurosis, which causes the toes to plantarflex.

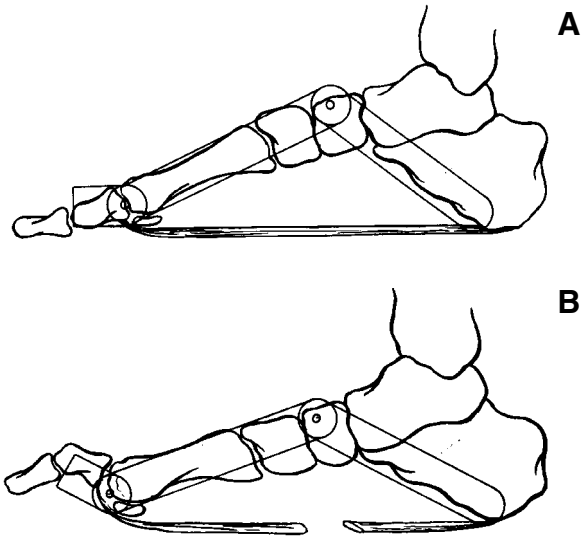

Figure 2. Illustrations simulating the windlass mechanism in reverse. A, Weightbearing tenses the plantar aponeurosis, thereby providing a stabilizing force to the proximal phalanx in the direction of plantarflexion. B, When the plantar aponeurosis is sectioned, this force is lost.

Case Report

A 53-year-old female presented to the Foot and Ankle Institute with a concern of contracted toes and pain in the ball of the right foot. The patient first noticed the toes beginning to "curl and atrophy" after surgical removal of a mass on the plantar aspect in the same foot 2 years prior to this presentation. The degree of contracture progressively increased to the point at which the toes were unable to be manually straightened. Likewise, the pain in the ball of the foot progressively increased and was exacerbated by weightbearing. Past medical history and review of systems were unremarkable and noncontributory.

Resection of a plantar fibroma from the plantar aspect of her right foot and a resection of a neuroma in the third intermetatarsal space were performed. The surgery was performed at another institution. The operative report stated that a large curvilinear incision 7 cm in length was used on the plantar aspect of the patient's right foot to gain access to the fibroma. A portion of the plantar aponeurosis including the plantar fibroma, measuring $3 \times 2.5 \times 1$ cm, was excised.

Physical examination revealed vascular status to be within normal limits. There was a decrease in epicritic sensation in the third toe web space of the right foot consistent with the neuroma removal, while muscle strength about the lower extremities was adequate and symmetrical. Patellar and Achilles reflexes were within normal limits bilaterally. The integument was grossly intact, noting the residual scar in the arch and some minor diffuse hyperkeratosis at the ball of the right foot. Subtalar, midtarsal, and first metatarsophalangeal joint range of motion were within normal limits; however, ankle joint dorsiflexion was limited bilaterally because of equinus.

While the patient rested in the examination chair, all of her toes appeared to be contracted. However, on weightbearing, the toes of the left foot reduced to a rectus configuration, while the toes of the right foot hammered (Fig. 3). Additionally, while standing in resting calcaneal stance position, a decrease in longitudinal arch height was noted on the right foot when compared with the left. The second through fifth digits of the right foot were nonreducible on manual distraction suggesting rigid hammer toe deformity. Radiographic evaluation of the right foot revealed severe contractures of the lesser digits and a decrease in arch height suggesting pronatory changes (Fig. 4).

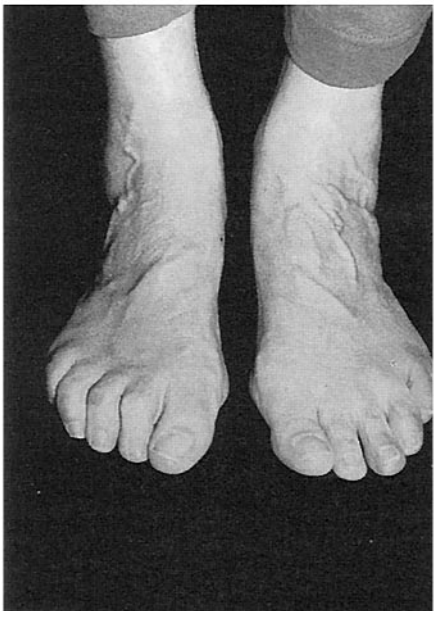

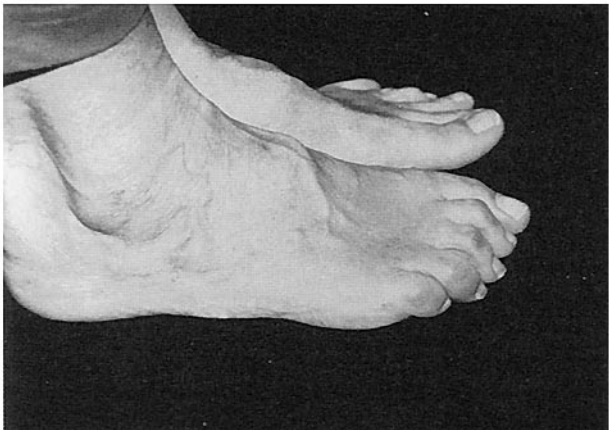

Figure 3. Clinical photographs showing unilateral hammer toe deformity.

Objective Gait Analysis

Qualitative slow motion video analysis was performed in the sagittal and frontal planes and dynamic plantar pressure studies were conducted bilaterally during comfortable cadence locomotion. Using the Musgrave Footprint®[1] system, bilateral pressures of the plantar aspect and associated biomechanical parameters were quantified. Pressures can range from 0 to 15 kg/cm^2. Pressures in excess of 10 kg/cm^2 are potentially pathologic.[11, 12]

The center of pressure curve for the left foot was variable but tended to be mildly overpronated, whereas the center of pressure line for the right foot was excessively medially deviated indicating significant overpronation (Fig. 5). Pressures of the plantar aspect of the left foot were within normal limits, while pressures up to 15 kg/cm^2 were recorded for the right foot corresponding to the metatarsal heads (Fig. 6).

In Figure 7, the vertical force *versus* time is depicted. Normally, a "double-humped camel" type waveform should be noted whereby the first peak corresponds to heel contact and the second peak corresponds to push-off. These two peaks should be symmetrical within a given limb and between limbs. This patient showed a more forceful push-off of the right foot consistent with retrograde loading as seen in hammer toe deformities.

Discussion

The history, physical examination, and objective gait analysis reveal that this patient has developed hammer toe deformities of her right foot as a postoperative complication from excision of the plantar fibroma. Additionally, analysis using the Musgrave Footprint System supports clinical observation by suggesting the right foot is significantly overpronating throughout the stance phase of gait. Increased pressures plantar to the metatarsal heads of the right foot were noted as expected because of the retrograde buckling of the hammer toes.

The extended position of the proximal phalanx has been described as the cardinal feature in the development of the hammer toe deformity.[10, 13] Inefficiency of the plantar structures, the intrinsic muscles, joint capsules, and the plantar aponeurosis may all contribute to a proximal phalanx that rests in an extended position while weightbearing.

Of these, Coughlin[14, 15] describes the plantar plate and aponeurosis as the most significant factors in stabilizing the proximal phalanx against the supporting surface. McGlamry[16] correlates failure of the plantar aponeurosis to load with floating toe syn-

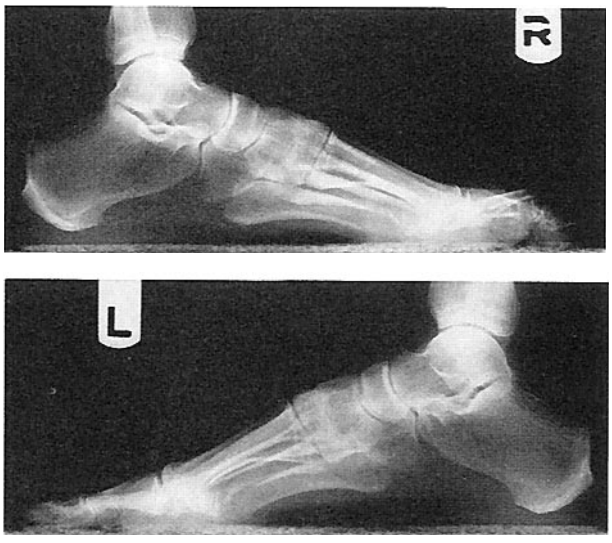

Figure 4. A, Lateral radiograph of the right foot showing contractures of the lesser digits and decrease in arch height. B, Lateral radiograph of the left foot for comparison.

®[1]WM Automation and Preston Communication Ltd, North Wales, United Kingdom.

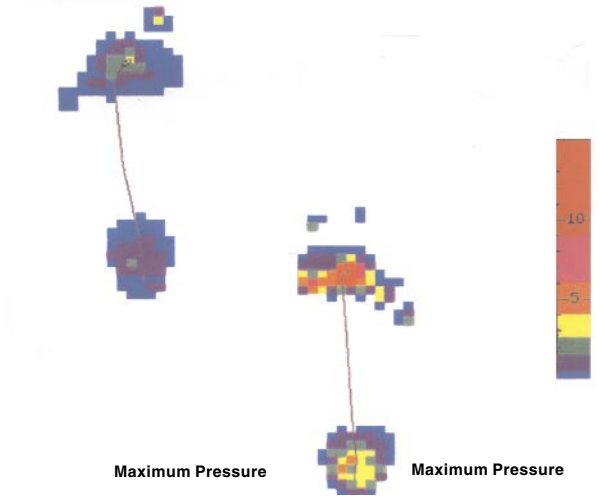

Figure 5. Center of pressure curves for both feet. Note the curve for the right foot reveals significant overpronation.

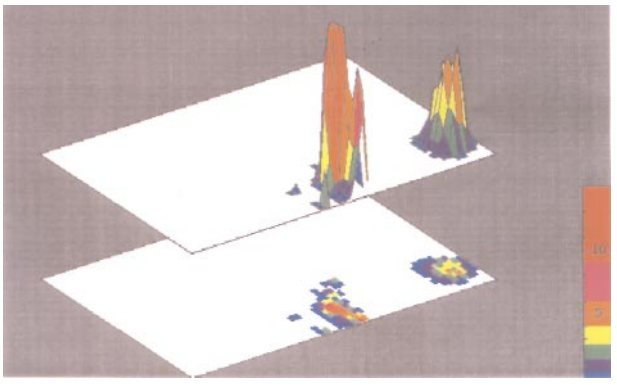

Figure 6. Graphical representation of pressures of the plantar aspect of the right foot. Note the excessive forefoot pressures.



Figure 7. Vertical force *versus* time and corresponding Musgrave Footprint for the right foot. The curve indicates a more forceful push-off.

drome, when the toe fails to purchase the ground. The plantar aponeurosis and plantar plate normally provide a passive static resistance to dorsiflexion or extension of the toes. The plantar aponeurosis simply tightens by virtue of its attachments through tension generated by lengthening the longitudinal arch while in stance. In this case, a deficit in the structural integrity of the plantar aponeurosis, created by surgical excision, rendered it inefficient in providing this plantarflexory force to the digits.

Additionally, the partial fasciectomy effectively lowered the longitudinal arch height, which resulted in a right foot that now functions overpronated. When the foot is significantly pronated in the gait cycle, flexor stabilization occurs as the longs flexors fire with greater force for a longer duration in an effort to resupinate the foot in late midstance and into propulsion. It is logical to assume that the combination of the plantar aponeurosis failing to provide a plantarflexory force to the proximal phalanx and flexor stabilization have facilitated the development of the hammer toe deformity.

Summary

A case report was presented that suggested the development of hammer toes as a postoperative complication to partial plantar fasciectomy. The plantar aponeurosis serves an important function in resisting collapse of the foot as a whole and plays an important role in digital stabilization. Disrupting the integrity of the plantar aponeurosis may result in a flattened arch contour, decreased toe purchase, and a foot that functions more pronated throughout the stance phase of gait. The surgeon should be aware that hammer toes and other symptomatology associated with pes planus may occur when part or all of the plantar aponeurosis is released.

References

1. Lapidus PW: Kinesiology and mechanical anatomy of the tarsal joints. Clin Orthop **30**: 20, 1963.
2. Sarrafian SK: Functional characteristics of the foot under tibiotalar loading. Foot Ankle **8**: 4, 1987.
3. Basmajian JV, Stecko G: The role of muscles in arch support of the foot: an electromyographic study. J Bone Joint Surg **45A**: 1184, 1963.
4. Huang CK, Kitaoka HB, An KN, et al: Biomechanical evaluation of longitudinal arch stability. Foot Ankle **14**: 353, 1993.
5. Hollingshead WH, Rosse C: "The Leg and the Foot," in *Textbook of Anatomy*, 4th Ed, JB Lippincott, Philadelphia, 1985.
6. Mitchell IR, Meyer C, Krueger WA: Deep fascia of the foot: anatomical and clinical considerations. JAPMA **81**: 373, 1991.
7. Bøjsen-Möller F, Flagstad KE: Plantar aponeurosis and internal architecture of the ball of the foot. J Anat **121**: 599, 1976.
8. Sarrafian SK: *Anatomy of the Foot and Ankle: Descriptive, Topographic, Functional*, 2nd Ed, JB Lippincott, Philadelphia, 1993.
9. Hicks JH: The mechanics of the foot: II. the plantar aponeurosis and the arch. J Anat **88**: 25, 1954.
10. Scheck M: Etiology of acquired hammer toe deformity. Clin Orthop **123**: 63, 1977.
11. Boulton AJM, Hardisty CA, Betts RP, et al: Dynamic foot pressure and other studies as diagnostic and management aids in diabetic neuropathy. Diabetes Care **6**: 26, 1983.
12. Boulton AJM, Betts RP, Franks CI, et al: Abnormalities of foot pressure in early diabetic neuropathy. Diabetic Med **4**: 225, 1987.
13. Kelikian H: "Deformities of the Lesser Toes," in *Hallux Valgus: Allied Deformities of the Forefoot and Metatarsalgia*, WB Saunders, Philadelphia, 1965.
14. Coughlin MJ: Lesser toe deformities. Orthopedics **10**: 63, 1987.
15. Coughlin MJ: Mallet toes, hammertoes, claw toes, and corns. Postgrad Med **75**: 191, 1984.
16. McGlamry ED: Floating toe syndrome. JAPA **72**: 561, 1982.