Journal of the
American Podiatric Medical Association

MDPI

Case Report

Solitary Osteochondroma of the Cuboid in an Adult Male: A Case Report

Sandeep Kumar Yadav [1], Sammarjanki Rymbai [1,*], Rajesh K. Rajnish [1] and Meenakshi Rao [2]

[1] Department of Orthopaedics, All India Institute of Medical Sciences (AIIMS), Jodhpur 342005, Rajasthan, India; sandy22987@gmail.com (S.K.Y.)
[2] Department of Pathology, All India Institute of Medical Sciences (AIIMS), Jodhpur 342005, Rajasthan, India
* Correspondence: maryandkhar@gmail.com

Abstract

Osteochondromas are the most common benign bone tumors, arising as cartilage-capped bony outgrowths near growth plates. They are mostly treated conservatively unless symptomatic. Their occurrence in the foot and ankle is rare, particularly in flat bones such as the cuboid. We report a case of an adult male who presented with progressive pain and swelling over the right midfoot on the plantar aspect. On physical examination, a firm, nonmobile bony mass is felt on the plantar surface. Radiographs and MRI demonstrated an exophytic lesion arising from the cuboid bone with a thin cartilaginous cap, consistent with osteochondroma. Complete surgical excision was performed, and postoperative recovery was uneventful. At one-year follow-up, the patient was asymptomatic with full functional restoration.

Keywords: case report; osteochondroma; cuboid

1. Introduction

Osteochondromas, also known as exostoses, are benign cartilage-capped bony projections that originate from bones formed through endochondral ossification [1]. These lesions account for approximately 20–50% of all benign bone tumors and typically manifest during the second or third decade of life, coinciding with the age of skeletal maturity, with a higher prevalence in males [2,3]. Most commonly, osteochondromas develop at the metaphyseal–diaphyseal junctions of long bones, including the femur, tibia, humerus, and flat bones such as the scapula [3]. Their occurrence in the foot and ankle is rare, at less than 1% of cases. In the foot, they are most commonly found in short tubular bones like the metatarsals and phalanges [3,4]. While solitary lesions predominate, the occurrence of multiple osteochondromas suggests hereditary multiple exostoses (HMEs), an autosomal dominant disorder associated with mutations in the *EXT-1* and *EXT-2* genes [3].

Most osteochondromas are asymptomatic and present as a painless hard lump on the bony surface, which causes cosmetic issues [4]. Symptomatic presentations result from complications like mechanical impingement of adjacent structures, skeletal deformity, pathological fracture, neurovascular compromise, or malignant transformation [5]. Osteochondromas in the foot produce symptoms early due to external pressure from footwear, which exacerbates the clinical manifestations, precipitating reactive bursa formation or integumentary breakdown [6].

While osteochondromas affecting the foot and ankle region have been documented in the literature, the calcaneus and talus represent the predominant anatomical sites. Our case

Check for updates

Academic Editor: Warren S. Joseph

Received: 27 September 2026
Revised: 10 November 2026
Accepted: 17 November 2026
Published: 25 November 2026

Copyright: © 2026 by the authors. Published by MDPI on behalf of the American Podiatric Medical Association. Licensee MDPI, Basel, Switzerland. This article is an open access article distributed under the terms and conditions of the Creative Commons Attribution (CC BY) license.

described an uncommon presentation of solitary osteochondroma of the cuboid in a young adult, thereby underscoring the importance of comprehensive diagnostic evaluation and judicious consideration of surgical management.

2. Case Presentation

A 28-year-old male presented to our tertiary care hospital with a two-year history of progressively increasing pain and swelling over the plantar aspect of the right midfoot. The swelling had gradually increased in size and was associated with dull, aching pain, occasionally accompanied by shooting sensations. The pain was aggravated by weight-bearing and walking and was relieved by rest. Over time, the patient experienced increasing difficulty in ambulation and had recently discontinued sports activities because of pain and discomfort during physical activity. There was no history of preceding trauma, local infection, or previous surgery involving the affected foot. His past medical history was otherwise unremarkable.

2.1. Clinical Findings

On physical examination, a well-defined, firm-to-hard, nonmobile swelling measuring approximately 5 cm × 4 cm was observed over the plantar aspect of the left midfoot (Figure 1). The swelling was tender on palpation, with no evidence of local warmth. The overlying skin was normal, without discoloration, erythema, ulceration, or adherence to the underlying mass. There were no clinical signs of vascular compromise, and distal pulses were palpable. Neurological examination revealed preserved sensory and motor functions of the affected foot.

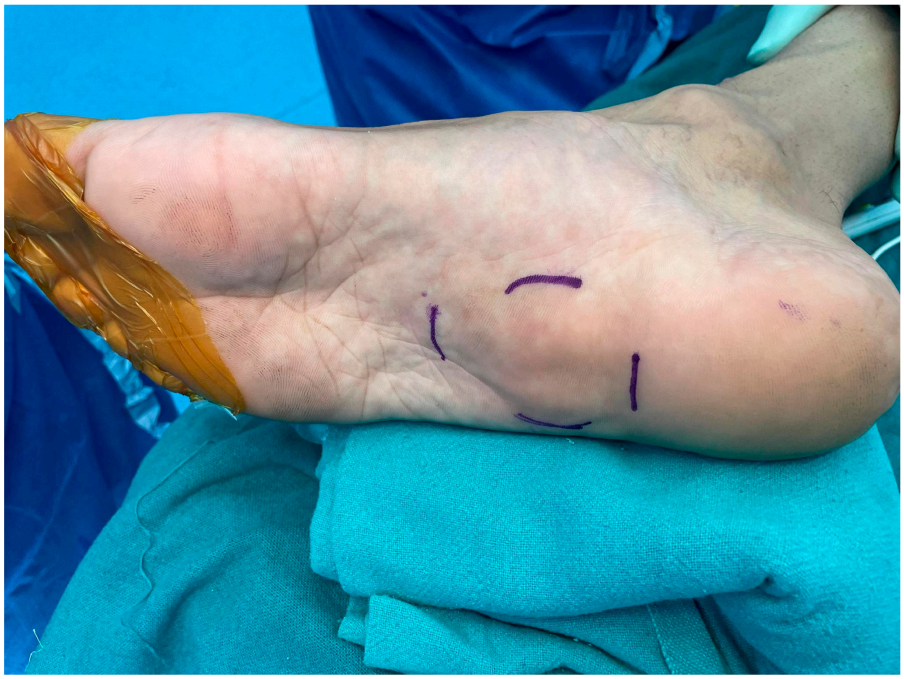

Figure 1. Clinical image of a hard, non-mobile mass on the plantar aspect of the foot.

2.2. Diagnostic Approach

Anteroposterior, medial-oblique, and lateral radiographs were obtained, and they showed bony outgrowth originating from the cuboid with articular irregularity (Figure 2). Magnetic resonance imaging (MRI) in axial, sagittal, and coronal T2-weighted sequences with fat saturation showed a large solitary osteochondroma on the medial plantar surface of the cuboid. It measured 4.7 cm × 5.5 cm × 2.5 cm (AP × Trans × SI) with a cartilaginous

cap of 2 mm thickness surrounding its plantar surface, marked stretching of the overlying soft tissue, and neurovascular compression leading to tissue edema with stretching and displacement of the long flexor tendons. No features of high-grade lesion or malignant transformation were noted (Figure 3). A CT scan was performed to confirm its location and for preoperative planning to identify the stalk. CT scan demonstrated a well-circumscribed, exophytic bony outgrowth arising from the medial plantar cortex of the cuboid bone measuring approximately [4.7 cm × 5.5 cm × 2.5 cm]. The lesion exhibits unambiguous continuity of both its cortex and medullary cavity with the underlying parent cuboid bone (Figure 4).



Figure 2. Radiographs of the foot in AP, lateral, and oblique views showed bony outgrowths on the medial plantar aspect of the cuboid with medullary continuity.

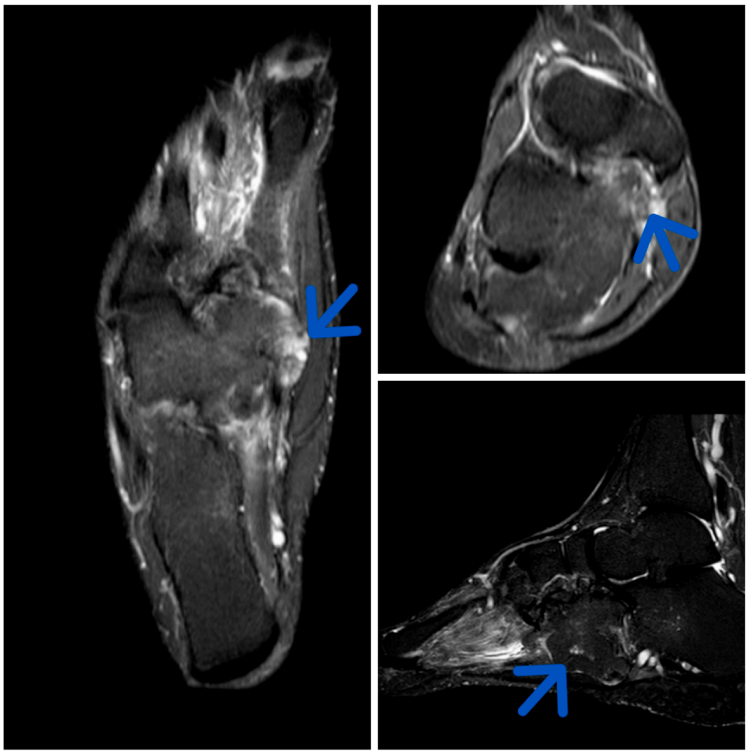

Figure 3. MRI T2 fat saturation in axial, coronal, and sagittal planes showing a large solitary osteochondroma of the medial plantar surface of the cuboid. Arrow showing the lesion arising from the cuboid.



Figure 4. CT scan showing a bony protrusion from the medial plantar aspect of the cuboid with medullary continuation, with a small pedunculated fragment obscuring the main stalk (arrow).

2.3. Surgical Intervention

Surgical intervention was undertaken following failure of conservative management. Non-operative treatment, including activity modification, footwear modification, and analgesics/NSAIDs, failed to provide adequate symptomatic relief, and the patient continued to experience pain and progressive difficulty with ambulation. In the operating room, the patient was positioned supine under spinal anesthesia, and a single midline plantar approach was selected based on the anatomical location of the lesion and the need for direct surgical exposure to facilitate adequate visualization. Intraoperative fluoroscopy was utilized to confirm the location of the mass. The plantar fascia was incised, and a few selected fibers were excised to achieve adequate exposure, as retraction was limited by the mass exerting pressure on the fascia. Upon exposure, a small pedunculated fragment partially obscured the main stalk, necessitating its removal along with the overlying cartilaginous cap. The main lesion was then excised using an osteotome in piecemeal, with the cut made parallel to the surface of the cuboid, and the specimen was submitted for histopathological evaluation (Figure 5). Care was taken to achieve adequate exposure and complete removal of the lesion while minimizing injury to the surrounding soft tissues and neurovascular structures. Following excision, the operative site was inspected for residual lesion, and haemostasis was secured. Post-excision fluoroscopy confirmed complete removal of the lesion.

A drain was placed in the dead space to facilitate postoperative drainage and minimize fluid accumulation. The wound was subsequently closed in layers, and a sterile dressing was applied.

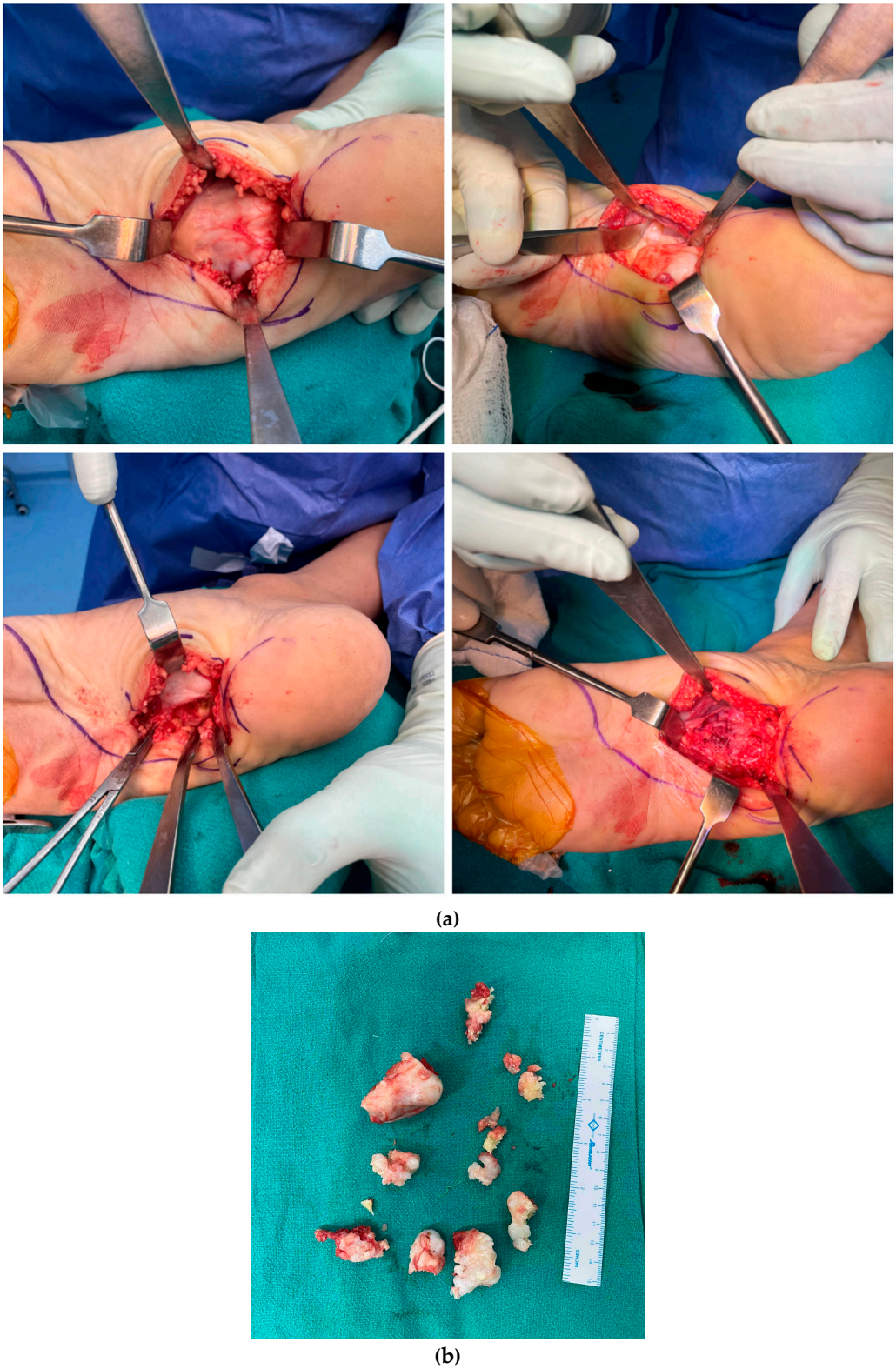

Figure 5. (**a**) Bony outgrowth with shiny cartilaginous cap exposed using the plantar midline approach and splitting of plantar fascia to fully expose the mass. (**b**) The specimen of the excised tumor.

Histopathological examination revealed a tumor comprising outer most fibrous perichondrium, underlying cartilaginous cap and underlying mature bony trabeculae. The cartilage cap shows a spatial distribution of chondrocytes. The superficial chondrocytes show clustering and move towards the osteochondral junction; the chondrocytes appear mildly enlarged, with a few showing gradual endochondral ossification surrounded by

cartilaginous hyaline matrix. The overlying perichondrium is seen continuing with the periosteum of the underlying bone. Overall features are suggestive of osteochondroma (Figure 6).

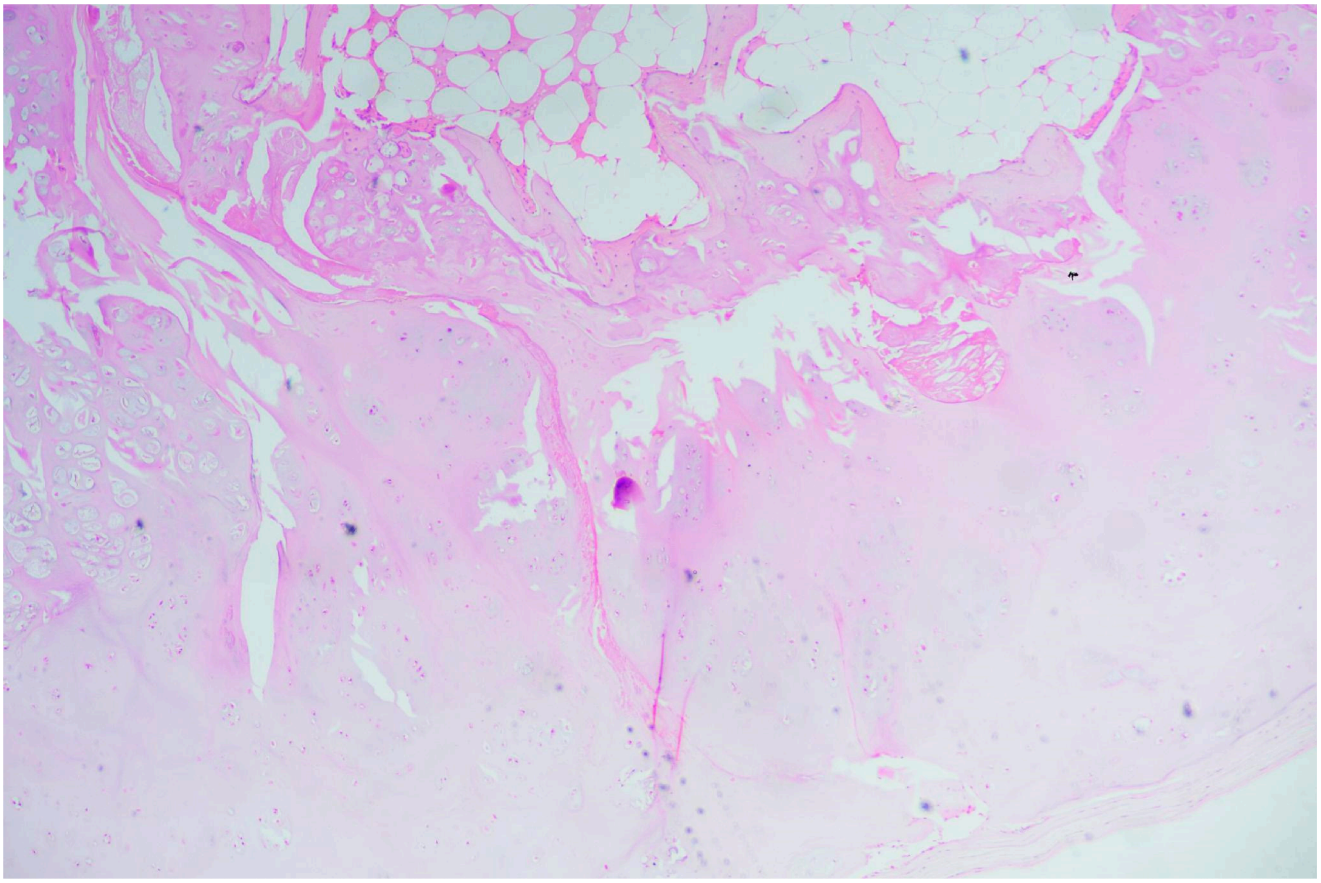

Figure 6. (H&E, 100×) show a tumor comprising outer most fibrous perichondrium, underlying cartilaginous cap and further underlying mature bony trabeculae. The cartilage cap shows a spatial distribution of chondrocytes. These are features of osteochondroma.

3. Follow-Up

The postoperative period was characterized by an uneventful recovery. The surgical drain was removed on postoperative day two without complications. The patient was initially kept non-weight-bearing. The surgical wound healed uneventfully, and sutures were removed at two weeks following surgery. Weight-bearing was initiated thereafter and gradually progressed according to the patient's tolerance. No wound-related complications were observed following the midline plantar incision. The patient was followed up regularly in the outpatient department at 2 weeks, 6 weeks, 3 months, 6 months, and 1 year. The patient's clinical progress was assessed qualitatively during follow-up, with particular attention to pain, ambulatory function, and return to normal daily activities. At the 1-year follow-up, the patient had resumed normal daily activities. At the final follow-up after 1 year, the patient reported complete resolution of pain and had successfully returned to recreational sporting activities without functional limitation. Clinical examination revealed a well-healed, non-tender surgical scar with appropriate cosmetic appearance. Radiographic imaging obtained at the most recent visit demonstrated no radiological evidence of tumor recurrence (Figure 7).



Figure 7. Postoperative radiograph of the ankle in AP, lateral, and oblique views at 1-year follow-up.

4. Discussion

Osteochondroma of the foot and ankle is rare, with most reported cases involving the talus and calcaneus [4,7]. Osteochondroma in the foot poses unique challenges when large or giant in size due to external pressure from footwear. Management of osteochondroma depends on the patient's symptoms, lesion location, size, growth pattern, and potential complications. Asymptomatic lesions without evidence of malignant transformation can generally be managed conservatively with regular clinical and radiological surveillance. Conservative treatment may include activity modification, analgesics or non-steroidal anti-inflammatory drugs (NSAIDs), footwear modification, and offloading of the affected area to reduce mechanical irritation and pressure-related symptoms. Surgical excision is indicated for these lesions after failed conservative management and with functional impairment. Surgical excision of symptomatic osteochondromas offers several potential benefits, including removal of the mechanical prominence, relief of pressure-related pain, improvement in weight-bearing comfort, and restoration of functional mobility. It also provides an opportunity for histopathological examination of the excised lesion. Nevertheless, surgical intervention, particularly for lesions arising from the plantar aspect of the foot, presents

several challenges. Potential complications include wound-related problems, infection, painful plantar scarring, injury to adjacent neurovascular structures, postoperative pain, disruption of the plantar fascia, and weakening of the underlying bone. Incomplete excision may also result in recurrence, particularly if the cartilaginous cap and perichondrium are not adequately removed. Therefore, careful preoperative planning and meticulous surgical technique are essential to minimize these risks.

Cuboid involvement of osteochondroma is exceptionally rare, with only one isolated case documented, including a 29-year-old male with 3-year progressive pain misdiagnosed initially as fibroma [7].

Here we describe a case of a large solitary osteochondroma arising from the medial plantar aspect of the cuboid. He presented with a history of pain in the right foot during ambulation, accompanied by progressive firm swelling. Radiography and Magnetic resonance Imaging confirmed the diagnosis of osteochondroma with a cartilage cap of 2 mm thickness [8]. Despite trying conservative measures, he continued to experience progressive pain and increasing difficulty with ambulation, which eventually interfered with his sports activities. Given the persistent symptoms, considerable lesion size, and mechanical discomfort during weight-bearing, surgical excision was considered the most appropriate treatment option. For surgical removal of any lesions, the surgical approach must provide direct access and adequate visualization of the lesion [9]. A midline plantar approach was utilized in this case as it provides adequate exposure of the lesion. The plantar fascia was split longitudinally to facilitate access; however, care was taken to minimize the extent of fascial disruption and injury to the surrounding soft tissues, which facilitated the complete removal of the lesion flush with the parent bone, ensuring no residual cartilage cap remains, thus reducing the likelihood of recurrence [10]. Following removal, the remaining cuboid cortex appeared intact on intraoperative inspection. No additional burring or rasping was necessary. The use of bone substitutes was not considered necessary because the excision did not result in a significant osseous defect or compromise the structural integrity of the cuboid. Bone wax was used for haemostatic purposes. Postoperatively, the patient was kept non-weight-bearing until sutures were removed at two weeks following surgery. Weight-bearing was initiated thereafter and gradually progressed according to the patient's tolerance. No wound-related complications were observed following the midline plantar incision.

At one-year follow-up, the patient resumed normal activities without any signs of recurrence, demonstrating the efficacy of surgical management in restoring function.

5. Conclusions

This case highlights the cuboid as a potential, although rare, site for osteochondroma. Podiatric surgeons should maintain a high index of suspicion for benign bone tumors when patients present with firm, slow-growing plantar masses and associated pressure symptoms. Advanced imaging, specifically MRI and CT, is indispensable for diagnosis and preoperative planning in the anatomically dense midfoot to ensure complete resection and avoid neurovascular injury. Surgical excision should be considered for symptomatic lesions that interfere with daily activities.

Author Contributions: Conceptualization: S.K.Y. and S.R.; methodology: S.R. and R.K.R.; software: S.K.Y. and M.R.; validation: S.K.Y., R.K.R. and M.R.; investigation: S.K.Y., S.R. and M.R.; resources: S.K.Y., R.K.R. and M.R.; data curation: S.R. and M.R.; writing—original draft preparation: S.K.Y. and S.R.; writing—review and editing: S.K.Y., S.R., R.K.R. and M.R.; visualization: S.K.Y., S.R. and R.K.R.; supervision: S.K.Y., R.K.R. and M.R.; project administration: S.K.Y. All authors have read and agreed to the published version of the manuscript.

Funding: This research received no external funding.

Institutional Review Board Statement: This case report of 1 patient during routine clinical care was exempted from IRB approval. The case was managed and reported in accordance with the ethical principles of the Declaration of Helsinki and applicable institutional standards. Appropriate measures were taken to protect patient privacy.

Informed Consent Statement: Written informed consent has been obtained from the patient to publish this paper.

Data Availability Statement: The original contributions presented in this study are included in the article. Further inquiries can be directed to the corresponding author.

Conflicts of Interest: The authors declare no conflicts of interest.

Abbreviations

The following abbreviations are used in this manuscript:

HMEs	Hereditary multiple exostoses
CT	Computed tomography

References

1. Wu, K.K. Large osteochondroma of the foot. *J. Foot Surg.* **1990**, *29*, 88–93. [PubMed]
2. Dc, D. Cartilaginous tumors of the soft tissues of the hands and feet. *InMayo Clin. Proc.* **1974**, *49*, 721–726. [CrossRef]
3. Tepelenis, K.; Papathanakos, G.; Kitsouli, A.; Troupis, T.; Barbouti, A.; Vlachos, K.; Kanavaros, P.; Kitsoulis, P. Osteochondromas: An updated review of epidemiology, pathogenesis, clinical presentation, radiological features and treatment options. *In Vivo* **2021**, *35*, 681–691. [CrossRef] [PubMed]
4. Patnala, A.K.; Babu, M.E.; Naidu, M.C.; Kumar, S.S.; Kumar, P.V. Osteochondroma of the OsCalcaneum—A case report. *J. Clin. Diagn. Res. JCDR* **2013**, *7*, 1737. [PubMed]
5. Mehta, M.; White, L.M.; Knapp, T.; Kandel, R.A.; Wunder, J.S.; Bell, R.S. MR imaging of symptomatic osteochondromas with pathological correlation. *Skelet. Radiol.* **1998**, *27*, 427–433. [CrossRef] [PubMed]
6. Karasick, D.; Schweitzer, M.E.; Eschelman, D. Symptomatic osteochondromas: Imaging features. *AJR Am. J. Roentgenol.* **1997**, *168*, 1507–1512. [CrossRef] [PubMed]
7. Whitaker, J.M.; Craig, G.C.; Winship, S. Osteochondroma of the cuboid: A case report. *J. Foot Ankle Surg.* **2017**, *56*, 1269–1275. [CrossRef] [PubMed]
8. Bernard, S.A.; Murphey, M.D.; Flemming, D.J.; Kransdorf, M.J. Improved differentiation of benign osteochondromas from secondary chondrosarcomas with standardized measurement of cartilage cap at CT and MR imaging. *Radiology* **2010**, *255*, 857–865. [CrossRef] [PubMed]
9. Kumar, S.; Dhammi, I.K.; Jain, A.K.; Shahi, P. Osteochondroma of the talus: Three varying cases. *BMJ Case Rep.* **2020**, *13*, e237670. [CrossRef] [PubMed]
10. Bottner, F.; Rodl, R.; Kordish, I.; Winkelmann, W.; Gosheger, G.; Lindner, N. Surgical treatment of symptomatic osteochondroma: A three-to eight-year follow-up study. *J. Bone Jt. Surg. Br.* **2003**, *85*, 1161–1165.

Disclaimer/Publisher's Note: The statements, opinions and data contained in all publications are solely those of the individual author(s) and contributor(s) and not of MDPI and/or the editor(s). MDPI and/or the editor(s) disclaim responsibility for any injury to people or property resulting from any ideas, methods, instructions or products referred to in the content.