Anatomical Structures at Risk After Medial Column Nailing

A Cadaveric Study

Dominick J. Casciato, DPM*
Alex Bischoff, DPM†
Ian Barron, DPM†

Background: Medial column nails have been introduced into Charcot's neuroarthropathy reconstruction as superconstruct fixation with high fatigue strength and pullout resistance. Similar to intramedullary nailing throughout other long-bone fixation, injury to neurovascular and musculotendinous structures secondary to percutaneous interlocking screw fixation may exist. We sought to identify structures at risk for injury during the interlocking of a medial column nail.

Methods: Medial column nails were inserted into ten cadaveric limbs. The proximal (talar), middle (first metatarsal), and distal (first metatarsal) locations for the interlocking screws were drilled, and a 0.062 Kirschner wire was inserted into respective drillholes to simulate interlocking screws. After dissection, the distances of each Kirschner wire to nearby anatomical structures were measured. Levels of risk were assigned to each soft-tissue structure based on distance to each Kirschner wire: high (0–3.5 mm), intermediate (3.6–7.0 mm), and low (>7.0 mm). A 3.5-mm threshold for each category was used because this represented a multiple of the diameter of the interlocking screws. Mean ± SD and ranges are reported for structures at high and intermediate risk for injury.

Results: Proximally, the deltoid ligament (ten of ten), posterior tibial tendon (eight of ten), and saphenous vein (six of ten) were at high or intermediate risk for injury consistently. At the middle screw, the medial dorsal cutaneous nerve and the medial marginal vein were at high or intermediate risk in ten and eight specimens, respectively. At the distal interlocking screw, the medial dorsal cutaneous nerve was at high risk for injury in all ten specimens.

Conclusions: There is high and intermediate risk to many musculotendinous and neurovascular structures when performing percutaneous interlocking screws in a medial column nail. These findings serve to educate surgeons of the anatomical considerations they must have when performing medial column nailing for reconstruction of Charcot's foot. (J Am Podiatr Med Assoc 115(6), 2025; doi:10.7547/23-110)

After degenerative changes associated with Charcot's neuroarthropathy, stabilization of midfoot and hindfoot pathology proves challenging owing to an at-risk soft-tissue envelope and poor bone quality.[1-3] Reduction and maintenance of this deformity relies on the application of superconstructs, whether through internal fixation or external fixation, or a combination of the two.[4-6] While minimizing the dissection used in traditional open reduction and internal fixation with plates and screws, the insertion of axial intramedullary fixation has shown positive results.[7,8] Among intramedullary beams, screws, bolts, and nails, many options exist for stabilizing midfoot Charcot's deformities. Although insertion of such fixation devices entails minimal dissection, anatomical structures throughout the foot and ankle remain at risk when inserting interlocking screws.

Previous cadaveric studies identified neurovascular and tendinous structures at risk with placement of a tibiotalocalcaneal intramedullary nail for hindfoot arthrodesis.[9-11] Although there exists a paucity of data examining structures at risk after retrograde medial column nailing, surgical anatomy has been well described. Specific to Charcot's neuroarthropathy, when attempting a posterior approach to medial column beaming, research found the sural nerve,

*Orlando VA Medical Center, Orlando, FL.
†OhioHealth Grant Medical Center, Columbus, OH.
Corresponding author: Dominick J. Casciato, DPM, Orlando VA Medical Center, 13800 Veterans Way, Orlando, FL 32827. (E-mail: dominickcasciatodpm@gmail.com)

Achilles tendon, flexor hallucis longus tendon, and ankle joint to be at risk for injury.[12] Moreover, cadaveric analysis has described the optimal diameter when beaming through each respective metatarsal.[13] Also, in a sample of patients with midfoot Charcot's neuroarthropathy, no difference among varying talar target sites for medial column intramedullary superconstructs were found.[2] Although Charcot's reconstruction may entail an open approach, appreciating structures at risk after nail placement proves important during neuropathic minimally invasive surgeries (NEMESIS) exposure techniques that obscure complete visualization of nail interlocking screw drilling and insertion.[14]

To our knowledge, there exists no description of the structures at risk after insertion of interlocking screws during retrograde medial column nailing. The aims of this investigation included the identification of nearby anatomical structures at low, medium, and high injury risk during interlocking screw placement. The results of this cadaveric study will assist surgeons with anticipating anatomical structures nearby when percutaneously inserting interlocking screws during medial column nailing. Similarly, appreciation for this encountered anatomy will guide surgeons when considering insertion of nails of varying lengths.

Methods

Ten fresh-frozen cadavers were thawed at room temperature. Specimen demographic data were collected and recorded using a spreadsheet program (Microsoft Excel; Microsoft Corp, Redmond, Washington). A linear incision was made medial to the extensor hallucis longus tendon, and a first metatarsophalangeal joint capsulotomy was performed. A guidewire was placed through the first metatarsal head, with the assistance of fluoroscopy, aiming just medial to the midline of the talar body. During guidewire placement into the talus, the forefoot was kept plantigrade to prevent residual first metatarsal elevatus, forefoot supinatus, or an everted forefoot. The length of the wire from the metatarsal head to the middle of the talar body in the sagittal plane was measured. A 5.5-mm opening drill was placed over the guidewire and used to bore a hole to the end of the talar body. The canal was then reamed to a final 8.5/9.0-mm reamer diameter for the insertion of an 8- or 9-mm-diameter by 130-mm-long nail. An intramedullary nail (T2 ICF; Stryker, Kalamazoo, Michigan) was then placed into the medial column while attached to the system's targeting device, allowing for one talar and two first metatarsal interlocking screws (Fig. 1A). The device was hammered until the proximal end of the nail stopped in the talar body, with the most distal screw hole parallel to the weightbearing surface of the first metatarsal (Fig. 1B). A stab incision was then made where the trocar for the proximal interlocking screw met the skin. This was followed by drilling of a 2.6-mm hole for a 3.5-mm interlocking screw into the nail. This was then repeated for the middle and distal screw holes (Fig. 1C).

Once all of the interlocking screws for the nail were drilled, the nail was removed. Next, 0.054 Kirschner wires were placed through the stab incisions into the previously drilled holes through the talus and first metatarsal sites. The skin was then removed from the cadaveric specimen, and the distances from nearby anatomical structures were measured and recorded using digital calipers (AllNice Calipers, Hardell Tools, Hagerstown, Maryland) (Fig. 2). Distances from each Kirschner wire were placed into high (0–3.5 mm), intermediate (3.6–7.0 mm), and low (>7.0 mm) risk categories, with a 1-cm radius from the Kirschner wire serving as the maximum distance to which structures were identified. Mean ± SD and ranges are reported for structures at high and intermediate risk for injury. A 3.5-mm threshold for each category was used because this represented a multiple of the diameter of the interlocking screws.

Results

The mean ± SD age and weight of the dissected cadavers were 68.8 ± 14.06 years and 170.3 ± 38.89 pounds, respectively. Among the eight male and two female specimens, there were four right limbs and six left limbs.

Proximal Screw

The deltoid ligament, posterior tibial tendon, flexor digitorum longus muscle, saphenous vein, and saphenous nerve were encountered at the level of the proximal screw (Table 1). Overall, the deltoid ligament was at high risk for injury in seven specimens, a mean ± SD of 1.28 ± 2.0 mm (range, 0–4.5 mm) away from the screw. The posterior tibial tendon was at high risk for injury in five specimens, a mean ± SD of 5.61 ± 5.99 mm (range, 0–18.5 mm) away from the screw. The saphenous vein (Fig. 2A and B) was at high risk for injury in three specimens, a mean ± SD of 8.14 ± 8.17 mm (range, 0–22.5 mm) away from the screw. The saphenous nerve was at high risk for injury in two specimens, a mean ± SD of 10.05 ± 7.61 mm (range, 0.5–22.2 mm) away from the screw. The flexor digitorum longus muscle was



Figure 1. Example lateral (A) and dorsoplantar (B) views of each foot after nail and interlocking screw insertion (C).

at intermediate risk for injury in two specimens, a mean ± SD of 13.3 ± 7.48 mm (range, 4–27.4 mm) away from the screw.

Middle Screw

The medial dorsal cutaneous nerve, medial marginal vein, extensor hallucis longus muscle, and penetrating first intermetatarsal arteries were encountered at the level of the middle screw. The medial dorsal cutaneous nerve was at high risk for injury in six specimens, a mean ± SD of 2.54 ± 1.83 mm (range, 0.2–5.1 mm) away from the middle screw. The medial marginal vein was at high risk for injury in six specimens, a mean ± SD of 4.14 ± 2.38 mm (range, 1.1–8.3 mm) away from the screw. The extensor hallucis longus muscle was at low risk for injury in ten specimens, a mean ± SD of 12.39 ± 2.83 mm (range, 8.4–17.9 mm) away from the

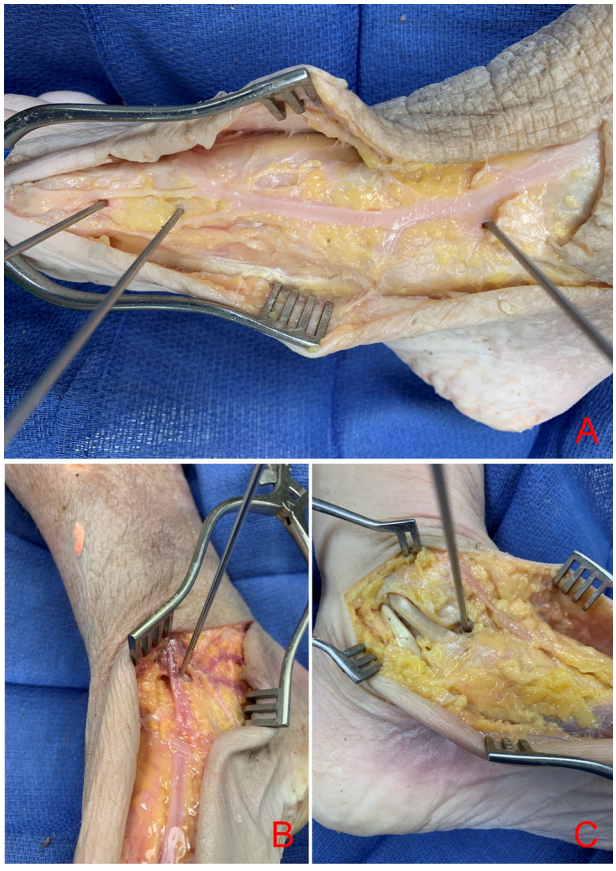

Figure 2. Placement of reference Kirschner wires in relation to underlying vascular (A and B) and tendinous (C) structures.

screw. The penetrating intermetatarsal artery was at high risk for injury in one specimen, a mean ± SD of 6.46 ± 1.98 mm (range, 2.8–8.6 mm) away from the screw.

Distal Screw

The medial dorsal cutaneous nerve, extensor hallucis longus muscle, and medial marginal vein were encountered at the level of the distal screw. The medial dorsal cutaneous nerve was at high risk for injury in ten specimens, a mean ± SD of 1.69 ± 0.90 mm (range, 0.5–3.2 mm) away from the screw. The medial marginal vein was at high risk for injury in four specimens, a mean ± SD of 5.76 ± 3.92 mm (range, 0.6–10 mm) away from the screw. The extensor hallucis longus muscle was at intermediate risk for injury in one specimen, a mean ± SD of 10.75 ± 3.21 mm (range, 4.7–15.6 mm) away from the screw.

Discussion

Intramedullary nailing provides a stable, load-sharing construct to address a myriad of orthopedic deformities. Applied to the hindfoot, this construct proves to be an effective and safe limb salvage technique in patients with Charcot's neuroarthropathy.[15] Although nailing midfoot structures has not been assessed, intramedullary fixation devices have been shown to be more robust than plantar plating and screws.[16] Moreover, these intramedullary devices require less soft-tissue dissection; however, anatomical structures remain at risk for injury due to the percutaneous or NEMESIS approaches.[12,14,17] Adding to previous research and expanding the knowledge base of midfoot nailing, this investigation identifies anatomical structures at risk when securing a medial column nail with interlocking screws.

Table 1. Number of Specimens with Screws in Proximity to Named Anatomical Structures at Risk

Screw Location	High Risk (0–3.5 mm)	Intermediate Risk (3.6–7.0 mm)	Low Risk (>7.0 mm)
Proximal screw			
Deltoid ligament	7	3	0
Posterior tibial tendon	5	3	2
Flexor digitorum longus muscle	0	2	8
Saphenous vein	3	3	4
Saphenous nerve	2	2	6
Middle screw			
Medial dorsal cutaneous nerve	6	4	0
Medial marginal vein	6	2	4
Penetrating intermetatarsal artery	1	4	5
Extensor hallucis longus muscle	0	0	10
Distal screw			
Extensor hallucis longus muscle	0	1	9
Medial dorsal cutaneous nerve	10	0	0
Medial marginal vein	4	2	4

In the present study, we used the T2 ICF nail specific for medial column fixation. This device provides for intramedullary stabilization as well as compression through one proximal and two distal screws locked into the nail. Whether through a percutaneous, minimal incision, or traditional open approach to joint preparation and fixation, understanding the structures at risk after inserting the nail during placement of interlocking screws remains imperative to avoid iatrogenic injury. Among all of the specimens, the deltoid ligament and posterior tibial tendon (Fig. 2C) were at high risk for damage from the proximal screw. As a result, care should be taken to avoid or repair an incision made into these ligamentous or tendinous structures to prevent further damage, as indicated when nailing other hindfoot pathology.[18] The saphenous and medial marginal veins were at risk for injury at the level of the proximal and middle/distal screws, respectively. To prevent undue bleeding of these structures, blunt dissection and retraction, or protection using a drill sleeve, should be attempted as similarly performed with hindfoot nailing.[19] Because the first penetrating artery was at high risk for injury in one specimen and intermediate risk in four specimens, attention should be given to preventing excessive drilling at the level of this artery, previously described as a mean ± SD of 11.5 ± 3.9 mm distal to the base of the first metatarsal, to prevent vascular damage.[17] High-risk nerve tissue at the level of the proximal screw (saphenous nerve) and middle/distal screws (medial dorsal cutaneous nerve) can also be avoided or minimized through clinical examination and mapping of the nerve at the level of the tarsometatarsal joint.[20]

Several limitations were encountered during this investigation, primarily due to the cadaveric nature of this study. First, because only ten cadavers were used, a larger sample size would be needed to consider different anatomical variations. Moreover, the feet nailed in this investigation were not pathologic. During insertion among those who meet nailing indications such as Charcot's neuroarthropathy, traumatic injury, or other osseous deformity, the distance to the structures measured in this study may be different. Notably, Charcot's reconstruction often entails a medial incision to prepare midfoot joints before fixation, allowing retraction of the structures identified in this study. However, as minimally invasive and minimal incision techniques advance, along with dissection that does not span the entirety of this intramedullary nailing system, appreciation for the named structures in this investigation remains important. Nevertheless, the anatomical description provided in this investigation adds to the current body of knowledge similarly examining structures at risk during medial and lateral column beaming.

Conclusions

Medial column nailing provides an additional type of intramedullary fixation along with beams, bolts, and screws to treat unstable midfoot Charcot's neuroarthropathy. Because anatomical structures remain at risk when securing the construct, attention should be given to respect nearby soft-tissue structures. In an open procedure, although some structures are unable to be avoided, such as the deltoid ligament when inserting the talar interlocking screw, repair of the ligament may be warranted. Although NEMESIS continues to advance, appreciation for structures at risk is imperative to reduce the risk of iatrogenic injury. As a relatively new device, future investigations will need to compare the outcomes of medial column nailing versus other intramedullary fixation approaches.

Financial Disclosure: None reported.
Conflict of Interest: None reported.

References

1. Pierre-Jerome C: *The Essentials of Charcot Neuroarthropathy: Biomechanics, Pathophysiology, and MRI Findings*, Elsevier, Cambridge, MA, 2022.
2. Casciato DJ, Stone R, Thompson J, et al: Radiodensity analysis of medial column superconstruct fixation sites in midfoot Charcot neuroarthropathy. J Foot Ankle Surg **61:** 1076, 2022.
3. Casciato DJ, Stone R, Thompson J, et al: Radiodensity analysis of lateral column superconstruct fixation sites in midfoot Charcot neuroarthropathy. J Foot Ankle Surg **62:** 377, 2023.
4. Frøkjær J: Surgical treatment of midfoot Charcot neuroarthropathy review of literature and our results after superconstruct reconstruction of midfoot Charcot neuroarthropathy. J Clin Orthop Trauma **17:** 59, 2021.
5. Lee DJ, Schaffer J, Chen T, et al: Internal versus external fixation of Charcot midfoot deformity realignment. Orthopedics **39:** e595, 2016.
6. Hegewald KW, Wilder ML, Chappell TM, et al: Combined internal and external fixation for diabetic Charcot reconstruction: a retrospective case series. J Foot Ankle Surg **55:** 619, 2016.
7. Wiewiorski M, Yasui T, Miska M, et al: Solid bolt fixation of the medial column in Charcot midfoot arthropathy. J Foot Ankle Surg **52:** 88, 2013.
8. Lamm BM, Siddiqui NA, Nair AK, et al: Intramedullary foot fixation for midfoot Charcot neuroarthropathy. J Foot Ankle Surg **51:** 531, 2012.

9. Pochatko DJ, Smith JW, Phillips RA, et al: Anatomic structures at risk: combined subtalar and ankle arthrodesis with a retrograde intramedullary rod. Foot Ankle Int **16:** 542, 1995.
10. McGarvey WC, Trevino SG, Baxter DE, et al: Tibiotalocalcaneal arthrodesis: anatomic and technical considerations. Foot Ankle Int **19:** 363, 1998.
11. de Cesar Netto C, Johannesmeyer D, Cone B, et al: Neurovascular structures at risk with curved retrograde TTC fusion nails. Foot Ankle Int **38:** 1139, 2017.
12. Peterson KS, Hyer CF: Posterior approach for medial column beam screw in midfoot Charcot reconstruction: technique and structures at risk. J Foot Ankle Surg **54:** 433, 2015.
13. Fidler CM, Watson BC, Reb CW, et al: Beaming in Charcot arthropathy—intramedullary fixation for complicated reconstructions: a cadaveric study. J Foot Ankle Surg **56:** 802, 2017.
14. Miller RJ: Neuropathic minimally invasive surgeries (NEMESIS): percutaneous diabetic foot surgery and reconstruction. Foot Ankle Clin **21:** 595, 2016.
15. Paola LD, Volpe A, Varotto D, et al: Use of a retrograde nail for ankle arthrodesis in Charcot neuroarthropathy: a limb salvage procedure. Foot Ankle Int **28**, 967, 2007.
16. Simonik MM, Wilczek J, LaPorta G, et al: Biomechanical comparison of intramedullary beaming and plantar plating methods for stabilizing the medial column of the foot: an in vitro study. J Foot Ankle Surg **57:** 1073, 2018.
17. Whelan JH, Lazoritz JP, Kiser C, et al: Location of the deep plantar artery: a cadaveric study. JAPMA **110:** Article_4, 2020.
18. Goss DA Jr, Reb CW, Philbin TM: Anatomic structures at risk when utilizing an intramedullary nail for distal fibular fractures: a cadaveric study. Foot Ankle Int **38:** 916, 2017.
19. Knight T, Rosenfeld P, Jones IT, et al: Anatomic structures at risk: curved hindfoot arthrodesis nail: a cadaveric approach. J Foot Ankle Surg **53:** 687, 2014.
20. Boffeli TJ, Gervais SJ: Accuracy of palpation to identify the medial branch of the medial dorsal cutaneous nerve in medial column surgery: correlation of preoperative nerve marking with intraoperative findings during Lapidus fusion. J Foot Ankle Surg **60:** 2, 2021.