Tarsal Tunnel Release Using a Mini-Incision and Single-Portal Endoscopy

Michael H. Wynn, DPM*

Background: This retrospective study aimed to describe the decompression of the tarsal tunnel and porta pedis using a mini-incision and single-portal endoscopy.

Methods: Thirty-one feet were evaluated and conservatively treated for tarsal tunnel syndrome between December 2013 and February 2019. Age, sex, medical history, and test results (those of nerve conduction studies, magnetic resonance imaging, and provocation tests) were compared. Foot-related quality of life assessments included subjective improvement and the American Orthopaedic Foot and Ankle Society (AOFAS) hindfoot-ankle score.

Results: Twenty women (77%) and six men (23%) (age range, 30–77 years) were included in the study. Overall, 26 feet (83.9%) underwent decompression of the tibial nerve, medial plantar nerve, and lateral plantar nerves; five of these feet (19.2%) underwent bilateral nerve decompression. The length of clinical follow-up ranged from 2 to 64 months (mean, 27.3 months). During postoperative evaluations, the average AOFAS score was 85.9 (range, 70–100). No significant difference between the AOFAS scores of healthy and unhealthy patients was found. The percentage of perceived improvement as reported by patients ranged from 50% to 100%.

Conclusions: The mini-incision approach is a viable option for tarsal tunnel surgery. With reduced dissection, the chances of complications and pain are minimized without compromising adequate external neurolysis. Therefore, patients may be able to perform early weightbearing/ambulation on the operated extremity. (J Am Podiatr Med Assoc 115(2), 2025; doi:10.7547/22-147)

Tibial nerve compression in the tarsal tunnel has been described in the literature since the 1960s.[1,2] The tarsal tunnel comprises the flexor retinaculum (laciniate ligament), which runs from the medial malleolus to the medial calcaneal wall,[2] and the tissues deep to the retinaculum. In the tarsal tunnel, the tibial nerve and its branches, tibial artery, tibial veins, posterior tibial tendon, flexor digitorum longus tendon, and flexor hallucis longus tendon are positioned in the fibro-osseous spaces.[3] At the distal margin of the tarsal tunnel, the porta pedis provides an entry for the branches of the tibial nerve to course from the tunnel into the plantar vault. The porta pedis is composed of the anterior (medial plantar nerve) and posterior (lateral plantar nerve) calcaneal tunnels, which are separated by a fibrous septum that extends from the abductor hallucis to the medial calcaneal wall. Compression of the tibial nerve or its associated branches can lead to pain, numbness, and tingling in the foot[4,5]; in some cases, decompression by means of external neurolysis can be achieved by releasing the flexor retinaculum and the structures that delimit the porta pedis, often alleviating pain and improving sensation.[3,6]

The initial diagnosis of tarsal tunnel syndrome is mostly clinical. Associated symptoms include ankle pain radiating to the arch of the foot, paresthesia in the distributions of the tibial nerve, and pain while walking.[1-10] Clinical findings typically include a positive response (ie, shooting nerve pain) to a provocation palpation or percussion test at the tarsal tunnel, eliciting either a Valleix or Tinel sign.[11] Electroneurodiagnostic tests, such as nerve conduction studies (NCSs), are used to support the diagnosis of tarsal tunnel syndrome[8]; however, these can be subject to operator biases, and negative test results do not definitively exclude the diagnosis. Furthermore, magnetic resonance imaging (MRI) and radiography can be used to rule out bone and soft-tissue impingement in the tarsal tunnel.[12] In addition, when conservative treatments are unsuccessful, surgical release of the flexor retinaculum and porta pedis is indicated.[6-10]

Open tarsal tunnel release is the classic method for surgically treating tarsal tunnel syndrome.[9] However, inconsistent results have been reported

*Foot Care Associates of Texas, 23972-A Hwy 59 N, Kingwood, TX 77339.

Corresponding author: Michael H. Wynn, (E-mail: MichaelFCAT@gmail.com)

in the literature, and success rates range from 44% to 95%.[4,13,14] Complications associated with open surgical release of the tibial nerve and its branches include poor wound healing, scarring that further entraps nerve tissue, edema, hematoma, and symptom recurrence.[3,15,16] Endoscopic tarsal tunnel release is an alternative to open surgical decompression, and this method has been associated with low recurrence of symptoms, minimal scarring associated with small incisions, limited dissection, and early weightbearing ambulation on the operated extremity and aids in nerve gliding.[7,15] However, a limitation of endoscopic tarsal tunnel decompression is the reduced visualization of the neurovascular structures and structures defining the porta pedis.

Considering the drawbacks of the open method and potential limitations of a purely endoscopic method, we hypothesized that a mini-incision, single-portal endoscopic procedure would reduce complications and yield good patient satisfaction at the time of postoperative follow-up. To assess this outcome, we performed a retrospective case series investigation of consecutive patients surgically treated for tarsal tunnel syndrome using the mini-incision and single-portal endoscopic approach. This study aimed to evaluate patient satisfaction and observe complications associated with this surgical approach.

Patients and Methods

Between May 2014 and February 2019 (4 years 10 months), mini-incision tarsal tunnel release was performed on 26 consecutive patients (31 feet) for the treatment of tarsal tunnel syndrome. All of the procedures were performed by one surgeon (M.W.), who is a member of the Association of Extremity Nerve Surgeons. The study design was approved by the institutional review board of HCA Houston Healthcare (Kingwood, Texas), and the requirement for informed consent was waived due to the retrospective design of the study. Patient information was anonymized, and no protected health information was exposed. All of the patients were followed up by the surgeon throughout the postoperative course. Patients with soleal sling conditions, Baxter nerve entrapment, medial calcaneal nerve entrapment, and plantar fasciitis were excluded because these pathologies warrant separate interventions.

Extended patient profiles were created with the variables of interest, including age, sex, medical history, MRI findings, NCS results, duration of follow-up, and foot-related quality of life scores (Table 1). Although not every patient was evaluated using MRI and NCSs before 2015, diagnoses were purely clinically based on the patient's reports of numbness and discomfort along the distribution of the posterior tibial nerve. A positive provocation test or Tinel sign and positive NCS or MRI results were used to confirm the clinical findings. The electrodiagnostic test results in almost all of the patients showed a decrease in amplitude and velocity of the tibial nerve behind the ankle, as mentioned in the interpretation by the testing neurologist. After May 2015, 16 patients (61.5%) underwent both an MRI and NCSs in the diagnosis of tarsal tunnel syndrome. Foot-related quality of life assessments included subjective improvement and the American Orthopaedic Foot and Ankle Society

Table 1. General Patient Information and Summary of Statistical Results

Variable	Total (N = 26)	Healthy (n = 14)	Unhealthy (n = 12)	*P* Values
Age (mean ± SD [years])	57.6 ± 11.8	56.1 ± 11.2	59.3 ± 12.7	
Sex (No. [%])				
Male	6 (23)	3	3	
Female	20 (77)	11	9	
Foot (No. [%])				
Left	10 (38.5)	5	5	
Right	11 (42.3)	8	3	
Both	5 (19.2)	1	4	
AOFAS score[a]				
No. of feet	24	10	14	
Median (range)	99.0 (70–100)	99.0 (70–99)	99.0 (74–100)	.39 (NSD)
% Improvement[a]				
No. of feet	30	14	16	
Median (range)	90.0 (50–100)	90.0 (50–100)	85.0 (50–100)	.57 (NSD)

Abbreviations: AOFAS, American Orthopaedic Foot and Ankle Society; NSD, no significant difference.

[a]Data were analyzed using a Mann-Whitney *U* test. The AOFAS and percentage of improvement scores for each foot were entered as independent data points.

(AOFAS) hindfoot-ankle score, as discussed by Kitaoka et al[17] and Ibrahim et al.[18]

The percentage of improvement (range, 0%–100%) was determined based on the patient's subjective assessment of improvement and was recorded in the respective patient's medical record. The AOFAS score was determined based on direct communication and telephone interviews. Seven patients (26.9%) (seven feet; 22.6%) were lost to follow-up because they could not be reached for further evaluations after a mean of 9.1 weeks (range, 8–16 weeks) after the operation; therefore, outcomes of interest for these patients were not obtained. Patients were lost to follow-up despite a minimum of two telephone calls and a written letter attempting to recall them.

Procedure

The endoscopic tarsal tunnel decompression set of instruments (Stryker Corp, Portage, Michigan) was used for all of the procedures. This set includes obturators, slotted cannulas, a spatula, probes, and a hook knife. Adjunct instruments included Stevens scissors, a Crile retractor, a 2.7-mm 30° endoscope, a bipolar electrocoagulator, and a set of ×3.5 magnification loupes with a headlamp.

Using a grid to measure the tarsal tunnel and porta pedis, the medial malleolus, navicular tuberosity, and calcaneal axis were identified. In addition, a point—1.2 cm posterior to the medial malleolus—was used as the estimated anatomical location of the tibial nerve.[6] Using a marking pen, a 2-cm line was drawn parallel to the axis of the calcaneus over the site of the neurovascular bundle (Fig. 1A). Then, the soft spot (indicative of the location of the medial and lateral plantar nerve tunnels inside the porta pedis) was marked.

The patient was placed in the supine position on a split-leg table. The surgical site was prepared and draped in a sterile manner to halfway up the leg. A thigh tourniquet was applied and inflated to approximately 100 mm Hg above the patient's systolic blood pressure. Using a No. 15 blade, a 1.5- to 2.0-cm incision was made over the calcaneal axis, centered over the neurovascular bundle through the skin and into the subcutaneous tissue. Perpendicular vessels were ligated using the bipolar electrocoagulator. Aided by the ×3.5 magnification loupes, meticulous dissection was performed to free the soft tissue from the flexor retinaculum. The puncture was performed through the flexor retinaculum on the posteriormost aspect of the incision, along the calcaneal axis, and traced anteriorly. The flexor retinaculum was sectioned using the bipolar electrocoagulator (Fig. 1B). Then, the Stevens scissors or bipolar electrocoagulator was used to section the retinaculum and enter the third canal of the tarsal tunnel.

Identification of the tarsal canal was confirmed on both sides of the flexor retinaculum. Working proximally, a spatula was used to free the deep soft tissue from the inferior retinaculum, while avoiding the neurovascular bundle within the tarsal canal. The obturator and cannula of the endoscope were inserted deep to the retinaculum and superficial to the neurovascular bundle; thereafter, the obturator and cannula were maneuvered proximally to dilate the tunnel space. The obturator and cannula were placed such that the slot in the cannula was at the 12 o'clock position (Fig. 1C). Then, the obturator was removed and the endoscopic camera was inserted. This allowed visualization of the retinaculum (Fig. 2A) and any vessels in the retinaculum; however, visualization of the neurovascular structures was obscured. The spatula was used to free the soft tissues superficial to the retinaculum, and the Crile retractor was inserted for optimal retraction and visualization in the subcutaneous plane. At this point, both sides of the flexor retinaculum (deep and superficial) were visualized at the level of the ankle. Vascularity in the flexor retinaculum was identified, and the endoscope was removed. Using a bipolar electrocoagulator, the flexor retinaculum was sectioned in line with the cannula slot to seal any bleeding before cutting the retinaculum (Fig. 1D). The cannula served as a guide for the bipolar electrocoagulator and promoted straight sectioning. Then, either the hook knife or Stevens scissors were used to section the flexor retinaculum. When using the hook knife, the endoscope was inserted into the cannula for clear visualization of the structures to be cut. Blunt dissection was performed to verify that there was no constriction of the site. At this point during the surgery, external neurolysis of the tibial nerve in the proximal tarsal tunnel was complete (Fig. 2B).

Attention was then directed to the distal aspect of the tarsal tunnel. The next step was to identify the neurovascular structures and trace them distally to identify the tunnels of the porta pedis beneath the abductor hallucis muscle. A single small obturator was placed superficial to the neurovascular bundle and into the tunnels to slightly dilate the soft tissues (Fig. 1E). Then, the obturator and cannula were placed in the tunnels. The obturator and cannula were adjusted such that the retinaculum could be identified at the 12 o'clock position on the camera scope. The endoscope was inserted as previously described to identify vascular bleeding and the fibrous roof of the porta pedis tunnel (Fig. 2C).

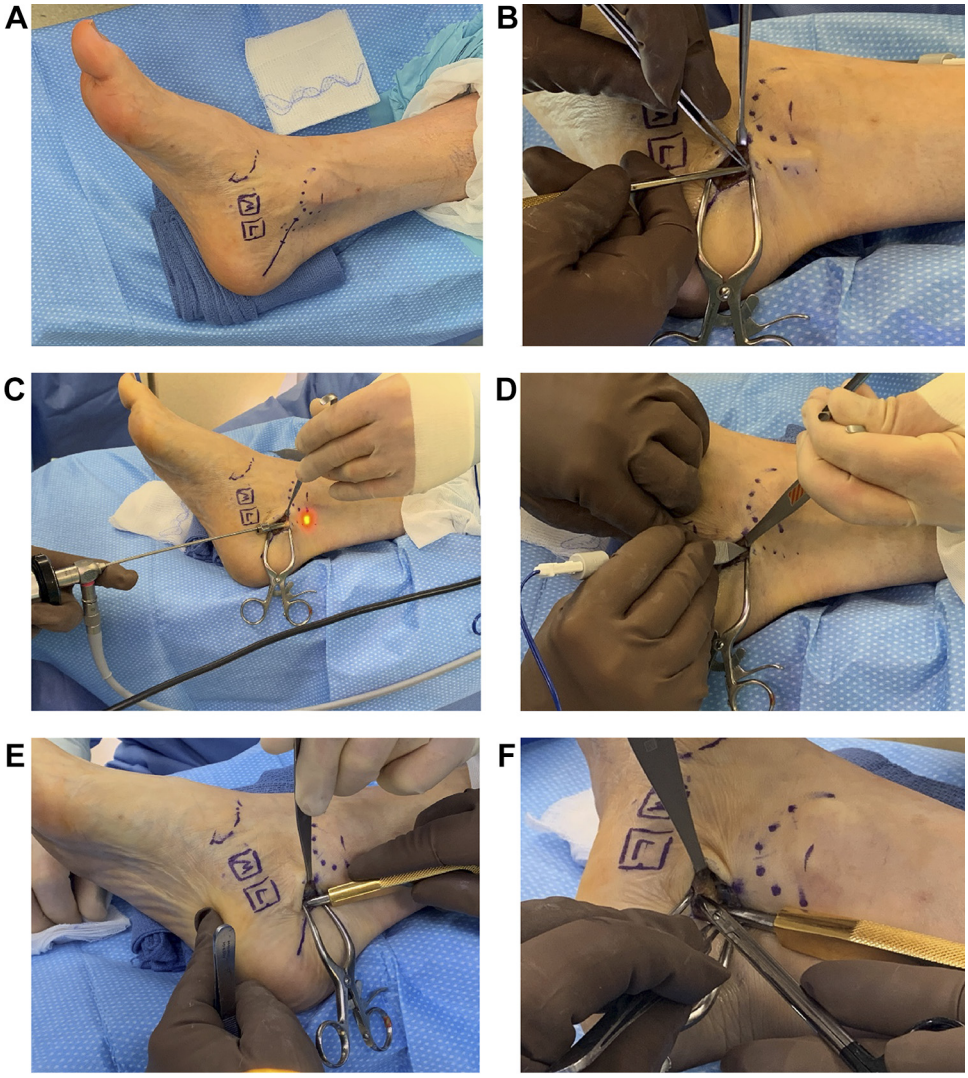

Figure 1. Intraoperative photographs. A, Landmarks on the medial aspect of the ankle and foot. B, Spatula inserted underneath the retinaculum. C, Insertion of the endoscope into the porta pedis. D, Use of a bipolar electrocoagulator on the flexor retinaculum. E, Identification of the lateral portal with an obturator. F, View of the porta pedis using Stevens scissors to identify the medial portal.

Separation of the abductor hallucis muscle from its fascia or the roof of the porta pedis was performed in a narrow window, above the slot of the cannula. The septum of the porta pedis could not be visualized. A Crile retractor was inserted and lifted to raise the skin and muscle, and the bipolar electrocoagulator was used to coagulate any bleeding at the roof of the porta pedis or fascia of the abductor muscle. Thereafter, using either the hook knife or Stevens scissors, the roof of the tunnel was sectioned (Fig. 1F), and both the medial and lateral plantar nerve tunnels of the porta pedis were lysed (Fig. 2D). Typically, the distal portion of the canal extended for approximately 2 cm; at this point, decompression of the porta pedis was considered complete, although the fibrous septum had not been excised—the optimum procedure for decompression, as discussed by Rosson et al.[19] According to my experience, releasing the fascial roof of the tunnels results in adequate decompression of the medial and lateral plantar nerves to this point. Furthermore, the septum cannot be excised using endoscopic equipment alone. The site was flushed, and the tourniquet was released. Visible bleeds were identified and ligated or electrocoagulated. The skin was then closed in the usual manner, and the area was infiltrated with 0.5% bupivacaine as a postoperative nerve block.

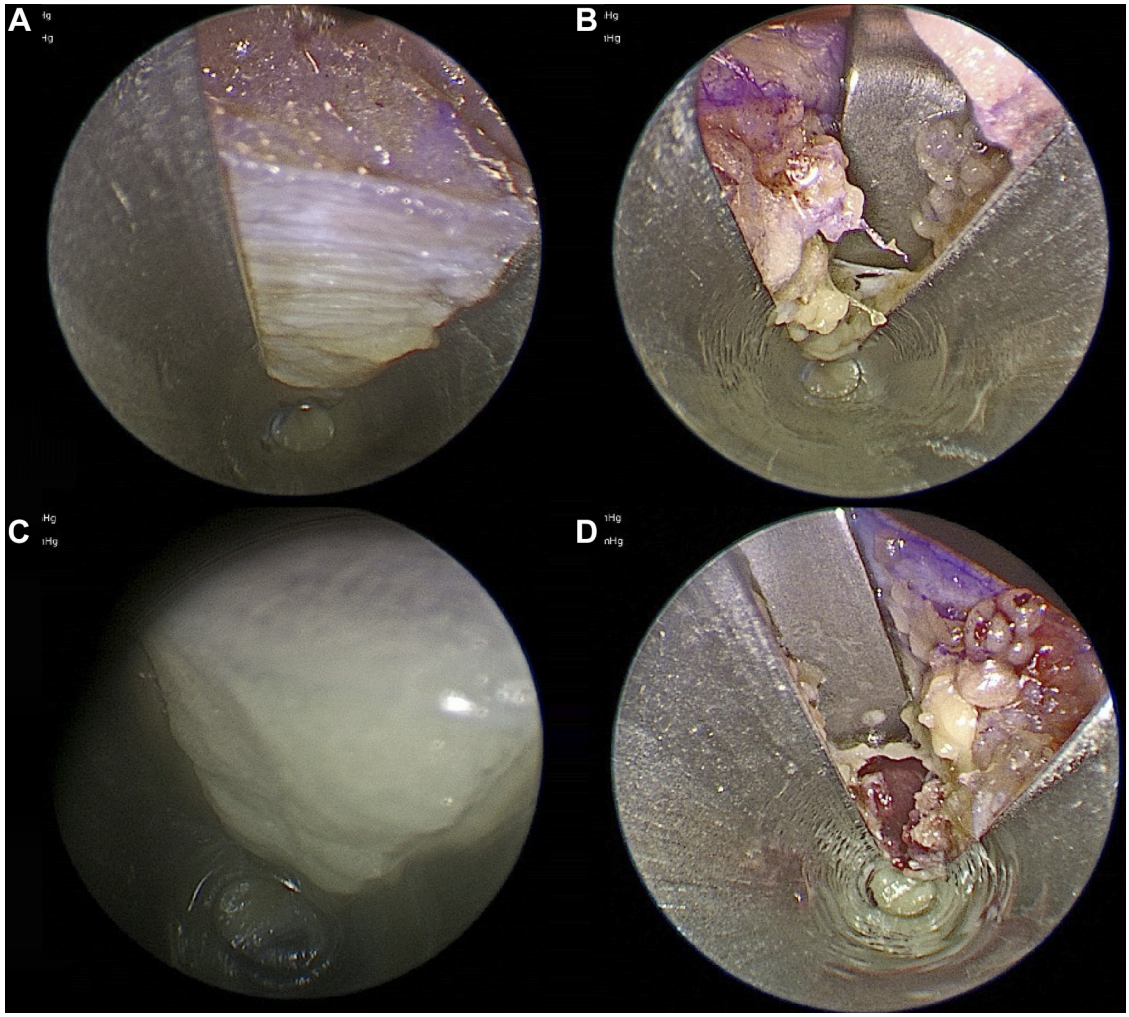

Figure 2. Endoscopic images taken intraoperatively. A, Flexor retinaculum. B, Retinaculum lysed with a Crile retractor. C, Porta pedis roof. D, Porta pedis roof lysed with a Crile retractor.

After surgery, all of the patients avoided weightbearing activities on the operated extremity for the first 4 days after the operation. Patients did not use splints. They performed passive range-of-motion exercises of the ankle and foot, which decreases loading of the foot and decreases additional irritation to the surgical site, minimizing the risk of bleeding into the surgical area. Thereafter, partial weightbearing was allowed for 1 to 2 weeks while wearing a postoperative shoe. The range-of-motion exercises of the ankle were also continued. Postoperative swelling and hematoma were minimized (Fig. 3). Sutures were removed 3 weeks after the operation, and the patients returned to wearing normal shoes at this time. Surgical intervention for the contralateral extremity, if symptomatic, could be scheduled as early as 8 weeks after the first surgery.

Statistical Analyses

Patient satisfaction regarding the mini-incision and single-portal endoscopy approach was assessed using AOFAS scores and self-reported percentages of improvement. Nineteen patients reported their AOFAS scores, and 25 reported their percentage of satisfaction; however, because some patients underwent surgical treatment on both feet, data of each foot were used as independent data points. One patient was excluded from all of the analyses because no AOFAS scores or percentage improvement data were available. A Mann-Whitney *U* test was performed to determine whether satisfaction was greater among patients considered healthy than among those considered unhealthy. "Unhealthy" was considered as having the comorbidities diabetes mellitus, fibromyalgia, chronic obstructive pulmonary disease, heart disease,

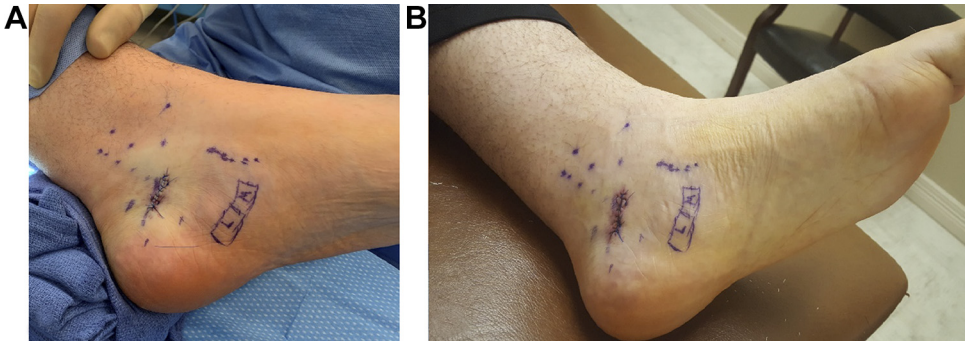

Figure 3. A, Final intraoperative photograph with the incision closed. B, One-week postoperative photograph taken in the clinic.

rheumatoid arthritis, or obesity. A $P < .05$ was considered significant.

Results

All of the patients described an array of subjective symptoms such as numbness, tingling, pain on light touch, shooting pain, burning, cold feet, and radiating ankle-to-foot shocks. All 26 patients experienced a positive Tinel sign when pressure was applied to the tibial nerve in the tarsal tunnel. One patient (3.9%) displayed the Valleix sign. Thirty-one surgeries were performed for 26 patients; of these patients, six (23.0%) were men and 20 were women, with an age range of 30 to 77 years (Table 1). The patients were subcategorized according to age, sex, involvement of left or right foot, and comorbidities (Table 1). Results of the procedures were retrospectively compiled for analysis.

During mean follow-up of 27.3 months (range, 2–64 months), the incidence of subjective improvement was 80% (25 patients). Patients with less improvement had associated nerve disease or a history of injury, which contributed to lower satisfaction with the surgical results. Of all of the patients, 43% and 28% had type 2 diabetes mellitus and secondary nerve pathology at the level of the spine, respectively. However, all of the patients displayed a positive Valleix or Tinel sign and had no soft-tissue or bone abnormalities at the tarsal canal. In this study, histories of back pain, spinal injury, radiculopathy, diabetes mellitus, rheumatoid arthritis, and peripheral nerve diseases were identified in the patient population. Half of the patients met the criteria for double-crush/multiple-crush syndrome, as discussed by MacKinnon and Dellon[20] and Hurst et al.[21]

The total postoperative AOFAS scores ranged from 70 to 100, with a mean AOFAS score of 85.9. No significant difference in the AOFAS scores was found between healthy and unhealthy patients ($P > .05$) (Table 1). The percentage of perceived improvement as reported by patients ranged from 50% to 100%. No significant difference between the two groups regarding their perceived improvement was found ($P > .05$) (Table 1).

Discussion

Endoscopy is minimally invasive and requires only a small incision to visualize and perform surgery.[7,12,15] In this study, the mini-incision and single-portal endoscopy, which were used to perform tarsal tunnel release, provided satisfactory results in all of the patients. The presence of the Valleix or Tinel sign and positive electrodiagnostic results were positive predictive signs of successful improvement after the procedure, as reported previously.[22-25] During the nearly 5-year period of observation for these patients, one (3.85%) experienced a postoperative complication caused by dehiscence and a slow-healing incision site. No cases of hematoma, seroma, or failure to heal were observed. Moreover, the clinical AOFAS scores revealed that the unhealthy and healthy groups benefited from the approach involving mini-incision and single-portal endoscopy. All of the patients reported similar levels of satisfaction with this approach.

The Barrett procedure, which was taught during an Association of Extremity Nerve Surgeons course, involves the use of a single-portal endoscopy to release the tarsal tunnel, allowing fascial decompression of the retinaculum and porta pedis tunnels with standard sharp instrumentation. The proposed surgical technique differs from the Barrett technique because it enables the use of a longer single portal, for better visualization and identification of tunnels of the porta pedis, while the use of a bipolar

electrocoagulator sections the tarsal tunnel retinaculum and fascial layer below the abductor muscle in the porta pedis. We used a 1.5- to 2.0-cm incision portal, angled obliquely parallel to the axis of the calcaneus. The portal allowed access to both the proximal flexor retinaculum and distal porta pedis, with respect to the soft tissue. A longer incision allows optimal visualization to enable identification of the medial and lateral tunnels and enables the surgeon to separate the abductor hallucis muscle from the porta pedis.

The technique presented herein reduces the required dissection compared with that performed during an open procedure and allows the freeing of the retinaculum and tunnels of the porta pedis such that a bipolar electrocoagulator can be used. We believe that the use of a bipolar electrocoagulator is beneficial for long-term recovery because it allows hemostasis and retraction of the fascial tissue. A histologic view of the retinaculum reveals an outer loose connective tissue layer with vascular channels.[26] With a bipolar electrocoagulator, the surgeon can electrocoagulate any bleeding, and simultaneously lyse and seal the retinaculum to prevent bleeding while allowing retraction of the retinacular and fascial edges below the abductor muscle. Cauterization of the fibrous structures of the retinaculum and porta pedis promotes hemostasis, whereas reduced dissection and cauterization lead to less postoperative scar tissue formation and, ultimately, rapid recovery.[27]

Double-crush syndrome, described by Upton and McComas,[27] does not exclude patients from attaining surgical treatment of tarsal tunnel syndrome; however, such patients may not experience the full benefits of tarsal tunnel release. Previous studies have shown that serial nerve constraints observed as proximal impingement or metabolic conditions can predispose the nerve to dysfunction.[28] Based on my experience, six criteria contraindicate the release of the tarsal tunnel using the mini-incision: 1) previous surgery of the tarsal canal causing obstructive scar tissue, 2) soft tissue or bony mass in the tarsal tunnel, 3) Baxter's nerve entrapment, 4) morbid obesity, 5) medial calcaneal nerve entrapment, and 6) plantar fasciitis. Since 2015, MRI has been included in the diagnostic protocol of tarsal tunnel syndrome. Ideally, MRI would report no findings indicating that the shooting pain was caused by a bone fragment, cyst, or tendon pathology. In my opinion and experience, negative MRI findings and positive NCS results favor improved surgical outcomes after tarsal tunnel release.

This retrospective study had limitations that must be acknowledged. First, the follow-up period was not sufficiently long, and several patients were lost to follow-up. In addition, the subjective percentage of improvement was biased. Although the percentage of improvement was valid and clinically meaningful, it was not assessed for reliability as a health measurement. Furthermore, MRI and NCSs were not performed preoperatively before 2015. The decision to proceed with surgery and use the mini-incision was agreed on by the surgeon and patient based on clinical findings. Finally, this retrospective case series is subject to biases that are inherent to any investigation during which the attending surgeon also records outcomes and decides on therapies during the postoperative phase. Despite these limitations, however, the results of this investigation can likely be used for the development of future prospective cohort studies and randomized controlled trials that focus on the surgical treatment of tarsal tunnel syndrome.

Conclusions

My approach involving mini-incision and endoscopy is an appropriate and minimally invasive procedure for the surgical treatment of tarsal tunnel syndrome. Tibial nerve decompression can be achieved at the flexor retinaculum and medial and lateral plantar nerve tunnels in the porta pedis without neurovascular damage, resulting in adequate pain relief, according to the subjective postoperative opinions of the patients involved. This method may result in less postoperative scar formation and early return to weightbearing ambulation on the operated limb. This method is a viable surgical option with a low incidence of complications. Further studies involving a larger patient population are necessary to verify these results.

Acknowledgments: Editage (www.editage.com) for English language editing and K. B. Bjugstad, PhD, for statistical analyses.
Financial Disclosure: None reported.
Conflict of Interest: None reported.

References

1. Kopell HP, Thompson WA: Peripheral entrapment neuropathies of the lower extremity. N Engl J Med **262:** 56, 1960.
2. Lam SJ: A tarsal-tunnel syndrome. Lancet **2:** 1354, 1962.
3. Raikin SM, Minnich JM: Failed tarsal tunnel syndrome surgery. Foot Ankle Clin **8:** 159, 2003.

4. Lau JT, Daniels TR: Tarsal tunnel syndrome: a review of the literature. Foot Ankle Int **20:** 201, 1999.
5. Cimino WR: Tarsal tunnel syndrome: review of the literature. Foot Ankle **11:** 47, 1990.
6. Heimkes B, Posel P, Stotz S, et al: The proximal and distal tarsal tunnel syndromes: an anatomical study. Int Orthop **11:** 193, 1987.
7. Day FN III, Naples JJ: Endoscopic tarsal tunnel release: update 96. J Foot Ankle Surg **35:** 225, 1996.
8. Mahan KT: "Tarsal Tunnel," in *Reconstruction of the Foot and Leg Update 94*, ed by CA Camasta, NS Vickers, JA Ruch, p 6, The Podiatry Institute Inc, Tucker, GA, 1994.
9. Gould JS: The failed tarsal tunnel release. Foot Ankle Clin **16:** 287, 2011.
10. Keck C: The tarsal-tunnel syndrome. J Bone Joint Surg **44:** 180, 1962.
11. Oh SJ, Kim HS, Ahmad BK: The near-nerve sensory nerve conduction in tarsal tunnel syndrome. J Neurol Neurosurg Psychiatry **48:** 999, 1985.
12. Sammarco J, Chang L: Outcome of surgical treatment of tarsal tunnel syndrome. Foot Ankle Int **24:** 125, 2003.
13. Pfeiffer WH, Crachiolo A III: Clinical results after tarsal tunnel decompression. J Bone Joint Surg Am **76:** 1222, 1994.
14. Gkotsoulias EN, Simonson DC, Roukis TS: Outcomes and safety of endoscopic tarsal tunnel decompression: a systematic review. Foot Ankle Spec **7:** 57, 2014.
15. Yoshida A, Okutus I, Hamanaka I: Endoscopic tarsal tunnel syndrome surgery using the universal subcutaneous endoscope system. Asia Pac J Sports Med Arthrosc Rehabil Technol **3:** 1, 2015.
16. Weiman TJ, Patel VG: Treatment of hyperesthetic neuropathic pain in diabetics: decompression of the tarsal tunnel. Ann Surg **221:** 660, 1995.
17. Kitaoka HB, Alexander IJ, Adelaar RS, et al: Clinical rating systems for the ankle-hindfoot, midfoot, hallux, lesser toes. Foot Ankle Int **15:** 349, 1994.
18. Ibrahim TI, Beiri A, Azzabi M, et al: Reliability and validity of the subjective component of the American Orthopaedic Foot and Ankle Society clinical rating scales. J Foot Ankle Surg **46:** 65, 2007.
19. Rosson GD, Larson AR, Williams EH, et al: Tibial nerve decompression in patients with tarsal tunnel syndrome: pressures in the tarsal, medial plantar, and lateral plantar tunnels. Plast Reconstr Surg **124:** 1202, 2009.
20. Mackinnon SE, Dellon AL: "Multiple Crush Syndrome," in *Surgery of the Peripheral Nerve*, Thieme Medical Publishers, New York, 1988.
21. Hurst LC, Weissberg D, Carroll RE: The relationship of the double crush to carpal tunnel syndrome (an analysis of 1,000 cases of carpal tunnel syndrome). J Hand Surg Br **10:** 202, 1985.
22. Dellon AL, Muse VL, Nickerson DS, et al: A positive Tinel sign as predictor of pain relief or sensory recovery after decompression of chronic tibial nerve compression in patients with diabetic neuropathy. J Reconstr Microsurg **28:** 235, 2012.
23. Caffee HH: Treatment of diabetic neuropathy by decompression of the posterior tibial nerve. Plast Reconstr Surg **106:** 813, 2000.
24. Lee CH, Dellon AL: Prognostic ability of a positive Tinel sign in determining outcome for decompression surgery in diabetic and nondiabetic neuropathy. Ann Plast Surg **53:** 523, 2004.
25. Klein DM, Katzman BM, Mesa JA, et al: Histology of the extensor retinaculum of the wrist and the ankle. J Hand Surg Am **24:** 799, 1999.
26. Cordero I: Electrosurgical units: how they work and how to use them safely. Community Eye Health J **28:** 15, 2015.
27. Upton AR, McComas AJ: The double crush in nerve entrapment syndromes. Lancet **302:** 359, 1973.
28. Dellon AL: Treatment of symptomatic diabetic neuropathy by surgical decompression of multiple peripheral nerves. Plast Reconstr Surg **89:** 689, 1992.