Efficacy and Reliability of Percutaneous Gigli Saw Osteotomy in Midfoot Surgery

A Cadaver Study

Muharrem Kanar, MD*
Rodi Ertogrul, MD†
Yunus Oc, MD‡
Elif Nedret Keskinöz, MD§
Bekir Eray Kilinc, PhD‖

Background: Midfoot osteotomy is often used in the surgical treatment of foot deformities. The percutaneous Gigli saw osteotomy (PGSO) technique has many advantages compared with known osteotomy techniques. We aimed to show the efficacy and reliability of the PGSO technique in the midfoot of fresh frozen cadavers without using an image intensifier.

Methods: Four mini-incisions were performed on the dorsomedial, dorsolateral, plantar medial, and plantar lateral regions of the midfoot. Subperiosteal tunnels were then opened with a thin bone elevator, and the four incisions were combined with each other. The Gigli saw was tied to suture material and passed through the tunnels. The PGSO was performed in the midfoot of 12 feet of the cadaver specimens without using an image intensifier. Cadaver specimens were dissected, and injured structures were noted.

Results: The mean ± SD (range) cadaver age was 81.16 ± 10.38 years (65–93 years) and weight was 60.86 ± 12.39 kg (49.8–81.6 kg). All of the osteotomies were adequate as planned in the cuboid-cuneiform level and all of them were complete osteotomy .Incomplete osteotomy was not observed in any cadaver specimens. In one specimen, a complete injury of the peroneal tendons (peroneus longus and brevis) was detected. In another specimen, an incomplete tibialis anterior tendon injury was detected. There was no iatrogenic neurovascular injury in the specimens.

Conclusions: The PGSO technique is recommended for use even by inexperienced surgeons owing to its minimal risk of soft-tissue injury, provision of a complete osteotomy line, and easy application with limited incisions. (J Am Podiatr Med Assoc 112(2), 2022)

Midfoot osteotomy is often used in the surgical treatment of foot deformities caused by pes equinovarus sequelae, Charcot's arthropathy, post-traumatic malunion, rigid pes cavus, metatarsus adductus, and scars from burn or previous surgery.[1–4] Most post-traumatic foot deformity is caused by isolated soft-tissue damage without bone injury because of the poor soft-tissue coverage of the foot.[5]

Conservative treatment with a cast or brace can be applied for foot deformity.[6] However, osteotomy is often required for rigid deformity caused by the ongoing growth period of the pediatric population. Many methods, such as drill osteotomy, osteotomy only, power saw osteotomy, and percutaneous Gigli saw osteotomy (PGSO), are used in the treatment of foot deformity.[7] The main goals of all osteotomies are to protect the neurovascular structures regardless of the technique used and to preserve the periosteal blood circulation of the bone to minimize thermal necrosis.[8,9] Use of a power saw and a high-speed burr can cause necrosis in the osteotomy site.[10] In addition, the energy applied to the

*Department of Orthopaedics and Traumatology, University of Health Sciences, Sisli Hamidiye Etfal Training and Research Hospital, İstanbul, Turkey.

†Yedikule Surp Pirgic Armenian Hospital, İstanbul, Turkey.

‡Bağcılar Hospital, İstanbul, Turkey.

§Department of Anatomy, Acibadem Mehmet Ali Aydinlar University, İstanbul, Turkey.

‖Department of Orthopaedics and Traumatology, University of Health Sciences, Fatih Sultan Mehmet Training and Research Hospital, İstanbul, Turkey.

Corresponding author: Muharrem Kanar, MD, Department of Orthopaedics and Traumatology, University of Health Sciences, Sisli Hamidiye Etfal Training and Research Hospital, 19 Mayıs Mh. Etfal Sk. Şişli Etfal EAH. Şişli İstanbul, 34371 Turkey. (E-mail: dr.kanar@hotmail.com)

osteotomy reduces the vitality and subsequent osteogenic potential in that region. On the other hand, PGSO has several advantages: minimally invasive, reduced damage to the periosteum, provides a low-energy osteotomy, and can be used for every bone in the body. The PGSO technique has many advantages compared with known osteotomy techniques. Using this technique is minimally invasive, requires minimal soft-tissue dissection, and eliminates the risk of incomplete osteotomy.[10]

We hypothesized that PGSO is a safe and effective method in midfoot surgery. This technique can be used for midfoot deformity correction. We aimed to show the efficacy and reliability of the PGSO technique in the midfoot of fresh frozen cadavers without using an image intensifier.

Materials and Methods

This level II study was conducted in the lower extremities of six fresh frozen cadavers in November 2019. Approval for the study was obtained from Acibadem Mehmet Ali Aydinlar University institutional review board (ADATEK) number: 2019/17 .

The demographic changes of the cadavers were recorded. Cadavers that had a deformity or contracture in the foot region or previous foot dissection were excluded from the study. The procedures were performed by two orthopedic surgeons (M.K. and R.E.).

The surgical instruments used for this osteotomy are shown on Figure 1. Osteotomy was performed with four mini-incisions on the plantar medial, plantar lateral, dorsomedial, and dorsolateral regions of the midfoot (Fig. 2). The dorsomedial incision was performed by palpation of the medial cuneiform under the skin to use as a landmark. It was placed proximal inferior to the anterior tibial tendon and distal superior to the insertion of the posterior



Figure 1. The surgical instruments used for the technique.



Figure 2. Mini-incisions of the technique (dorsal view of the left foot).

tibial tendon. The dorsolateral incision was placed proximal to the fifth metatarsal bone on the dorsolateral aspect of the cuboid bone. It was placed proximal superior to the peroneus longus and brevis tendons and proximal inferior to the peroneus tertius tendon. The plantar incisions were performed directly below the border of the tarsal bones medially and laterally.

From these incisions, subperiosteal tunnels were then opened with a thin bone elevator, and the four incisions were combined with the each other. With a thin curved clamp, suture material was used as a guide from the previously opened subperiosteal tunnels, and then the Gigli saw was tied to this suture material and passed through the tunnels. The two ends of the Gigli saw were removed from the skin at the same side laterally (plantar lateral, dorsolateral). The tunnel between the two ends of the Gigli saw was protected with a periosteum elevator. The angle between the two ends of the saw was kept minimally to avoid the soft-tissue injury described elsewhere.[11]

The osteotomy was started from the cuneiform bone medially and ended at the cuboid bone laterally. We performed a midfoot osteotomy without using an image intensifier in the technique. The PGSO was performed in the midfoot of 12 feet of the cadaver specimens. After the osteotomy procedure was completed, all of the cadaver specimens were dissected by two experienced anatomy

specialists (E.N.K.) who were blinded to the specimens' surgeon, and injured structures in the midfoot region were noted.

Results

The study was performed on the lower extremities of six (three male and three female) fresh frozen cadavers. The mean ± SD (range) cadaver age was 81.16 ± 10.38 years (65–93 years) and weight was 60.86 ± 12.39 kg (49.8–81.6 kg).

All of the osteotomies were adequate as planned in the cuboid-cuneiform level and all of them were complete osteotomy (Fig. 3). Incomplete osteotomy was not observed in any cadaver specimens. In one cadaver specimen, a complete injury of the peroneal tendons (peroneus longus and brevis) was detected (Fig. 4). In another cadaver specimen, an incomplete tibialis anterior tendon injury was detected (Fig. 5). There was no iatrogenic neurovascular injury in the cadaver specimens.

Discussion

Although there are tendon injuries in two feet, this minimally invasive technique is an effective and reliable method in midfoot surgery. Despite having tendon injuries during the surgery, this complication can be solved easily with tendon repair during the procedure.

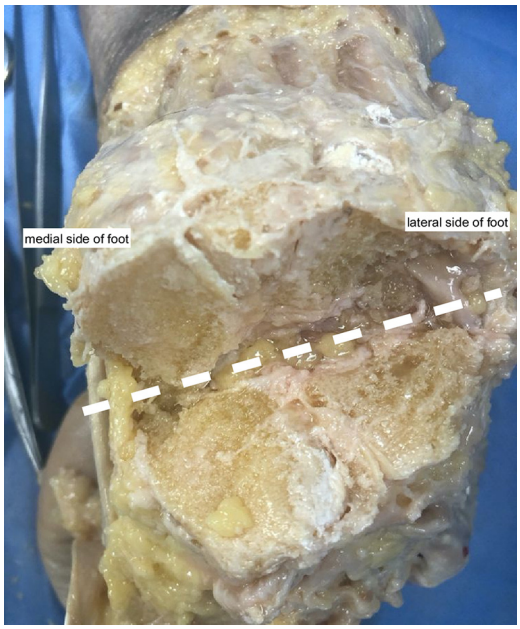

Figure 3. Complete osteotomy and adequate level (cuboid-cuneiform).

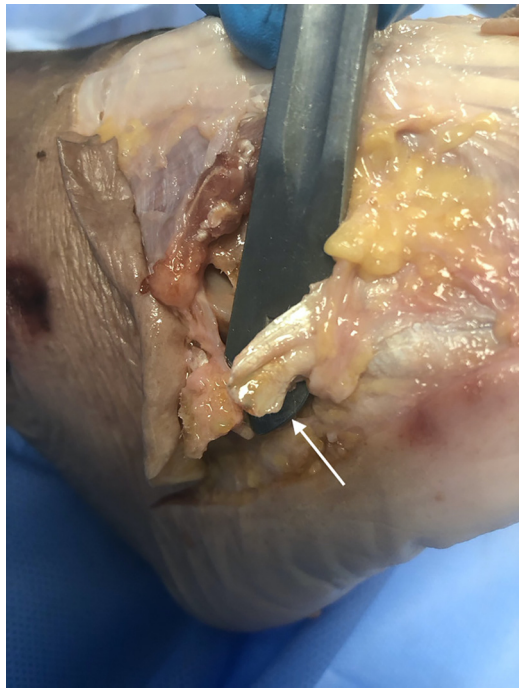

Figure 4. Peroneal tendons' total injury.

Pes equinovarus sequelae, Charcot's arthropathy, rigid pes cavus, and post-traumatic malunion are often corrected with midfoot osteotomy.[1,4] Due to the scar tissue of previous surgery and poor soft-tissue coverage of the foot, it is necessary to avoid



Figure 5. Tibialis anterior tendon partial injury.

traditional open osteotomy techniques with extensive exposure. Many osteotomies can require extensive exposure and dissections to be completed. Extensive exposure increases the risk of neurovascular injury. Some studies reported that extensive exposure was not appropriate for protecting the periosteum and soft tissue around the bone during osteotomy. This can reduce healing in the osteotomy line.[7–12]

The PGSO technique, as a minimally invasive surgery, was first published by Paley and Tetsworth in 1991.[7] This technique is also called "Afghan percutaneous osteotomy."[13] The technique has become widespread and is used frequently in foot deformity correction surgery. Nevertheless, there are serious concerns about neurovascular injury in this procedure during the correction of deformity.[1,14] In addition, a study reported that wound side necrosis was a serious complication in the foot deformity surgery.[15] In PGSO, limited soft-tissue dissection minimalizes the rate of complications such as wound necrosis, soft-tissue infection, and healing problems of the osteotomy line. It is recommended that PGSO be performed by experienced surgeons because of the complex anatomy of the region and to avoid wire breakage during the technique. These limitations were considered disadvantages of the minimally invasive technique.[10,16] Although there are concerns about serious damage to anatomical structures such as vessels and nerves with the PGSO technique, in this study we did not detect any major neurovascular damage in cadaver specimens. The absence of neurovascular damage in any specimen after performing osteotomy showed the advantage of the technique and its reliability.

One study reported that PGSO was recommended for rotational and triplane angular deformity corrections. Furthermore, providing straight and transverse osteotomy lines with this technique facilitates radiologic follow-up.[10] It can also be used with applied intramedullary nails and an external fixator. Another advantage of this technique is its use in short bone segments that need more than one osteotomy. Using a Gigli saw for osteotomy with its low energy stimulates neovascularization in the regeneration region better than using a power saw.[10] One study reported that preservation of the periosteum during osteotomy is important to ensure the quality of regenerated bone and callus.[17] Another study showed that PGSO is superior to the drill osteotomy technique in the healing indexes of the bone.[18] Some studies reported that osteotomy performed by subperiosteal tunnels reduces neurovascular injuries and the risk of soft-tissue problems.[11,19] In the present study, we performed a minimally invasive midfoot osteotomy in cadaver specimens. Small skin incisions provided for the correct placement of the Gigli saw to minimize the risk of soft-tissue injury. We recommend mini subperiosteal tunnels during PGSO in the midfoot region as an effective and reliable technique.

To prevent thermal necrosis during osteotomy in orthopedic surgery, it is important to ensure that the bone temperature does not exceed 45°C during the procedure. Hence, this can produce the regenerated quality.[20] The PGSO is a low-energy technique that makes a smooth cut of the bone and prevents thermal damage in the bone.[21] In the present study, no thermal damage occurred in the bone macroscopically related to the heat of the PGSO technique. This advantage can produce the regenerate for better bone healing in the osteotomy line. One study reported that using an image intensifier was recommended for midfoot PGSO to be sure about the osteotomy line during the procedure.[10] In the present study, although we did not use an image intensifier during the procedure to control the osteotomy line, the osteotomy line was planned before the procedure. This finding showed that using a Gigli saw during the osteotomy without an image intensifier was a reliable technique even in the limited conditions of the surgery room. Although the cadavers had no deformity in the midfoot, we believe that this technique can be used for deformity correction as well.

In foot deformity surgery, it was reported that gradual deformity correction by external fixator was the safest and most effective surgery preference.[22,23] One study reported that the two most common complications in midfoot deformity correction surgeries are pin-tract infection and incomplete osteotomy with early consolidation of the osteotomy line.[13] In the present cadaver study, incomplete osteotomy was not observed in any cadaver specimens. The PGSO technique allowed us to perform the complete osteotomy in the midfoot region. Based on the present study findings, to avoid early consolidation of the osteotomy line during midfoot deformity correction, we strongly recommend PGSO with any kind of fixation method.

The first limitation of this study was the small sample size. Because the study was performed with a limited number of cadavers, it would be better to do this with more clinical practice and long-term follow-up with radiography. In addition, cadaveric specimens did not have any surgery or deformity previously. The absence of scar or fibrous tissue

facilitated performance of the procedure. To avoid bias, the dissections of the feet were performed by two anatomy specialists (E.N.K.) who were blinded to the cadaver specimens' surgeon.

Conclusions

Despite the long learning curve in midfoot surgery, the PGSO technique is recommended for use even by inexperienced surgeons, with its minimal soft-tissue injury, provision of a complete osteotomy line, and easy application with limited incisions.

Financial Disclosure: None reported.
Conflict of Interest: None reported.

References

1. Groner TW, DiDomenico LA: Midfoot osteotomies for the cavus foot. Clin Podiatr Med Surg **22:** 247, 2005.
2. Gordon JE, Luhmann SJ, Dobbs MB, et al: Combined midfoot osteotomy for severe forefoot adductus. J Pediatr Orthop **23:** 74, 2003.
3. Dierauer S, Schäfer D, Hefti F: Osteotomies in the midfoot and the calcaneal part of the foot in relapsed clubfoot. Orthopade **28:** 117, 1999.
4. Lamm BM, Gourdine-Shaw MC, Thabet AM, et al: Distraction osteogenesis for complex foot deformities: Gigli saw midfoot osteotomy with external fixation. J Foot Ankle Surg **53:** 567, 2014.
5. Balaji G, Arokiaraj J, Nithyananth M, et al: Complex post traumatic foot deformities: outcomes after corrective surgery. J Clin Orthop Trauma **11:** 432, 2020.
6. d'Astorg H, Rampal V, Seringe R, et al: Is non-operative management of childhood neurologic cavovarus foot effective? Orthop Traumatol Surg Res **102:** 1087, 2016.
7. Paley D, Tetsworth K: Percutaneous osteotomies: osteotome and Gigli saw techniques. Orthop Clin North Am **22:** 613, 1991.
8. Conti SF, Roukis TS: Corrective ankle osteotomies. Clin Podiatr Med Surg **21:** 353, 2004.
9. Roukis TS: Corrective ankle osteotomies. Clin Podiatr Med Surg **21:** 353, 2004.
10. Wardak MM, Wardak E: Percutaneous Gigli saw osteotomy. Oper Orthop Traumatol **22:** 414, 2010.
11. Stapleton JJ, DiDomenico LA, Zgonis T: Corrective midfoot osteotomies. Clin Podiatr Med Surg **25:** 681, 2008.
12. De Bastiani G, Aldegheri R, Renzi-Brivio L, et al: Limb lengthening by callus distraction (callotasis). J Pediatr Orthop **7:** 129, 1987.
13. Paktis AS, Gross RH: Afghan percutaneous osteotomy. J Pediatr Orthop **13:** 531, 1993.
14. Paley D: The correction of complex foot deformities using Ilizarov's distraction osteotomies. Clin Orthop Relat Res **293:** 97, 1993.
15. Kliushin NM, Sudnitsyn AS, Subramanyam KN, et al: Management of neurologic deformity of the ankle and foot with concurrent osteomyelitis with the Ilizarov method. Foot Ankle Int **39:** 226, 2018.
16. De Prado M: Minimally invasive foot surgery: a paradigm shift. Minim Invasive Surg Foot Ankle **1:** 3, 2011.
17. Kojimoto H, Yasui N, Goto T, et al: Bone lengthening in rabbits by callus distraction: the role of periosteum and endosteum. J Bone Joint Surg Br **70:** 543, 1988.
18. Eralp L, Kocaoglu M, Özkan K, et al: A comparison of two osteotomy techniques for tibial lengthening. Arch Orthop Trauma Surg **124:** 298, 2004.
19. Sen C, Kocaoğlu M, Dinçyürek H, et al: The reliability of percutaneous osteotomy with the Gigli saw technique in the proximal tibia: a cadaveric study. Acta Orthop Traumatol Turc **36:** 136, 2002.
20. Li S, Chien S, Brånemark P: Heat shock-induced necrosis and apoptosis in osteoblasts. J Orthop Res **17:** 891, 1999.
21. Eidelman M, Katzman A, Zaidman M, et al: Deformity correction using supramalleolar Gigli saw osteotomy and Taylor spatial frame: how to perform this osteotomy safely? J Pediatr Orthop B **20:** 318, 2011.
22. Ha J, Hester T, Foley R, et al: Charcot foot reconstruction outcomes: a systematic review. J Clin Orthop Trauma **11:** 357, 2020.
23. Wrotslavsky P, Kriger SJ, Hammer-Nahman SM, et al: Computer-assisted gradual correction of Charcot foot deformities: an in-depth evaluation of stage one of a planned two-stage approach to Charcot reconstruction. J Foot Ankle Surg **59:** 841, 2020.