Delayed Peroneal Neuropathy After Bosworth Fracture Dislocation of the Ankle

Sung Hoon Choi, MD*
Jeong Min Hur, MD*
Kyu-Tae Hwang, MD, PhD*

The Bosworth ankle fracture-dislocation is a rare injury and is often irreducible because of an entrapped proximal fragment of the fibula behind the posterior tibial tubercle. Repeated closed reduction or delayed open reduction may result in several complications. Thus, early open reduction and internal fixation enable a better outcome by minimizing soft-tissue damage. We report on a 27-year-old man who underwent open reduction and internal fixation after multiple attempts at failed closed reduction, complicated by severe soft-tissue swelling, rhabdomyolysis, and delayed peroneal nerve palsy around the ankle. (J Am Podiatr Med Assoc 111(4): 1-6, 2021)

In 1947, Bosworth described five cases of unusual fracture-dislocation of the ankle. The Bosworth ankle fracture-dislocation is a condition with entrapment of the proximal fragment of the distal fibular fracture behind the posterior tibial tubercle.[1] Approximately 60 cases have been reported in the literature since 1947.[2-4]

Various fracture patterns include posterior tibial tubercle fracture, medial malleolus fracture, intact fibula, deltoid ligament rupture, skin defect, compartment syndrome, and/or vascular injury.[5-7] Generally, closed reduction is performed in a patient with a fracture-dislocation of the ankle to minimize the risk of soft-tissue–related complications. In most cases of fracture-dislocation of the ankle, reducing the bone fragments is relatively easily done; however, it is difficult to maintain the reduction with a cast or splint.[8] In most cases, the fractures are treated with open reduction and internal fixation, as closed reduction often fails.[3,9,10]

Early open reduction and internal fixation enables a better outcome by minimizing soft-tissue damage. Delay of treatment may result in malunion and development of severe post-traumatic arthritis.[11] We experienced a closed, irreducible Bosworth fracture-dislocation caused by an incarcerated fibula fragment within the posterior tibial lip fracture. Complications of this case included severe soft-tissue swelling, rhabdomyolysis, and delayed common peroneal nerve palsy. The purpose of this report is to review the result of a patient with Bosworth fracture-dislocation of the ankle and to suggest a high degree of vigilance for early recognition and prompt reduction to prevent complications and long-term morbidity.

*Department of Orthopaedic Surgery, College of Medicine, Hanyang University, Seoul, Republic of Korea.

Corresponding author: Kyu-Tae Hwang, MD, PhD, Department of Orthopaedic Surgery, College of Medicine, Hanyang University, 222 Wangsimni-ro, Seongdong-gu, Seoul 04763, Republic of Korea. (E-mail: md0713@hanmail.net)

Case Report

A 27-year-old man presented to our emergency department after visiting another emergency department several hours earlier. He had sustained a severe external rotation injury to the left ankle while playing in a recreational soccer match, resulting in immediate pain and swelling. Physical examination revealed a severe deformity and swelling of the left ankle, but skin was intact without an open wound. He had intact sensation throughout the foot; was of the dorsalis pedis and posterior tibial arteries were intact. Active flexion and extension of the toes involving the great toe were possible, and there was no evidence of compartment syndrome.

Initial anteroposterior and lateral radiographs after injury showed a lateral malleolar fracture (Weber type B) with posterior malleolar fracture and posterolateral displacement of the talus in relation to the tibia. The proximal fibula was lying posterior to the tibia. In other words, it was classified as a Bosworth fracture-dislocation (Fig. 1). The first attempt to reduce the fracture was



Figure 1. A, Short oblique fracture of the lateral malleolus and subluxation shown on the initial anteroposterior radiograph. B, Posterior subluxation of talus and fracture of the posterior lip of the distal tibia on the lateral radiograph.

undertaken several times at another emergency department. Unfortunately, it failed and resulted in severe swelling of his ankle. At the time of arrival at the emergency department, the visual analog scale (VAS) score was 8 and gentle closed reduction of the ankle was performed under intravenous conscious sedation in our institution; however, the reduction was deemed unsuccessful. After applying a long-leg splint, the patient was subsequently admitted to the orthopedic ward. A computed tomographic scan was obtained to confirm the anatomy and associated fracture. An axial computed tomographic scan showed incarceration of the fibular fragment between the posterior tibial fracture fragments (Fig. 2).

On the second day in the hospital, swelling of the ankle was still severe. In addition, several bullae were observed on the anterior, lateral, and posterior aspects of the left ankle. On the third day in the hospital, the patient suffered from rhabdomyolysis. Massive hydration was started. Unfortunately, on the eighth day in the hospital, dorsiflexion of the great toe was grade 0, delayed peroneal nerve palsy had developed, and the symptom of peroneal neuropathy had not improved. Because the electromyography/nerve conduction studies could not be performed preoperatively because of multiple bullae around the left ankle, delayed peroneal palsy was confirmed through physical examination. Finally, 11 days after the injury, the soft-tissue status around the ankle showed improvement, the patient's VAS score was 6, and the patient underwent open reduction and internal fixation. The ankle was approached by way of a posterolateral incision to the distal fibula. After performing further dissection, it was noted that the proximal part of the fibular fracture was displaced behind the tibia. Then, provisional reduction of the fibula was obtained with clamps, and the fibula was fixed with a distal fibular locking plate and screws (Zimmer, Warsaw, Indiana). In addition, the fracture at the posterior lip of the plafond fracture was noted and reduced in a joystick maneuver and then fixed with a cannulated screw and washer, and the ruptured deltoid ligament was reconstructed. The syndesmosis was unstable and a syndesmotic screw was placed across three cortices (Fig. 3). Postoperatively, the VAS score decreased to 4, a short-leg splint was applied for 3 weeks, and a plaster cast was applied for 2 weeks. The screw across the syndesmosis was left in place for 12 weeks, during which time the patient remained nonweightbearing. After removal of the screw, weightbearing was allowed as tolerated. At 4 months postoperatively, we observed that the patient's peroneal palsy began to improve on an outpatient basis. At the latest follow-up at 12 months, the fractured ankle had achieved bony union (Fig. 4); however, he still had mild pain and mild stiffness of the ankle (10° of dorsiflexion, 30° of plantarflexion, 10° of inversion, and 5° of eversion).

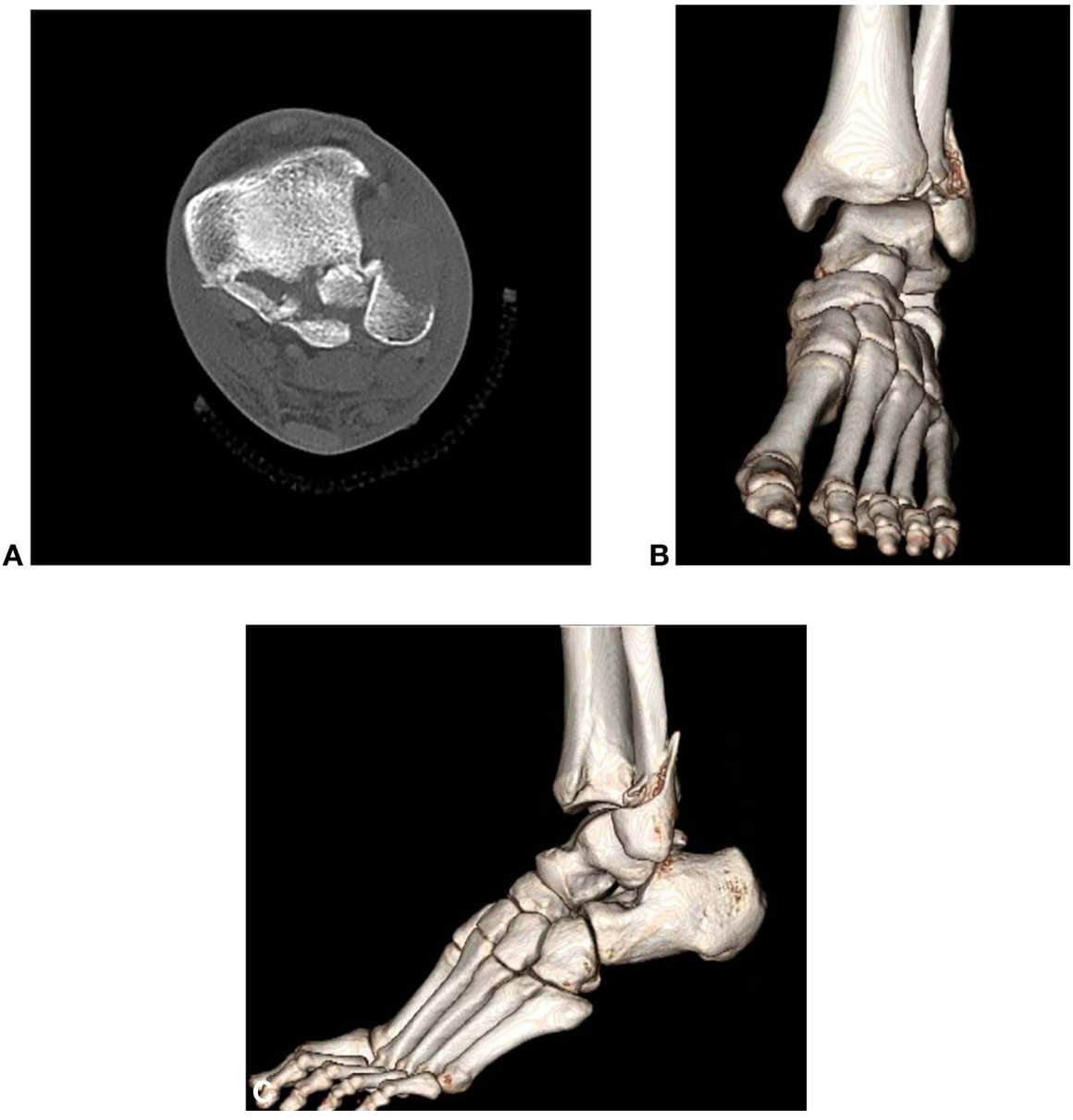

Figure 2. A, Axial computed tomographic scan shows entrapment of the proximal fibula behind the tibia. B, Three-dimensional reconstruction shows posterior dislocation of the distal fragment of the fibula. C, Lateral image of three-dimensional computed tomographic reconstruction shows fibula entrapped behind the posterior of the distal tibia.

The patient's deep and superficial peroneal neuropathy was confirmed by electromyography and nerve conduction study and recovered at 12 months after injury (Tables 1 and 2). Informed consent was obtained from the patient for publication of data from this case, including the photographs.

Discussion

Bosworth fracture-dislocation of the ankle is a rare injury and is frequently missed in the primary care setting. This diagnosis should always be kept in mind in cases of fracture-dislocation of the ankle.[12]

In most cases of Bosworth fracture-dislocation, closed reduction fails because of incarcerated fibula fragment within the posterior tibial lip fracture. Forceful closed reduction of the dislocated ankle or repeated attempts is not advisable, as it can cause additional soft-tissue trauma, especially around the fibula.[8]

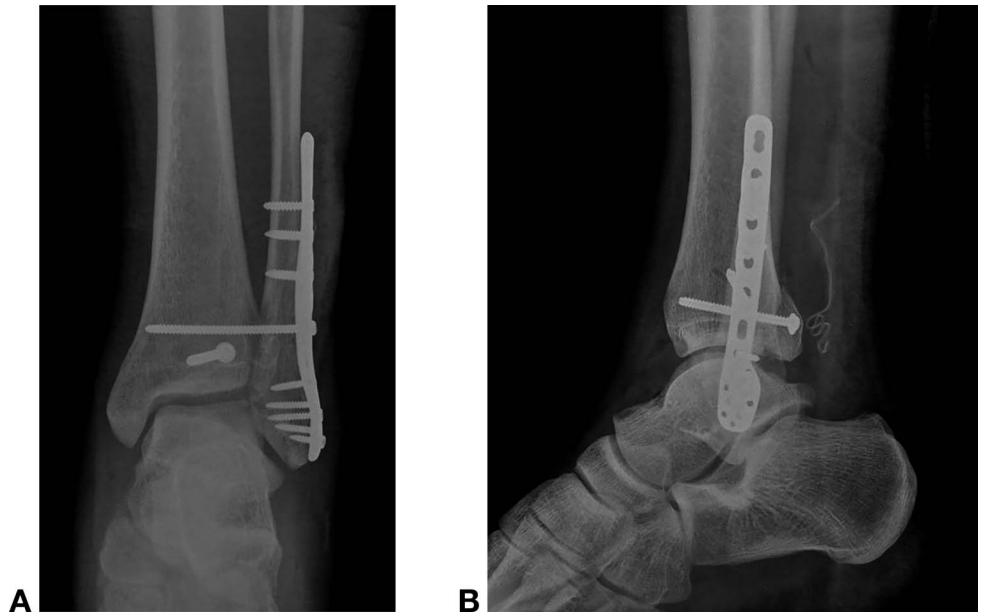

Figure 3. A, Radiograph of the left ankle after open reduction and internal fixation through the posterolateral approach. B, Postoperative lateral radiograph shows reduction and fixation of the posterior lip of the distal tibia.

This type of fracture-dislocation can be accompanied by various complications (acute or chronic), such as compartment syndrome,[13,14] ankle stiffness,[8] and skin necrosis.[11] In our case, there were several complications: rhabdomyolysis, stiffness of the ankle, and delayed deep peroneal nerve (DPN) and superficial peroneal nerve (SPN) palsy at the level of the ankle.

To the best of our knowledge, this is the first case of a closed, irreducible Bosworth fracture-dislocation involving delayed SPN and SPN palsy around the ankle. We suggest two hypotheses regarding the mechanism of this injury. First, the fact that the traction injury can occur over the DPN and the SPN supports peroneal neuropathy. In this case, there was anteromedial displacement of the tibia in

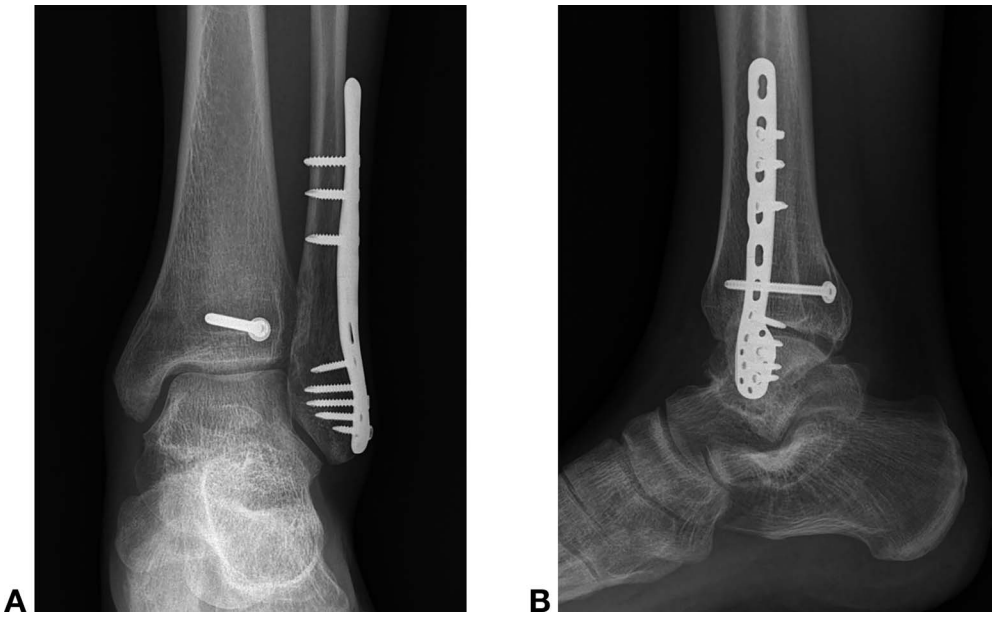

Figure 4. A, Anteroposterior radiograph at last follow-up. B, Lateral radiograph at last follow-up.

Table 1. Findings of the Nerve Conduction Study

Site	Onset (ms)	Peak (ms)	Amplitude (mV)	Distance (cm)	Velocity (m/sec)
Left peroneal motor (EDB)					
Ankle	NR	—	—	—	—
BF	NR	—	—	—	—
Right peroneal motor (EDB)					
Ankle	3.2	5.9	10.9	34.0	49.0
BF	10.1	13.0	10.0		
Left peroneal motor (TA)					
Fibular head	2.7	4.6	3.1	8.0	47.0
Popliteal	4.4	5.9	2.6		
Right peroneal motor (TA)					
Fibular head	2.9	10.0	8.5	8.0	57.0
Popliteal	4.3	11.3	7.7		
Left tibial motor (AHB)					
Ankle	3.4	7.9	10.5	41.0	47.0
Knee	12.2	16.9	8.6		
Right tibial motor (AHB)					
Ankle	4.5	7.4	13.8	41.0	53.0
Knee	12.3	15.5	12.1		
Left superficial peroneal antisensory					
Ant Lat Mall	2.3	2.9	10.8	14.0	61.0
Right superficial peroneal antisensory					
Ant Lat Mall	3.0	3.5	14.0	14.0	47.0
Left sural antisensory					
Lat Mall	2.7	3.3	10.2	14.0	52.0

Abbreviations: AHB, abductor hallucis brevis; Ant Lat Mall, anterior lateral malleolus; BF, below fibular head; EDB, extensor digitorum brevis; Lat Mall, lateral malleolus; NR, no response; TA, tibialis anterior.

relation to the talus and permanent internal rotation of the tibia for several days because closed reduction had failed. Therefore, nerve fibers and endoneurial tubes of the DPN and SPN could have been damaged by anteromedial traction force for several days resulting in delayed neuropathy. Second, the DPN and SPN can be damaged by swelling or hemorrhage inside the nerve. As mentioned previously, Nobel[15] reported two cases of peroneal neuropathy caused by hematoma inside the peroneal nerve sheath. Similarly, in the current case, the torsional forces that occurred during the trauma (supination and external rotation) transmitted the traction force along the peroneal nerve around the ankle and dissected the nutritional vessels of the nerve, resulting in delayed deep and superficial peroneal neuropathy. These mechanisms are not still clear; further case series study is necessary.

Table 2. Findings of the Needle Electromyography Study in the Left Lower Extremity

Muscle	IA	Fibs	PSW	Amp	Dur	Poly	Interference Pattern
Both paraspinalis (L3–S1)	N	N	N	N	N	N	N
Gluteus medius	N	N	N	N	N	N	N
Vastus medialis	N	N	N	N	N	N	N
Biceps femoris (short)	N	N	N	N	N	N	N
Tibialis anterior	Incr	N	N	Incr	N	Incr	Decr
Peroneus longus	N	N	N	N	N	N	N
Peroneus brevis	Incr	N	N	Incr	Incr	Incr	Decr
Extensor digitorum brevis	Incr	N	N	N	N	Incr	Decr
Gastrocnemius (medial)	N	N	N	N	N	N	N

Abbreviations: Amp, amplitude; Decr, decreased; Dur, duration; Fibs, fibrillations; IA, insertional activity; Incr, increased; N, normal; PSW, positive sharp wave; Poly, polyphasic potential.

Conclusions

In conclusion, Bosworth fracture-dislocation of the ankle is a rare injury, and delayed peroneal neuropathy at the ankle level after ankle injury is exceedingly rare. Not only immediate peroneal neuropathy but also delayed neuropathy around the ankle can occur after ankle injury, including Bosworth fracture-dislocation. Therefore, a high degree of vigilance regarding neuropathy must be maintained when managing Bosworth injury.

Financial Disclosure: None reported.
Conflict of Interest: None reported.

References

1. Cecil ML, Fenton PJ, Ebraheim NA: Fracture-dislocation of the ankle with fixed displacement of the fibula behind the tibia. Orthop Rev **22:** 1255, 1993.
2. Khan F, Borton D: A constant radiological sign in Bosworth's fractures: "the Axilla sign". Foot Ankle Int **29:** 55, 2008.
3. Delasotta LA, Hansen RH III, Sands AK: Surgical management of the posterior fibula fracture dislocation: case report. Foot Ankle Int **34:** 1443, 2013.
4. Schepers T, Hagenaars T, Den Hartog D: An irreducible ankle fracture dislocation: the Bosworth injury. J Foot Ankle Surg **51:** 501, 2012.
5. Collins RS, O'Connor D, Denton JR: An irreducible distal fibula dislocation while in-line skating. J Orthop Trauma **12:** 364, 1998.
6. Tipton WW, D'Ambrosia RD: Vascular impairment as a result of fracture-dislocation of the ankle. J Trauma **15:** 524, 1975.
7. Ermis MN, Yagmurlu MF, Kilinc AS, et al: Irreducible fracture dislocation of the ankle caused by tibialis posterior tendon interposition. J Foot Ankle Surg **49:** 166, 2010.
8. Lui TH, Chan KB, Kong CC, et al: Ankle stiffness after Bosworth fracture dislocation of the ankle. Arch Orthop Trauma Surg **128:** 49, 2008.
9. Bartonicek J, Fric V, Svatos F, et al: Bosworth-type fibular entrapment injuries of the ankle: the Bosworth lesion. A report of 6 cases and literature review. J Orthop Trauma **21:** 710, 2007.
10. Wright SE, Legg A, Davies MB: A contemporary approach to the management of a Bosworth injury. Injury **43:** 252, 2012.
11. Yeoh CS, Tan GM: Bosworth fracture-dislocation of the ankle: a case report. J Orthop Surg (Hong Kong) **21:** 249, 2013.
12. Fahey JJ, Schlenker LT, Stauffer RC: Fracture dislocation of the ankle with fixed displacement of the fibula behind the tibia. Am J Roentgenol Radium Ther Nucl Med **76:** 1102, 1956.
13. Beekman R, Watson JT: Bosworth fracture-dislocation and resultant compartment syndrome. A case report. J Bone Joint Surg Am **85:** 2211, 2003.
14. Szalay MD, Roberts JB: Compartment syndrome after Bosworth fracture-dislocation of the ankle: a case report. J Orthop Trauma **15:** 301, 2001.
15. Nobel W: Peroneal palsy due to hematoma in the common peroneal nerve sheath after distal torsional fractures and inversion ankle sprains. J Bone Joint Surg Am **48:** 1484, 1966.