Posterior Tibial Tendon Dysfunction

A Review

Beverley Durrant, MSc Clin Pod Bio, BSc(Hons) Pod*
Nachiappan Chockalingam, PhD†
Farina Hashmi, PhD†

Posterior tibial tendon dysfunction is a progressive deformity that can result in the development of a pathologic flatfoot deformity. Numerous publications have studied the effects of clinical interventions at specific stages of progression of posterior tibial tendon dysfunction, but there is still uncertainty regarding the clinical identification of the condition. It is clear that more information regarding the etiology, progression, and risk factors of posterior tibial tendon dysfunction is required. Clear evidence exists that suggests that the quality of life for patients with posterior tibial tendon dysfunction is significantly affected. Furthermore, evidence suggests that early conservative intervention can significantly improve quality of life regarding disability, function, and pain. This would suggest that significant cost burden reductions could be made by improving awareness of the condition, which would improve early diagnosis. Early conservative intervention may help reduce the number of patients requiring surgery. This review focuses on the etiologic factors, epidemiologic features, and pathogenesis of posterior tibial tendon dysfunction. It aims to analyze, discuss, and debate the current understanding of this condition using the available literature. In addition, there is a discussion of the evidence base surrounding disease characteristics associated with the different clinical stages of posterior tibial tendon dysfunction. (J Am Podiatr Med Assoc 101(2): 176-186, 2011)

The posterior tibial muscle is situated in the deep posterior compartment of the leg. It affects the function of the subtalar and midtarsal joints during gait, providing an inversion moment at the subtalar joint.[1, 2] Posterior tibial tendon dysfunction (PTTD) is a common cause of pathologic flatfoot deformity in adults[3] that when left untreated can lead to considerable functional impairment and, consequently, have a detrimental effect on the quality of life of the individual involved. Although numerous publications have studied the effects of clinical interventions at specific stages of PTTD progression, there is still uncertainty regarding the clinical identification of the condition in the foot. In the absence of a standardized set of clinical descriptors that has undergone scientific validation for clinical application for each stage of PTTD, the provision of effective treatment interventions becomes difficult to evaluate. Because there is a lack of clarity regarding progression, any attempt to evaluate the efficacy of intervention is difficult, especially because one of the aims of treatment is to reduce progression.

It is clear that more information regarding the etiology, progression, and risk factors of PTTD is required to ensure that timely and appropriate interventions are used not only to alleviate the burden of the cost to the National Health Service but also to prevent deterioration of the quality of life of the individuals involved. Most publications related to outcomes for PTTD report on surgical interventions or outcome data of surgical procedures.[4-6] These data, although valuable, inform clinicians of the value of specific surgical procedures at a point when the patient has a progressing flatfoot deformity and surgery is deemed to be the best, and often only, option. It is, therefore, vital that interventions are administered early in the progression of this condition.

Clear evidence exists that suggests that the quality of life for patients with PTTD is significantly

*Podiatry, University of Brighton, Eastbourne, East Sussex, England.
†Faculty of Health, Staffordshire University, Stoke-on-Trent, England.
Corresponding author: Beverley Durrant, MSc Clin Pod Bio, BSc(Hons) Pod, Podiatry, University of Brighton, 49 Darley Rd, Eastbourne, East Sussex BN21 2HR, England. (E-mail: b.durrant@brighton.ac.uk)

affected. Furthermore, evidence suggests that early conservative intervention can significantly improve quality of life regarding disability, function, and pain.[7] This suggests that significant cost burden reductions could be made by improving awareness of the condition, which would improve early diagnosis. Early conservative intervention may help reduce the number of patients requiring surgery.

This review focuses on the etiologic factors, epidemiologic features, and pathogenesis of PTTD. It aims to analyze, discuss, and debate the current understanding of PTTD using the available literature. In addition, there is a discussion of the evidence base surrounding disease characteristics associated with the different clinical stages of PTTD. This review discusses the methods used to measure these characteristics and, therefore, explores the quantification of tissue changes in the tendon with time, including changes in the function of the muscle. To achieve this, the discussion includes biochemical and kinematic analyses.

Search Strategy

Databases that were searched include PubMed, MEDLINE (1950 to present), SportDiscus, AMED (1980 to present), CINAHL (1981 to present), BMJ Clinical Evidence, Cochrane Library, ISI Web of Knowledge (Science) (1990 to present), IngentaConnect, Science Citation Index, ScienceDirect, and Wiley Interscience; we also performed online searches of *The Foot*, *Podiatry Now* (nonindexed), and the *British Journal of Podiatry*.

Key words used include *posterior tibial tendon dysfunction*, *posterior tibial tendon insufficiency*, *posterior tibial tendon function*, *PTTD*, *TPTD*, *posterior tendon pathology*, *PT pathology*, *posterior tibial tendon rupture*, *posterior tibial tendon classification*, *foot kinematics*, and *foot AND/OR ankle kinematics*. All of the articles used were published in the English language. Owing to the exploratory nature of this review, we did not use strict inclusion/exclusion criteria.

Structure and Function of the PTT

The PTT originates from the posterior aspect of the interosseous membrane and from the superior two-thirds of the medial part of the posterior aspect of the fibula (Fig. 1).[8] It also takes part origin from the superior aspect of the posterior tibia and the intermuscular septa of the adjacent muscles of the posterior compartment. Many studies have confirmed its function to be predominantly occurring during the stance phase.[9-11] Because of its orientation with the subtalar joint and the ankle joint axis, the PTT is a plantarflexor at the ankle joint and an invertor of the foot at the subtalar joint and is, therefore, known as a main supinator of the foot during stance (Fig. 2).[1, 2, 11]

Epidemiologic Features and Prevalence of PTTD

Little information is available relating to the epidemiologic features of PTTD; however, what is available suggests that middle-aged women and older people are the most common groups affected.[12-15] Johnson[14] reports on findings from a small ($n = 11$) surgical study indicating that the average age (49 years) of participants recruited to this study suggests that PTTD is a condition of adult women. However, because the study was concerned only with the diagnosis and management of total tendon rupture, it offers little to the understanding of the epidemiologic features of the broader PTTD. Because the sample size was small and little information is available regarding the design of the study, it is difficult to assess whether this study represents a true clinical picture.

In a more recent study, Holmes and Mann[13] studied the possible epidemiologic factors associated with PTT rupture. The study involved the retrospective analysis of medical records of 67 patients with a flatfoot deformity or PTT rupture. The analysis revealed that the pathologic abnormalities predominantly presented in women aged 51 and 87 years. Although this study has added to the existing knowledge of PTTD, it must be acknowledged that the study design was nonexperimental, and, owing to the small sample size, there are many confounding variables that could not be accounted for in the data analysis. For example, no information was given about the time since diagnosis of hypertension, diabetes, and obesity. There is also no information regarding the severity of these conditions. It may be that most of the study cohort had well-controlled newly diagnosed hypertension or, conversely, long-standing poorly controlled hypertension. No data are presented to confirm whether some of the cohort may have been double counted if presenting with comorbidities such as obesity coupled with hypertension. The raw data presented seem to point to a variety of patients in this situation; however, this fact is not accounted for in the analysis. There is also no information available for stage of disease at diagnosis. This has significance because knowing what the risk

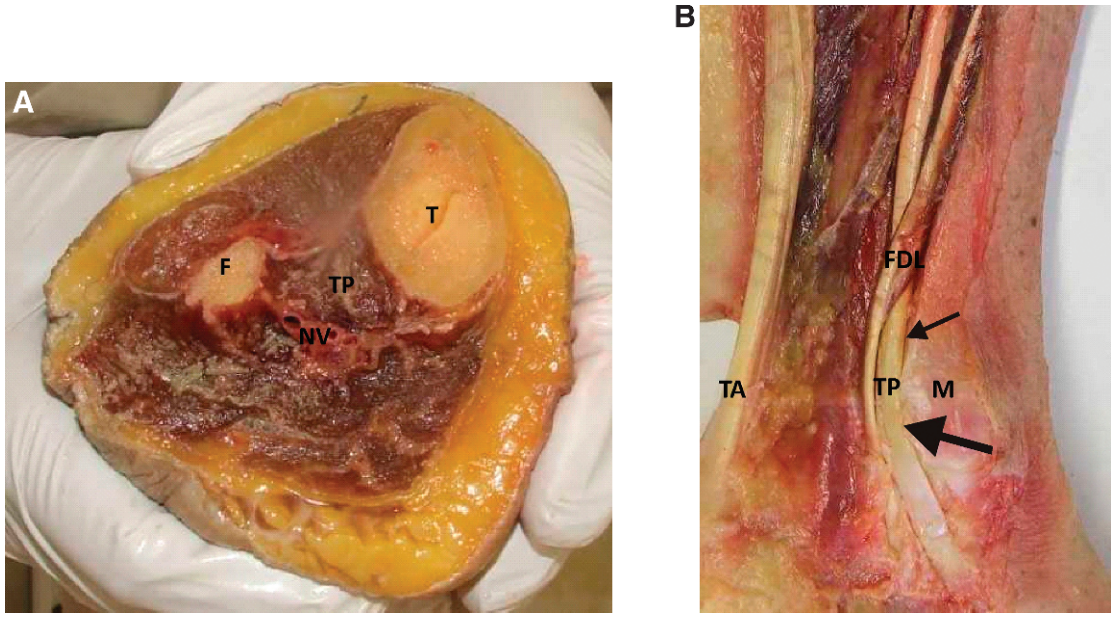

Figure 1. Images showing the anatomical location of the posterior tibial muscle. A, Disarticulation at the knee and the position of the posterior tibial muscle in situ. B, Retromalleolar region. The small arrow indicates a rounded appearance of the tibialis posterior tendon, and the large arrow indicates a more flattened appearance at the retromalleolar region. F indicates fibula; FDL, flexor digitorum longus; M, malleoli; NV, neurovascular bundle; T, tibia; TA, tendo Achillis; and TP, tibialis posterior. (From Semple et al.[8])

factors are would be advantageous only if coupled with early diagnosis and early intervention of the condition. The data suggest that perhaps most patients in the older age group (51 of 67 patients) had received a progressed late-stage diagnosis because the confirmation of posterior tibial rupture was made at the time of surgery. The retrospective

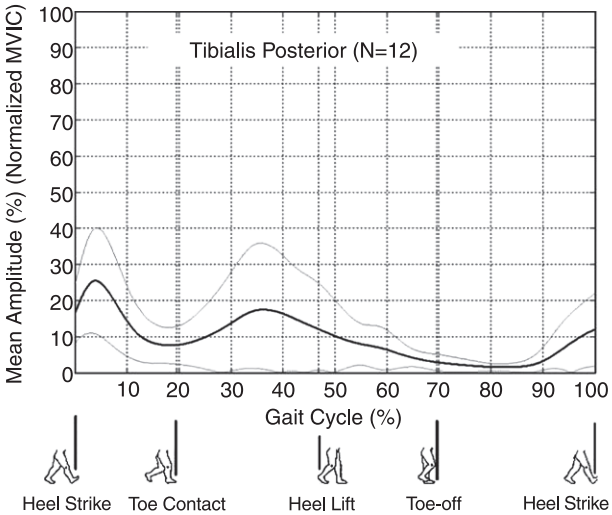

Figure 2. The activity of the tibialis posterior muscle for a normal neutral foot type. (Reprinted from the *Journal of Electromyography* with permission from Murley et al[11] and Elsevier.)

nature of the study means that these confounding variables could not be accounted for.

Note that the data were extracted from the patient notes at certain time points. For example, the results suggest that the mean time from symptom onset to diagnosis of PTTD was 2 years. Because there is no information regarding a prediagnosis period, this delayed diagnosis could be an important factor leading to the rupture of the PTT. It could be possible that the tendon gradually degenerates across 2 years as a consequence of abnormal lower-limb biomechanics. This is a reasonable hypothesis if it is accepted that this disorder is progressive. To support these data and test these hypotheses, future studies should aim to be prospective in design and should consider using a larger sample size and more robust data collection procedures.

Pomeroy et al[15] and Fenn and Chiodo[12] cite Holmes and Mann[13] in two review articles providing an overview and discussion of current concepts of PTTD; however, neither article provides any new information regarding the epidemiologic features of this condition. Only one published study,[16] to our knowledge, has addressed the question of the prevalence of PTTD in the UK population. Moreover, this is the only study to date that has reported prevalence data for PTTD. Participants were asked

to complete a questionnaire that asked them to confirm whether they had problems with their feet and whether they thought that they had flat feet. Patients were then asked specific questions relating to their foot pain and foot shape. For example, patients were asked whether their foot shape had changed and whether they had arch pain or whether there was swelling present on the inside of the ankle. The questionnaire was distributed to a population of female patients older than 40 years. The participants were selected at random from a general practitioner practice database of general patients registered at the practice. The database was kept up-to-date by the practice staff. There were 1,922 female patients in the practice who were 40 years or older. A random number generator then selected 1,000 of these patients to complete the questionnaire.

Of 582 women who completed the questionnaire, 360 (61.9%) reported no problems with their feet. Two hundred twenty-two participants (38.1%) indicated that they did have foot problems, with 106 (18.2%) reporting forefoot problems only. The remaining 116 participants (19.9%) were contacted by telephone to clarify the nature of their foot problems, and 79 of those (13.6%) were asked to attend the podiatric medical clinic for a more detailed assessment. Seventy-five percent of these individuals attended their appointment; a diagnosis of symptomatic flatfoot was made in nine cases, seven patients were diagnosed as having stage I PTTD and 12 as having stage II PTTD, and a further nine were diagnosed as having acquired adult flatfoot deformity. Of the 37 patients with diagnoses, only five had been previously given a diagnosis and were receiving specialist care. The prevalence, therefore, was 6.6% for flatfoot abnormalities and 3.3% for PTTD.

Although this study has made a considerable contribution to the understanding of the prevalence of PTTD, it also highlights the fundamental problems associated with the accurate diagnosis of PTTD, in particular the classification of stage I. This information adds to the previous discussion in that PTTD is often diagnosed at a later stage and, therefore, there is a significant delay in the patient receiving therapeutic interventions. This gap in the knowledge of the identification of the early stages of PTTD and lack of understanding of the progression of the disease places emphasis on the need to come to a universal understanding among clinicians of the standardized classification of the stages of PTTD development. Without this key information, including the validation of assessment tools, the collection of epidemiologic and prevalence data will inevitably be inaccurate. These stages are listed and discussed in detail in the "Classification and the Progression of PTTD" section.

Etiology

There is a lack of consensus surrounding the etiology of PTTD. Researchers working in the field of musculoskeletal medicine differ in their opinions regarding the causes of PTTD, describing the condition as having an unknown etiology or a poorly understood complex etiology. Because the pathogenesis of the development and progression of PTTD involves the disruption and disorganization of specific tissues in the tendon, the etiology of the condition is multifarious. This is exemplified by the associated changes in other soft-tissue structures such as plantar ligaments.[17, 18] Although this research has not identified the precise role of ligaments in the diagnosis, etiology, and contribution to PTTD, the results suggest that most individuals with PTTD also present with a damaged superomedial component of the spring ligament and significant abnormalities in the sinus tarsi, particularly to the talocalcaneal interosseous ligament.[17]

A further study by Deland et al[18] reported the presence of abnormalities in numerous ligaments of the foot in patients diagnosed as having PTTD. Using magnetic resonance imaging (comparing age-matched controls), Deland et al[18] identified that the superomedial component of the spring ligament was "at risk" for injury compared with other ligaments likely to affect the profile of the medial longitudinal arch.

Information regarding the stage of PTTD at the time of diagnosis of the participants in the studies is unclear. Without this information, it is impossible to establish at what point the PTT becomes truly dysfunctional in terms of the development of pes planus and, therefore, at what point the plantar ligament becomes involved in the dysfunction. It is possible that abnormalities observed in the spring ligament could occur before involvement of the PTT in pathologic flatfoot.

PTTD and Spring Ligament Involvement

The contribution of spring ligament dysfunction to the development of a flatfoot deformity has been debated in the literature.[19-21] It seems that this ligament may be a key structure in maintaining the integrity and the architecture of the foot. The function of the spring ligament is thought to be

associated with the subtalar joint and the medial longitudinal arch.[21] The calcaneonavicular ligament, as it is also known, is reported to have a primary function in providing stability to the medial longitudinal arch of the foot. In addition, it is thought to provide support to the talar head by contributing to the formation of the articular cavity or acetabulum pedis.[21] It has been suggested that the spring ligament has some involvement in the development of PTTD. However, there remains some debate over the anatomical makeup of the spring ligament itself.[19] Some authors refer to the superomedial and inferior aspects of the ligament,[19] and others refer to a third component[20, 21] that is often overlooked but could be significant when defining the role of this ligament (Fig. 3).[20] Research involving sectioning the spring ligament in cadaveric specimens[19] and in vivo magnetic resonance imaging assessment of the spring ligament in patients with a diagnosis of PTTD suggests that this ligament may play a more vital role than originally thought.

Work conducted by Mengiardi et al[21] and Taniguchi et al[20] identified the presence of a "third ligament" in the spring ligament complex. The authors consistently found the third portion of the ligament. This was apparent in the cadaver dissections (n = 5) and in the magnetic resonance imaging for the asymptomatic subjects (n = 78) and the cadaver images.

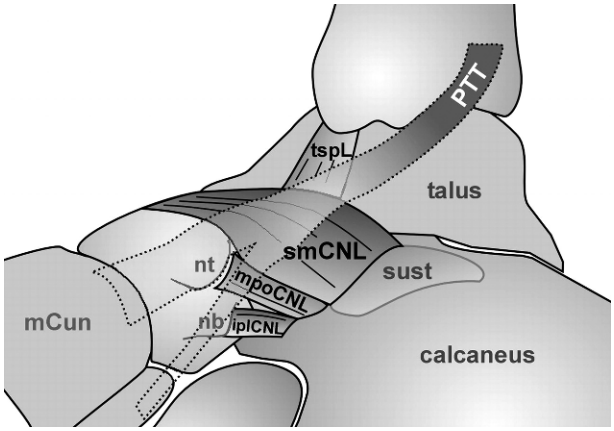

Figure 3. A schematic diagram of the proposed tripartite spring ligament. ipICNL indicates inferoplantar longitudinal calcaneonavicular ligament; mCun, medial cuneiform; mpoCNL, medioplantar oblique calcaneonavicular ligament; nb, beak of navicular bone; nt, tuberosity of navicular bone; PTT, posterior tibial tendon; smCNL, superomedial calcaneonavicular ligament; sust, sustentaculum tali; and tspL, tibiospring ligament. (Reprinted with permission from Mengiardi et al[21] and the Radiological Society of North America.)

The tripartite ligament runs from between the middle and anterior calcaneal facets to the navicular tuberosity. The superomedial component runs along the anterior border of the middle facet of the calcaneus. The superficial fibers of the ligament merge with the tendon sheath of the PTT, and the deeper fibers insert onto the medial articular facet of the navicular bone. The inferior component runs along the notch between the anterior and middle facets of the calcaneum and insert onto the navicular beak (Fig. 3).[21]

Jennings and Christensen[19] attempted to establish the contribution that the spring ligament makes to the development of flatfoot deformity. Their five-specimen cadaver study attempted to mimic the stance phase of gait. Having dissected out the main muscle compartments of the leg, exposing the main tendons (triceps surae, peroneus longus and brevis, flexor digitorum longus, flexor hallucis longus, and PTT), each structure was subjected to a loading pattern replicating load during the stance phase of gait. Each musculotendinous structure was tested before and after sectioning of the spring ligament and before and after sectioning of the PTT. Each structure was loaded at 0%, 50%, 100%, and 150% of its calculated force strength during the stance phase. Three-dimensional kinematic analysis was used to measure the positions and rotations of the talus, navicular, and calcaneus bones. The results suggest that sectioning of the spring ligament complex significantly alters the architecture of the foot and that with reloading of the PTT, these changes are not significantly reduced. This suggests that the primary etiologic factor involved in the development of flatfoot deformity may rest with an inefficient spring ligament complex. However, there are a variety of issues with this type of study. The study gives no added information as to whether PTT insufficiency occurs as a primary or secondary problem. The foot posture of the cadaver specimens is also unknown. This may be a limitation because previous studies have suggested that abnormal foot posture could place an individual with a preexisting tendency at risk for PTTD.[22, 23] The specimens were loaded 100 times to mimic ambulation, suggesting that this simulation represents 100 steps. Considering that the average individual may walk in excess of 1,000 steps and up to 10,000 steps a day, this is suggestive of significantly reduced mobility and arguably does not come close to a "real situation." This may be important particularly because PTTD is referred to as a progressive disorder and is assessed clinically in this way.[5, 24, 25] The fact that a midstance simulation was performed and that the

PTT is actually most active during the beginning and end of the stance phase and not at the midstance point is a significant limitation. This study suggests that the spring ligament seems to have a significant function in maintaining the stability of the foot and the arch profile of the foot, but it says little about its interaction with the PTT. This remains one of the unanswered questions facing clinicians.

Histologic Analysis of the PTT

The histologic characteristics of the PTT have been studied in normal and pathologic specimens. Smith[26] notes that early-stage PTTD is characterized by an acute tendinitis giving rise to inflammatory cell proliferation and that with progression of the deformity, continued collagen disorientation with vascular "ingrowth" becomes a prominent feature.

Blake et al[27] suggest that inflammation may contribute to damage to the tendon with the infiltration of inflammatory mediators, with degradative enzymes leading to cellular and tissue damage. Bare and Haddad,[28] citing Holmes and Mann,[13] suggest that tenosynovitis occurs in 16% of tenosynovitis and paratendinitis affecting the ankle, although it is unclear from the study by Bare and Haddad[28] how this figure is derived and is not stated by Holmes and Mann.[13] This highlights the belief that the inflammatory process is considered to be one of the possible etiologic and precipitating factors; however, there is conflicting evidence to support this view in the literature.

In adult human tissue, collagen type I is the major constituent of tendons and ligaments. A variety of studies have attempted to analyze the histologic features of the tendon and the histochemical changes that take place in the presence of dysfunction. Mosier et al[29] studied 15 surgical PTTs and 15 normal cadaver tendons. The surgical tendons were all graded at stage II, representing early-stage to midstage dysfunction. The surgical tendons were found to be 1.4 times the dorsoplantar diameter and 1.9 times the mediolateral diameter of the cadaver tendons, and this difference was found to be significant ($P < .0001$). The results reveal differences in the microscopic appearance of the two sets of tendons. Of particular interest were pale areas indicating increased mucin content: also noted was the location of fibrous tissue surrounding the blood vessels, between collagen bundles, and in the substance of the collagen bundle itself, with disorganization of the collagen bundles and interference of the normal linear orientation of the fibers as a result. Fibroblast hypercellularity and neovascularization were also identified in the surgery tendons, with a corresponding increase in size, number, and branching of small blood vessels.

This earlier work[29] has been supported by others.[10, 30] The term *tendinitis* may not be an inappropriate term to use for some tendon abnormalities.[31] Fowble et al[30] studied the histopathologic findings of 28 PTTs associated with stage II and stage III PTTD. Their samples were all taken from the same anatomical location at the time of surgical repair. Each sample was tested for vascularization, mucoid change, chondrometaplasia, tenocyte cellularity, and tendon layer thickness. The results of this study seem to suggest that there are certainly significant histopathologic changes noted in their sample; however, similar to others, there was little evidence that there was inflammation present. One of the main findings suggests that neovascularization accounts for much of the change seen in the collagen fibrils.

The findings from this study are consistent with those from Mosier et al,[29] and additionally they found that neovascular infiltration was the most prevalent finding and thought to be the main reason for the collagen disorganization.[30] The authors did not find evidence of inflammation or ischemic change. Of interest is the authors' observation that there was no clear difference in the histopathologic features seen in grade 2 and 3 tendon dysfunction. The authors suggest as a possible explanation for their findings that perhaps a damaging event, or stretching in some way of the PTT, may trigger the histopathologic changes seen. If this is the case, then further work needs to be performed at the early stages of this disorder to establish whether prophylactic intervention to off-load the structure may result in slowing down the development of the dysfunction. However, biopsies in early-stage PTTD are not clinically or ethically appropriate, and, therefore, other methods of identification would be required.

In addition to disruption of the collagen, the type of collagen present in normal versus diseased tendons has also received a mention in the literature. Tendons are thought to be predominantly composed of type I collagen and much smaller amounts of types III, IV, and V collagen[32]; however, recent research into the composition of diseased PTTs has suggested that this collagen type changes in the presence of dysfunction.[33, 34] A reduction in type I collagen (40%) and increases in type V collagen (26%) and type III collagen (53%) have been reported.[33]

An often-quoted clinical phrase is that there is a hypovascular area approximately 2 to 4 cm proximal to the insertion point on the navicular bone and distal to the medial malleolus. Clinical reasoning suggests that these locations are significant as it relates to the two points that are likely to undergo the highest stress: the retromalleolar area, because of the potential compression of the tendon against the malleolus as the tendon changes direction, and the navicular bone, because it is the main insertion point. However, although this reasoning is plausible, the evidence to support it is varied.

Harris,[35] cited by Frey et al,[36] was the first to suggest that there may be a link with hypovascularity and pathologic abnormality at the PTT. Results from a 28-tendon cadaver study report consistently observing hypovascularity at the midportion of the tendon.[36] Petersen et al[37] hypothesize that there may be an avascular (as opposed to a hypovascular) region at this point. However, this point remains controversial, and more recent research has challenged this assertion.[38]

Prado et al[38] report findings from an 80-tendon cadaver study that are in direct contrast to those of Petersen et al[37] and Frey et al.[36] The results indicate that there were no significant differences related to sex, age, and the selection of the tendon studied (either left or right); however, significant findings were confirmed for the vascular density increasing toward more distal segments. The three studies reviewed all found differing results using different methods. There are inconsistencies in the selection criteria and in the number of tendons recruited to the studies. None of the studies report on the assessment of dysfunctional PTTs. For these reasons, it is not possible to say that insufficient vascular supply is responsible for the degenerative changes seen in PTTD.

Classification and the Progression of PTTD

The development of assessment criteria for PTTD has largely been led by the orthopedic community. The existing criteria suggest that it is possible to identify discrete stages in the clinical signs and symptoms of the progression of the pathologic abnormality.[5, 24, 25] The adoption of this approach will allow for the identification of a relationship between the presenting symptoms and clinical features of specific stages of PTTD. Such a framework for the classification of different stages of PTTD is essential for successful clinical diagnosis; however, the scientific rigor surrounding the sensitivity and specificity of the clinical features at each stage is limited, and there is a paucity of published work in this area.

Currently, the classification models used in clinical practice include surgical interventions for stages of PTTD, in addition to suggestions for conservative management in the early stages. Such classification systems are subject to interpretation and, therefore, may experience interrater and intrarater variability. Because the current classification systems are aimed predominantly at providing a framework that may ultimately aid timely surgical intervention, there is little recognition or acknowledgment in the literature of the merits of early conservative management that could be provided by the podiatric medical profession. As already discussed previously herein, research has shown that PTTD is often poorly diagnosed,[39, 40] and it is perhaps the lack of quantitative measures to establish the progression of the deformity that inhibits awareness of this condition.

In 1989, Johnson and Strom[5] reported on the various stages of the pathologic condition as it progressed. This three-stage classification system, along with the suggested treatment and management, remained the main classification criteria for approximately 10 years. At that point, a fourth stage was added to the classification in recognition that the Johnson and Strom system did not accommodate all of the variations seen clinically.[5, 25] Myerson[25] added a fourth stage to the classification, identifying that at end stage the rearfoot is in a valgus state and is rigid, with the only treatment option available being a fixed ankle-foot orthosis and a triple arthrodesis of the rearfoot and ankle.

In 2007, Bluman et al[24] published a redefined classification system that has several subdivisions for each stage (I–IV), taking into account other previously unclassified signs such as forefoot supination, forefoot abduction, and medial column instability. Stage I is identified as paratendinitis or partial rupture and is further subdivided into inflammatory disease secondary to systemic disease, partial tear with "normal" rearfoot anatomy, and partial tear with mild rearfoot valgus.

Stage II features are identified as significant attenuation of the tendon or frank rupture. Stage II is subdivided into three subcategories, and the first subcategory is further divided twice more. Stage IIa recognizes rearfoot valgus as the main defining feature, and some forefoot supination may also be apparent. Stage IIa1 is characterized by the definitive presence of forefoot varus on correction of the valgus forefoot. The forefoot varus is flexible

and can be passively corrected. Stage IIa2 is characterized by a rigid, fixed forefoot varus. The rearfoot remains flexible.

Stage IIb is characterized by forefoot abduction usually in conjunction with rearfoot valgus. The midtarsal joint complex may be the primary joint involvement or the metatarsal cuneiform joints, commonly presenting as osteoarthritis of the second metatarsal cuneiform joint. These features are best viewed on radiographs to distinguish them.[24]

Stage IIc is characterized by medial first-ray instability, this being the most salient presentation of this stage. The authors state that the unstable first ray causes the rearfoot to pronate. The forefoot remains in supination (forefoot varus) and is fixed. The foot, according to Bluman et al,[24] when placed in neutral at the rearfoot causes the first ray to dorsiflex, thereby causing the subtalar joint to pronate, causing impingement. However, the alternative way of viewing this, and the more conventional way, is to suggest that as the abnormality progresses, the rearfoot progresses into a valgus position. This, in turn, causes the first ray, which is a mobile unit, to progress into a dorsiflexed position. During the propulsive phase of gait, the windlass mechanism is inhibited and the gait becomes apropulsive or at least lateral loading. The other reason for the rearfoot to pronate would be to compensate for the forefoot varus or, as described by Bluman et al,[24] forefoot supination. This would not allow sufficient forefoot contact to occur at midstance or forefoot loading and would render the foot unstable as a result of the subtalar joint compensatory pronation. This, again, would have the net effect of pushing the first ray into dorsiflexion, inhibiting the windlass mechanism, and rendering the entire foot unstable and apropulsive and having a negative effect on the PTT and the remaining ligaments attempting to resist abnormal rearfoot pronation.

The final stages are not dissimilar to each other and to previously published guidelines, both referring to a rigid rearfoot deformity. Stage III is associated with advanced tendon rupture and is characterized by rearfoot valgus that is rigid, and there may also be a forefoot deformity, and often rigid forefoot abduction. Stage IV is associated with advanced stage also displaying the signs of a rigid flat foot affecting both the rearfoot and midcourt forefoot, but also includes a group with iatrogenic tibiotalar valgus, where misalignment may have occurred. There is also likely to be deltoid ligament insufficiency.

Using this classification system, all stages except stage I require surgical intervention ranging from tendon transfer to triple arthrodesis. Although the stage I criteria acknowledge that there may not be any rupture present, the subcategories accommodate nonrupture only when referring to inflammatory disease, where the paratenon may be inflamed secondary to systemic disease such as rheumatoid arthritis.

One problem with the currently available classification systems is the focus of the model. The three main classification systems in clinical use have been presented as work that builds on the previously proposed classification. For example, the work of Myerson[25] builds on the work of Johnson and Strom,[5] and the work of Bluman et al[24] builds on the work of Myerson[25] and Johnson and Strom.[5] However, the title of the classification changes throughout, and, hence, the focus of the refined classification also changes. The original classification proposed by Johnson and Strom[5] refers to PTTD. This suggests a broad range of presentations of the condition from early onset through total rupture. However, the latest reiteration[24] refers to PTT rupture, suggesting a much narrower focus. This leads to potential confusion because each successive author claims to have refined or expanded on the earlier work. This may be so, but it is also important to consider the focus of the work presented.

It seems that there is no consensus regarding the terminology used to describe the condition and, more notably, little recognition of the fact that there is evidence to suggest that if diagnosis is made early, then conservative intervention that could be provided by a podiatric physician may negate or at least defer the need for a surgical referral and subsequent surgical intervention. If a combination of approaches could be adopted using conservative podiatric medical intervention with surgical intervention when indicated, it may reduce the need for more radical surgery, which carries significant undesirable effects on foot function.

Although it is generally accepted clinically and from the available published evidence that PTTD is progressive and leads to an acquired flatfoot deformity, one publication seems to contradict this accepted understanding. Yeap et al[23] investigated the effect of PTT transfer and the consequence on foot shape and development of pathologic flatfoot deformity. The study findings suggest that acquired adult flatfoot deformity may not be the result of a PTTD. The research claims that in the small sample group studied, none of the patients demonstrated

the signs of PTTD or consequent flatfoot deformity. However, certain problems with the work presented make it difficult to evaluate. The sample size is small (n = 17). In the 17 patients included in the study, the time from surgery to retrospective follow-up ranged from 7.5 months to 25 years. The patients seen were being investigated and treated for footdrop not PTTD. It seems that this fact is a fundamental flaw in the structure of the project. The results of this study have not undergone statistical analysis and, therefore, remain unclear as to their significance.

Kinematic and Kinetic Changes in PTTD

Kinematic (movement) analysis and kinetic (force) characteristics can provide a comprehensive picture of the changes that may take place in foot and ankle movement during gait in the presence of a pathologic abnormality. Sophisticated equipment can detect small changes in movement and force. Data processing software can build an accurate and reliable "model" of the way in which a patient mobilizes during gait and give information regarding the forces involved in bringing about such movement.

Changes in the kinematic and kinetic variables in patients with PTTD are an underexplored area, with only a few studies reporting findings specifically relating to foot function. In 1999, Rattanaprasert et al[41] reported the three-dimensional kinematics of one case without a functioning PTT and compared them with a mean of data collected from ten healthy individuals. The results report differences in rearfoot and forefoot motions, with most of the differences occurring through late stance and propulsion. Sagittal plane motion with the leg relative to the rearfoot and with the forefoot relative to the rearfoot and adduction/abduction range of motion was particularly different. Temporal characteristics also changed when comparing the PTTD case with the amalgamated mean figures for the ten healthy individuals. Although this study gives insight into possible changes that might occur in PTTD, because the case used was atypical of a classic presentation of PTTD, it is not possible to say whether these data provide an accurate picture of the changes seen in PTTD.

Tome et al[42] analyzed three-dimensional kinematics of patients with stage II dysfunction compared with individuals in a control group for rearfoot eversion and inversion, medial longitudinal arch angle, and forefoot abduction and adduction. The results suggest that patients with PTTD demonstrate significantly more rearfoot eversion, a greater medial longitudinal arch angle, and increased abduction of the forefoot. These findings are consistent with others.[43, 44] The authors conclude that for this group of patients there is a failure of secondary ligamentous support to control foot kinematics and individuals with stage II dysfunction.

More recently, a comprehensive analysis of foot kinematics and kinetics for this group with PTTD was presented by Ringleb et al,[44] albeit using a small sample size. This study reports on the electromyographic activity, foot pressure data, motion data, and force plate data in a small group of patients reported to have stage II dysfunction.[44] This study reports significant differences in midfoot and rearfoot kinematics compared with healthy individuals. Nonsignificant increases in rearfoot eversion were reported, seemingly in direct contrast to what would be expected with this condition.

The electromyographic data suggested that in addition to an increase of activity in the second half of the stance phase for the tibialis posterior muscle, the same is also true for the tibialis anterior muscle and the gastrocnemius soleus complex, with increased, prolonged activity in the peroneus longus muscle. There was a reported phasic reversal for the peroneus brevis muscle compared with healthy individuals. Foot pressure data showed a significant medial shift in peak pressures.

The surprising results reported for nonsignificant eversion of the foot in PTTD compared with healthy individuals may have had to do with the way in which the baseline data had been collected. The authors' state that the position used for the baseline was relaxed standing. Therefore, if the foot was already maximally pronated, there would be no further scope for additional pronation to occur, and, therefore, this may have seemed to indicate that there was an insignificant increase in eversion compared with healthy individuals. The participants used for comparison were taken from a database of previously collected data and, therefore, were not matched controls. These individuals had not been collected specifically for this trial. Therefore, it is conceivable that the data collection procedure may have varied, yielding differences in the reported findings.

A more recent study[43] investigating kinematic changes in patients with PTTD reports similar findings as Ringleb et al[44] except for rearfoot eversion, which showed a significant increase. Ness et al[43] report on findings from 25 participants, again using previously collected data for the comparison.

The four-segment Milwaukee foot model was used to collect data from the tibia, rearfoot, forefoot, and hallux, with motion measured to the segment proximal to it. In addition, temporal and spatial parameters of gait were studied. The findings seem comparable with those from Ringleb et al[44] with one notable difference. The data presented for rearfoot eversion show a significant increase as opposed to the nonsignificant increase reported by Ringleb et al.[44] Reduction in dorsiflexion was also seen in the sagittal plane for the rearfoot. Overall, range-of-motion deficits were seen throughout most of the stance phase of gait. Significant reductions were also seen in the hallux sagittal plane range of motion. However, with an increase in rearfoot eversion, this would have an expected detrimental effect on the function of the first ray, preventing a successful windlass maneuver to occur and perhaps causing a functional hallux limitus. Information for nonweightbearing values are not reported. Further clarity regarding the significance of the differences in motion found at the rearfoot would be useful, as would an indication of the level of significance. Stance phase duration, stride length, cadence, and walking speed were all seen to decrease in the PTTD group compared with the healthy asymptomatic group.

Summary

This review identified that not only is there little or no consensus in the literature regarding current understanding of the etiologic makeup of PTTD, but there also seems to be little consensus regarding assessment of the condition, the terminology used to describe the condition, and the best approach to treatment of the condition. Therefore, these gaps in the understanding of this debilitating condition must be bridged if there is to be a streamlined approach to patient care. Although the plethora of research regarding treatment relates to surgical intervention, the latest research suggests that early intervention with conservative treatment could be advantageous to patient mobility and, therefore, ability to manage on a daily basis progression of the deformity. However, the crucial link here is early diagnosis. The existing prevalence studies have shown that this condition is poorly diagnosed. Therefore, any new research that could raise awareness among health care professionals to aid early diagnosis and immediate conservative treatment can be viewed only as a positive step forward. Podiatric physicians are in an ideal position to deliver this. The current prevalence studies suggest that patients may have already progressed too far for conservative management because they have a late or missed diagnosis. Some general practitioners or family physicians may also delay referral to orthopedic teams so as not to overburden the service, and they may not refer to podiatric medicine either, risking progression of the disorder and its subsequent sequelae.

For this condition to be recognized as a significant musculoskeletal disorder, further work must be undertaken to establish a clearer understanding of the etiologic factors that affect progression. Furthermore, if podiatric physicians are going to be recognized for their work in the early diagnosis and early provision of conservative intervention, the profession must be ready to engage in the cutting-edge research needed to establish and consolidate our current understanding of this debilitating condition.

Financial Disclosure: None reported.
Conflict of Interest: None reported.

References

1. Funk D, Cass J, Johnson K: Acquired adult flat foot secondary to posterior tibial-tendon pathology. J Bone Joint Surg Am **68:** 95, 1986.
2. Mueller TJ: Acquired adult flat foot secondary to tibialis posterior dysfunction: biomechanical aspects. J Foot Surg **30:** 2, 1991.
3. Weinraub GM, Heilala MA: Adult flatfoot/posterior tibial tendon dysfunction: outcomes analysis of surgical treatment utilizing an algorithmic approach. J Foot Ankle Surg **39:** 359, 2000.
4. Jahss M: Spontaneous rupture of the tibialis posterior tendon: clinical findings, tenographic studies, and a new technique of repair. Foot Ankle **3:** 158, 1982.
5. Johnson KA, Strom DE: Tibialis posterior tendon dysfunction. Clin Orthop Relat Res **239:** 196, 1989.
6. Wainwright AM, Kelly AJ, Glew D, et al: Classification and management of tibialis posterior tendon injuries according to magnetic resonance imaging findings. The Foot **6:** 66, 1996.
7. Kulig K, Reischl SF, Pomrantz AB, et al: Nonsurgical management of posterior tibial tendon dysfunction with orthoses and resistive exercise: a randomized controlled trial. Phys Ther **89:** 26, 2009.
8. Semple R, Murley G, Woodburn J, et al: Tibialis posterior in health and disease: a review of structure and function with specific reference to electromyographic studies. BMC J Foot Ankle Res **2:** 24, 2009.
9. Basmajian JV, Stecko G: The role of muscles in arch support of the foot: an electromyographic study. J Bone Joint Surg Am **45:** 1184, 1963.
10. Mosier SM, Pomeroy G, Manoli A II: Pathoanatomy and

etiology of posterior tibial tendon dysfunction. Clin Orthop Relat Res **365:** 12, 1999.
11. Murley GS, Buldt AK, Trump PJ, et al: Tibialis posterior EMG activity during barefoot walking in people with neutral foot posture. J Electromyogr Kinesiol **19:** e69, 2009.
12. Fenn P, Chiodo CP: Current literature review: posterior tibial tendon dysfunction. Curr Opin Orthop **17:** 91, 2006.
13. Holmes G, Mann RA: Possible epidemiological factors associated with rupture of the posterior tibial tendon. Foot Ankle Int **13:** 70, 1992.
14. Johnson K: Tibialis posterior tendon rupture. Clin Orthop **177:** 140, 1983.
15. Pomeroy GC, Pike RH, Beals TC, et al: Acquired flatfoot in adults due to dysfunction of the posterior tibial tendon. J Bone Joint Surg Am **81:** 1173, 1999.
16. Kohls-Gatzoulis J, Woods B, Angel JC, et al: The prevalence of symptomatic posterior tibialis tendon dysfunction in women over the age of 40 in England. Foot Ankle Surg **15:** 75, 2009.
17. Balen PF, Helms CA: Association of posterior tibial tendon injury with spring ligament injury, sinus tarsi abnormality, and plantar fasciitis on MR imaging. AJR Am J Roentgenol **176:** 1137, 2001.
18. Deland J, Sung AR, Ernberg I, et al: Posterior tibial tendon insufficiency: which ligaments are involved? Foot Ankle Int **26:** 427, 2005.
19. Jennings MM, Christensen JC: The effects of sectioning the spring ligament on rearfoot stability and posterior tibial tendon efficiency. J Foot Ankle Surg **47:** 219, 2008.
20. Taniguchi A, Tanaka Y, Takakura Y, et al: Anatomy of the spring ligament. J Bone Joint Surg Am **85:** 2174, 2003.
21. Mengiardi B, Zanetti M, Schottle P, et al: Spring ligament complex: MR imaging-anatomic correlation and findings in asymptomatic subjects. Radiology **237:** 242, 2005.
22. Dyal CM, Feder J, Deland JT, et al: Pes planus in patients with posterior tibial tendon insufficiency: asymptomatic versus symptomatic foot. Foot Ankle Int **18:** 85, 1997.
23. Yeap JS, Singh D, Birch R: Tibialis posterior tendon dysfunction: a primary or secondary problem? Foot Ankle Int **22:** 51, 2001.
24. Bluman EM, Title CI, Myerson MS: Posterior tibial tendon rupture: a refined classification system. Foot Ankle Clin **12:** 233, 2007.
25. Myerson MS: Instructional Course Lectures, The American Academy of Orthopaedic Surgeons: adult acquired flatfoot deformity: treatment of dysfunction of the posterior tibial tendon. J Bone Joint Surg Am **78:** 780, 1996.
26. Smith CF: Anatomy, function and the pathophysiology of the posterior tibial tendon. Clin Podiatr Med Surg **16:** 399, 1999.
27. Blake RL, Anderson K, Fergusson H: Posterior tibial tendinitis: a literature review with case reports. JAPMA **84:** 141, 1994.
28. Bare AA, Haddad SL: Tenosynovitis of the posterior tibial tendon. Foot Ankle Clin **6:** 37, 2001.
29. Mosier SM, Lucas DR, Pomeroy G, et al: Pathology of the posterior tibial tendon in posterior tibial tendon insufficiency. Foot Ankle Int **19:** 520, 1998.
30. Fowble A, Vigorita V, Bryk E, et al: Neovascularity in chronic posterior tibial tendon insufficiency. Clin Orthop Relat Res **450:** 225, 2006.
31. Rees JD, Wilson AM, Wolman RL: Current concepts in the management of tendon disorders. Rheumatology **45:** 508, 2006.
32. Satomi É, Teodoro WR, Parra ER, et al: Changes in histoanatomical distribution of types I, III and V collagen promote adaptative remodeling in posterior tibial tendon rupture. Clinics (Sao Paulo) **63:** 9, 2008.
33. Gonçalves-Neto J, Witzel S, Teodoro WR, et al: Changes in collagen matrix composition in human posterior tibial tendon dysfunction. Joint Bone Spine **69:** 189, 2002.
34. Kannus P, Jozsa L: Histopathological changes preceding spontaneous rupture of a tendon: a controlled study of 891 patients. J Bone Joint Surg Am **73:** 1507, 1991.
35. Harris H: The assessment of foot function anatomical and clinical considerations. Lancet **242:** 32, 1942.
36. Frey C, Shereff M, Greenidge N: Vascularity of the posterior tibial tendon. J Bone Joint Surg Am **72:** 884, 1990.
37. Petersen W, Hohmann G, Stein V, et al: The blood supply of the posterior tibial tendon. J Bone Joint Surg Br **84:** 141, 2002.
38. Prado M, de Carvalho AE Jr, Rodrigues CJ, et al: Vascular density of the posterior tibial tendon: a cadaver study. Foot Ankle Int **27:** 628, 2006.
39. Kohls-Gatzoulis J, Angel J, Singh D: Tibialis posterior dysfunction as a cause of flatfeet in elderly patients. The Foot **14:** 207, 2004.
40. Kohls-Gatzoulis J, Angel J, Singh D, et al: Tibialis posterior dysfunction: a common and treatable cause of adult acquired flatfoot. BMJ **329:** 1328, 2004.
41. Rattanaprasert U, Smith R, Sullivan M, et al: Three-dimensional kinematics of the forefoot, rearfoot, and leg without the function of tibialis posterior in comparison with normals during stance phase of walking. Clin Biomech **14:** 14, 1999.
42. Tome J, Nawoczenski D, Flemister A, et al: Comparison of foot kinematics between subjects with posterior tibial tendon dysfunction and healthy controls. J Orthop Sports Phys Ther **36:** 635, 2006.
43. Ness ME, Long J, Marks R, et al: Foot and ankle kinematics in patients with posterior tibial tendon dysfunction. Gait Posture **27:** 331, 2008.
44. Ringleb SI, Kavros SJ, Kotajarvi BR, et al: Changes in gait associated with acute stage II posterior tibial tendon dysfunction. Gait Posture **25:** 555, 2007.