Current Oncology

MDPI

Case Report

Treatment Response to Lenvatinib in Metastatic Adenoid Cystic Triple-Negative Breast Cancer: A Case Report

Blair Hoeting [1], Amber Friedman [2], Sumina Goel [2] and Kai C. C. Johnson [2,*]

[1] College of Medicine, The Ohio State University, Columbus, OH 43210, USA; blair.hoeting@osumc.edu
[2] James Comprehensive Cancer Center, The Ohio State University, Columbus, OH 43210, USA; amber.friedman@osumc.edu (A.F.); sumina.goel@osumc.edu (S.G.)
* Correspondence: kai.johnson2@osumc.edu; Tel.: +1-614-366-8541

Simple Summary

Adenoid cystic carcinoma of the breast is a rare form of breast cancer that typically grows slowly. When it spreads, treatment can be challenging because standard chemotherapy may be poorly tolerated or less effective, and few established treatment options exist. Lenvatinib is a targeted cancer medication that has shown activity against adenoid cystic carcinomas arising in other parts of the body, but its use in breast cancer of this type has not been previously reported. We describe a 68-year-old woman whose cancer spread to her lungs and the lining around her lungs after initial treatment. Following disease progression and difficulty tolerating chemotherapy, she received lenvatinib. Her breathing improved, fluid accumulation around her lungs decreased, and imaging showed reduced tumor burden and sustained disease control. This case suggests that lenvatinib may be a potential treatment option for patients with metastatic adenoid cystic breast cancer.

Abstract

While typically low-grade at diagnosis, cases of metastatic adenoid cystic carcinoma of the breast (ACCB) have been reported. Standardized treatment guidelines are lacking, particularly for triple-negative breast cancer (TNBC), as targeted therapy options are limited. We report a case of metastatic adenoid cystic TNBC demonstrating clinical and radiographic response to lenvatinib, a VEGF-directed receptor tyrosine kinase inhibitor. A 68-year-old female underwent mastectomy for stage II (pT2N0) adenoid cystic TNBC and declined adjuvant chemotherapy. After four years of surveillance, she presented with dyspnea and was found to have pulmonary metastases. She underwent two rounds of stereotactic radiation, then began taking capecitabine, which was discontinued after two months due to intolerance and development of a pulmonary embolism. After another year of surveillance, imaging demonstrated progressive pulmonary and pleural disease, confirmed by biopsy and PET. We trialed a course of lenvatinib (18 mg daily). Her dyspnea improved, and pleural fluid re-accumulation decreased. PET imaging demonstrated reduced pulmonary nodule size and pleural effusion. She has undergone thirteen 28-day cycles to date. To our knowledge, this is the first reported case of lenvatinib use for metastatic adenoid cystic TNBC. The observed clinical and radiographic response suggests lenvatinib may offer a novel therapeutic avenue warranting further investigation.

Keywords: adenoid cystic carcinoma of the breast; triple negative breast cancer; lenvatinib; metastatic; VEGF

Check for updates

Received: 26 October 2026
Revised: 23 November 2026
Accepted: 27 November 2026
Published: 28 November 2026

Copyright: © 2026 by the authors. Licensee MDPI, Basel, Switzerland. This article is an open access article distributed under the terms and conditions of the Creative Commons Attribution (CC BY) license.

1. Introduction

Adenoid cystic carcinoma (ACC) is a histologic subtype of cancer that is pathologically described as an invasive ductal carcinoma characterized by luminal epithelial and basaloid/myoepithelial cells. These tumors often originate from salivary tissue, with breast origin representing approximately 13% of cases [1]. Clinically, these tumors tend to grow in a slow manner. Due to this, ACC rarely reaches the point of widespread metastatic distribution, though occasionally such cases occur. Here, we describe such a case.

Historically, adenoid cystic carcinoma of the breast (ACCB) has been shown to be minimally responsive to conventional chemotherapy [2–4]. Specifically, in the neoadjuvant space, achievement of pathological complete response on surgical pathology is rarely documented following neoadjuvant chemotherapy [2,3]. Even when examining the application of chemotherapy for more aggressive histologic subtypes of ACCB, such as solid basaloid ACCB, chemotherapy receipt has similarly not been shown to reduce cancer recurrence risk [2,3]. Therefore, alternative systemic therapies are needed for management.

Preclinical models have suggested that ACC grows in part due to AKT and MAPK pathways [5]. Given this, there is interest in applying therapies that target this vulnerability within ACC. Lenvatinib, a multi-targeted tyrosine kinase inhibitor, exerts its effects through inhibition of pathways implicated in tumor angiogenesis and proliferation, including VEGF, FGFR, and downstream MAPK and PI3K/Akt signaling. In light of preclinical evidence suggesting that ACC tumorigenesis is driven, in part, by these pathways, lenvatinib represents a rational therapeutic candidate.

Clinically, lenvatinib has been shown to be efficacious in the management of several solid tumor subtypes, including medullary thyroid cancer, renal cell carcinoma, and hepatocellular carcinoma. Tchekmedyian et al. demonstrated in their phase 2 study that patients with a recurrent or metastatic ACC of any primary source treated with lenvatinib had an objective response rate (ORR) of 15.6% of their participants and a disease control rate (DCR) of 90.6% [6]. In a phase 3 trial, Shulmberger et al. showed that patients with radioiodine-refractory thyroid cancer had an ORR of 64.8% to lenvatinib and a DCR of 87.7% [7]. Other multi-targeted tyrosine kinase inhibitors have also been used to treat ACC, such as axitinib, which was demonstrated by Ho et al. to have an ORR of 9.1% and DCR of 84.8% in a phase 2 study [8]. Given the established activity of lenvatinib in malignancies driven by similar signaling pathways, there is a strong rationale to explore its use in adenoid cystic carcinoma of the breast. This is particularly relevant in the metastatic setting, where treatment options remain limited and are often poorly tolerated. Additionally, given the toxic profile of conventional chemotherapy agents typically applied in the management of triple-negative breast cancer (TNBC) and the low likelihood that this indolent histology subtype would respond to such chemotherapy, alternatives are appealing in scenarios where metastatic adenoid cystic TNBC is detected. Here, we describe such a case and the use of lenvatinib for managing their care.

2. Materials and Methods

We retrospectively reviewed hospital records, imaging studies, treatment plans, and pathology findings, including next-generation sequencing (NGS). Patient consent was obtained for the publication of this case report. Prior to submission for publication, we reviewed PubMed records to examine if similar data had been published on the management of ACCB with lenvatinib or similar agents, but found no such studies or case reports. As part of our manuscript preparations, we followed the 2013 CARE Checklist guidelines for case report development to ensure the utmost completeness and transparency regarding our findings [9].

3. Results

Case Presentation

A 68-year-old woman was referred to the breast clinic after a routine screening mammogram identified a 4 cm subareolar mass in the left breast. Core needle biopsy of the lesion revealed adenoid cystic carcinoma with a tumor grade of 2 and a Ki-67 proliferation index of 15%. Immunohistochemistry demonstrated a triple-negative profile, with 0% expression of estrogen receptor (ER) and progesterone receptor (PR), and HER2-negative status (IHC 0). She subsequently underwent a left mastectomy with sentinel lymph node biopsy, which confirmed stage II disease (pT2 pN0) without nodal involvement. The patient declined adjuvant chemotherapy and elected to proceed with a contralateral prophylactic mastectomy; pathology from the right breast was benign. She was then followed for observation.

Four years later, she presented to the emergency department with new onset dyspnea on exertion, initially suspected to be due to a viral illness. A chest radiograph obtained during this evaluation incidentally revealed two new nodules in the left upper lung. Staging with PET imaging demonstrated metabolic activity within these pulmonary nodules, as well as diffuse skin thickening and uptake in the right breast. Bronchoscopy with fine needle aspiration of the lung lesions confirmed metastatic adenoid cystic carcinoma consistent with a breast primary and with basaloid features. Submitted IHC stains were positive for AE1/3, CK7, and MYB, but negative for TTF-1, p40, INSM1, synaptophysin, GATA3, ER, PR, and HER2. Molecular profiling via next-generation sequencing revealed a PD-L1 combined positive score (CPS) of <1%, a low tumor mutational burden, microsatellite stability, and multiple somatic alterations present, including NOTCH1, CEBPA, and KMT2C mutations.

She underwent two courses of stereotactic body radiation therapy targeting the pulmonary lesions, receiving a cumulative dose of 5000 cGy. Systemic therapy with capecitabine was initiated thereafter but discontinued after two months due to poor tolerance and the development of a pulmonary embolism. She was again managed with surveillance for approximately one year, at which point follow-up chest CT imaging demonstrated progression, with an increase in the size and number of pulmonary nodules as well as new pleural-based lesions. Disease progression was confirmed by biopsy and repeat PET imaging. CEA and CA15-3 tumor markers at that time were noted to be 4.1 and 19.4, respectively.

Clinically, she developed worsening dyspnea and orthopnea, attributed to a recurrent and enlarging pleural effusion. Given symptomatic progression and limited prior treatment tolerance, a trial of lenvatinib was initiated at a dose of 18 mg daily, administered in 28-day cycles. This dose and schedule of lenvatinib was specifically applied based on prior safety data previously studied in the management of refractory thyroid cancer cases as well as based on expert consensus by the head and neck oncology team [10]. Treatment had to be temporarily paused after cycle 7 due to uncontrolled hypertension. Over the course of 13 cycles, the patient experienced notable clinical improvement, including resolution of dyspnea and stabling of the pleural effusion. Follow-up PET imaging has demonstrated a favorable treatment response, with a decrease in the size of known pulmonary nodules and improvement in the pleural effusion and sustained treatment response with no new or progressive lesions present [Figure 1]. Specific improvements of index lesions within the chest included the resolution of a previously measured left apical nodule in the left pleura, shrinkage of the left cardiophrenic nodule from 2.5 × 1.1 cm to 1.4 × 0.6 cm (SUVmax from 8.0 to 4.0), and significant reductions in focal uptake within pleural nodules at the left lung apex (SUVmax from 11.8 to 8.1), left apical medial lung (SUVmax from 11.8 to 8.1), and left posterior lower lobe (SUVmax from 7.1 to 3.6). Additional cross-sectional comparisons are illustrated in Figures 2 and 3. CEA and CA15-3 tumor markers after 13 cycles of treatment were noted to be 3.3 and 19.2, respectively.

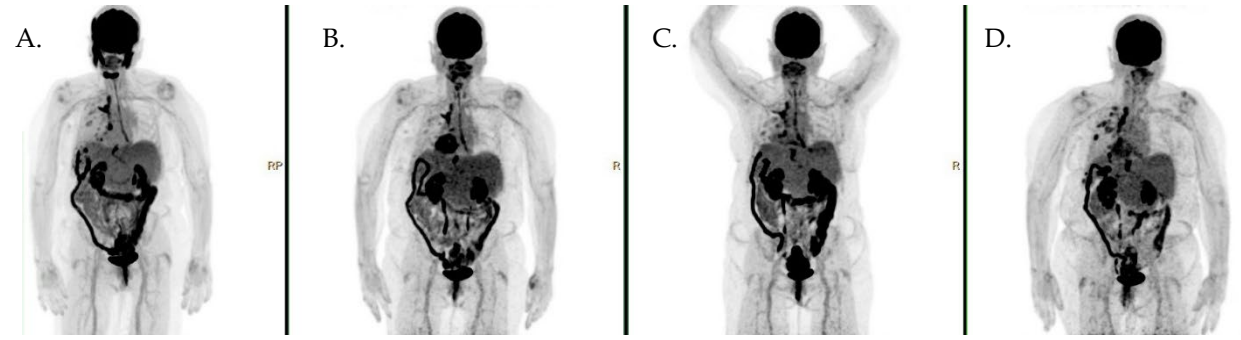

Figure 1. (**A**–**D**) Fluorodeoxyglucose positron emission tomography: (**A**) was completed on 17 April 2026 after 10 cycles of lenvatinib; (**B**) was completed on 13 January 2026 after 7 cycles of lenvatinib; (**C**) was completed on 18 September 2025 after 3 cycles of lenvatinib; (**D**) is baseline from 9 June 2025.

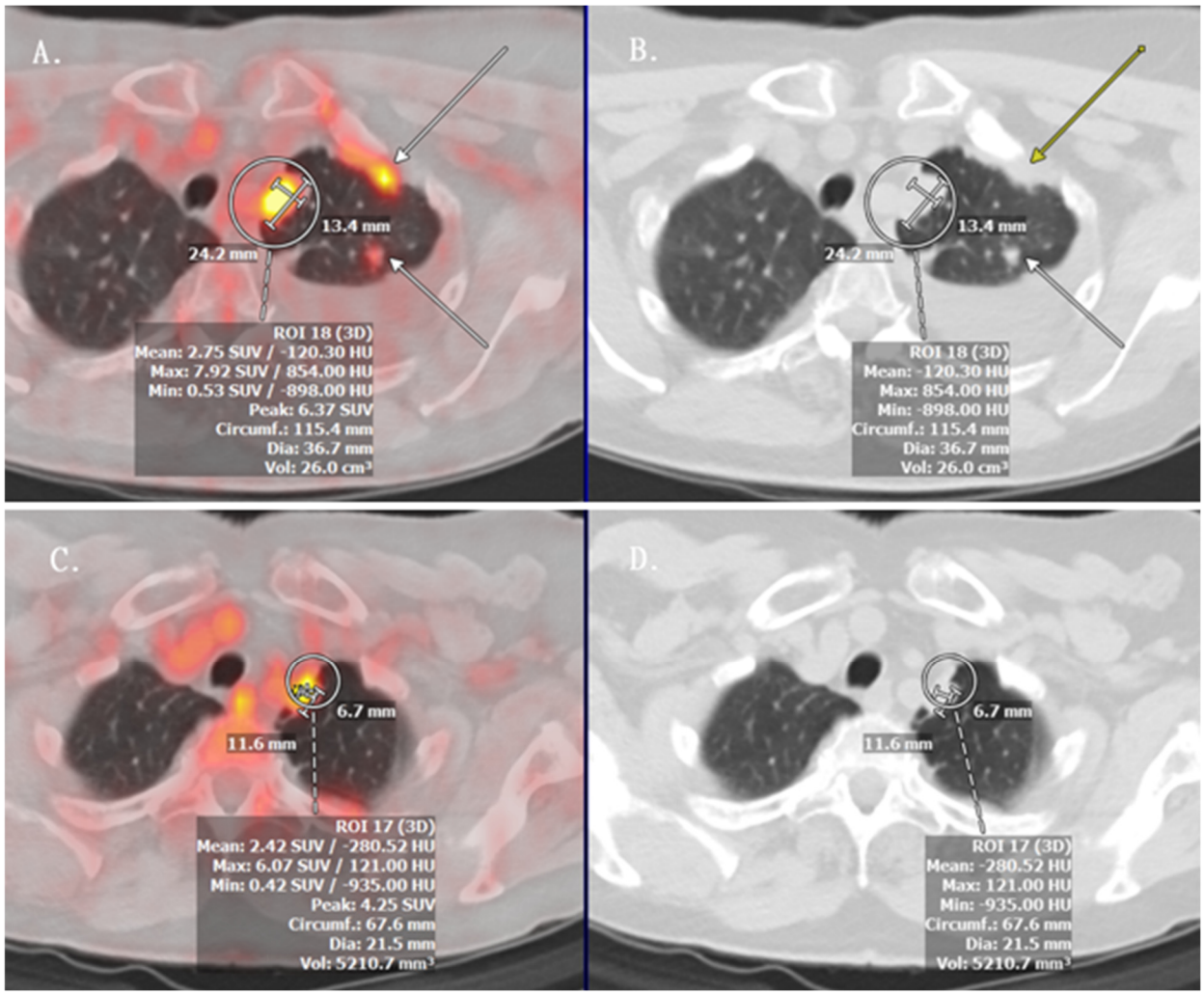

Figure 2. (**A**–**D**) Axial images from fluorodeoxyglucose positron emission tomography scans with size and SUVmax measurements. Images (**A**,**C**) show the fused axial images whereas (**B**,**D**) show the CT images. (**A**,**B**) were completed on 9 June 2025 as the baseline assessment pre-lenvatinib. (**C**,**D**) were performed on 18 September 2025 after 3 cycles of lenvatinib. Arrows are shown on (**A**,**B**) to depict additional target lesions that were monitored.

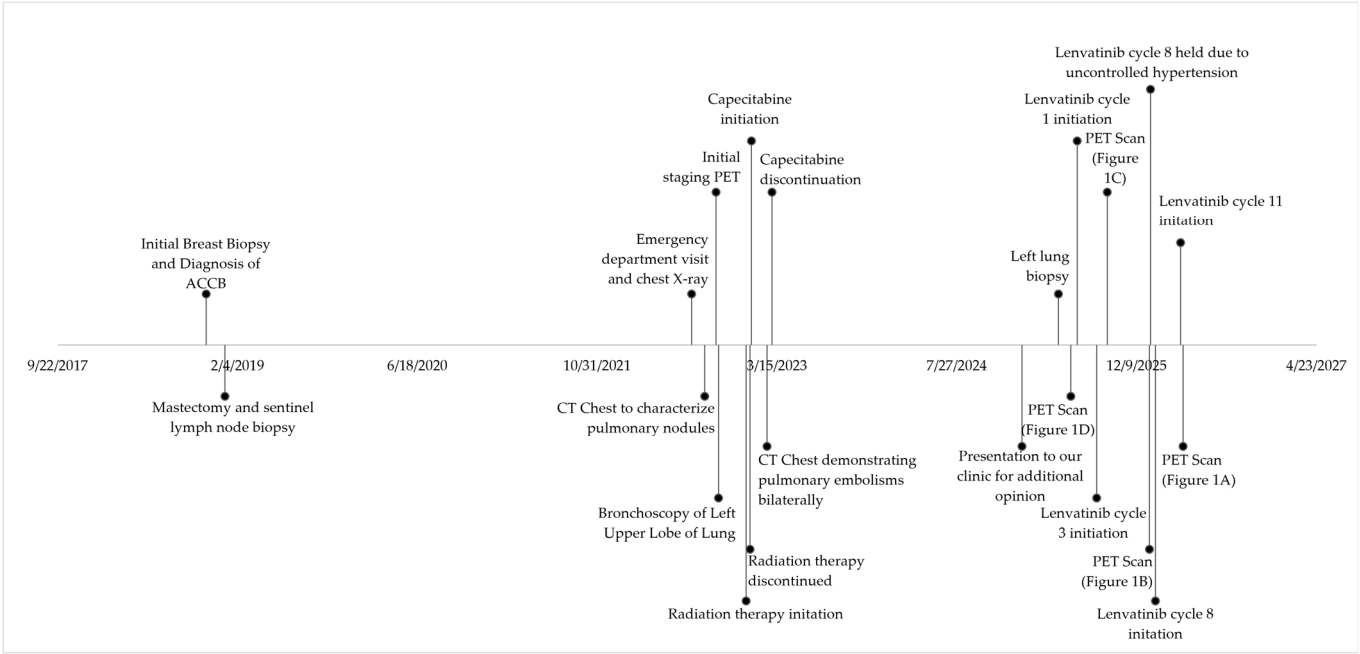

Figure 3. Timeline of events.

4. Discussion

Given the rarity of this malignancy and the absence of well-established systemic treatment guidelines, particularly in the metastatic setting, therapeutic decision-making remains challenging and is often extrapolated from limited data or other tumor types. Systemic reviews of metastatic and recurrent ACC trials have shown efficacy with tyrosine kinase inhibitors such as avatinib [11]. Notably, one phase 2 study investigating the use of lenvatinib for metastatic and recurrent ACC showed an ORR of 15.6%, DCR of 90.6%, and a median progression-free survival of 17.5 months among participants. This mirrors our case closely, where our patient had a clinical response to therapy, with improvement in symptomatology and disease stabilization for a prolonged period of time, including currently at the time of publication.

Importantly, none of the available studies evaluating alternative systemic therapies for ACC have specifically focused on breast-origin disease, and thus the applicability of these findings to ACCB remains uncertain. This case contributes to a limited body of literature and highlights the potential for future prospective research trials.

As discussed earlier, the clinical utility of conventional chemotherapy for the management of ACCB remains low [2–4]. One of the more comprehensive studies examining this question was conducted by Li L et al. in 2022. In their work, a combined SEER and National Cancer Center of China retrospective analysis of BCSS and OS was performed with propensity score-matching utilized to compare outcomes based on chemotherapy receipt, with no difference in OS ($p = 0.455$) or BCSS ($p = 0.148$) identified [4]. That said, the current management of metastatic triple-negative breast cancer, regardless of histologic subtype, now centers around the combination of both conventional chemotherapy and immune checkpoint inhibitors such as pembrolizumab [12]. In the context of our case, our patient had PD-L1 expression <1%, suggesting a lower likelihood of treatment response, but questions remain on how adding pembrolizumab to those with PD-L1 expressing metastatic adenoid cystic TNBC might improve response rates and duration of response. That said, these factors reinforce the limitations of applying standard metastatic TNBC treatments to ACCB and support the consideration of alternative, biologically targeted approaches, such as lenvatinib. Therapies targeting genomic patterns can be a future novel approach.

NOTCH1 is present in about 25% cases of ACC, including our patient, and is associated with more aggressive disease. Phase II trials investigating this approach have shown an ORR of 15% and a DCR of 68% [13].

Despite the encouraging findings in this case, there are several limitations. As a single case report, the observed response to lenvatinib may not be generalizable to other patients with metastatic adenoid cystic TNBC. The duration of follow-up, while over 1 year now, remains limited, and thus the longevity of response remains unclear over multiple years. Additionally, it is uncertain whether similar therapeutic benefit would be observed in metastatic sites that are less accessible to systemic therapies, such as in the central nervous system. Furthermore, while response was documented, this was not captured using RECIST criteria but instead on serial FDG-PET scans, so the accuracy in depicting treatment response within this case report is diminished. Similarly, prior radiation to the left lung 3 years earlier could partially influence the interpretability of specific index lesions, though documented progression of this region was noted while on observation. Finally, this report provides only a snapshot of the patient's molecular profile at a single time point. The incorporation of longitudinal translational analyses, such as circulating tumor DNA (ctDNA) monitoring, tumor biomarker monitoring, or serial NGS, may provide valuable insights into mechanisms of response and resistance over time and represents a direction for future research.

In summary, this case highlights the potential role of lenvatinib as a therapeutic option in metastatic adenoid cystic TNBC, particularly in patients with limited tolerance for conventional chemotherapy and a low likelihood of response to immunotherapy. Given the absence of standardized treatment approaches for this malignancy, further investigation through prospective studies is warranted to better define the efficacy of lenvatinib in this patient population.

5. Conclusions

To our knowledge, there are currently no published reports describing the use of lenvatinib in the management of metastatic adenoid cystic carcinoma of the breast with a triple-negative phenotype. In this context, the clinically meaningful improvement observed in our patient and objective radiographic evidence of disease response suggests that lenvatinib may represent a promising and previously underexplored therapeutic option. While this single case does not establish efficacy, it highlights the potential for lenvatinib to provide both symptomatic relief and disease control in a patient population with otherwise limited options. These findings show the need for further investigation to better define the role of lenvatinib in the treatment of metastatic adenoid cystic triple-negative breast cancer.

Author Contributions: Conceptualization, K.C.C.J.; methodology, K.C.C.J.; validation, K.C.C.J., A.F. and B.H.; formal analysis, K.C.C.J. and B.H.; investigation, K.C.C.J.; data curation, K.C.C.J. and S.G.; writing—original draft preparation, B.H.; writing—review and editing, K.C.C.J., A.F., S.G. and B.H.; visualization, B.H., S.G. and K.C.C.J.; supervision, K.C.C.J.; project administration, K.C.C.J. All authors have read and agreed to the published version of the manuscript.

Funding: This research received no external funding.

Institutional Review Board Statement: Ethical review and approval were waived for this study as this study was a retrospective case report and did not involve the application of experimental agents involving humans or animal subjects.

Informed Consent Statement: Informed consent was obtained from all subjects involved in the study. Written informed consent has been obtained from the patient to publish this paper.

Data Availability Statement: The data presented in this study are available on request from the corresponding author due to patient privacy.

Acknowledgments: We would like to acknowledge Marcelo Bonomi at OSU Medical Oncology for his expertise in the management of rare cancer subtypes.

Conflicts of Interest: The authors declare no conflicts of interest. The funders had no role in the design of the study; in the collection, analyses, or interpretation of data; in the writing of the manuscript; or in the decision to publish the results.

Abbreviations

The following abbreviations are used in this manuscript:

ACCB	Adenoid cystic carcinoma of the breast
TNBC	Triple-negative breast cancer
NGS	Next-Generation Sequencing
ACC	Adenoid cystic carcinoma
ORR	Objective response rate
DCR	Disease control rate
ER	Estrogen receptor
PR	Progesterone receptor
ctDNA	Circulating tumor DNA

References

1. Li, N.; Xu, L.; Zhao, H.; El-Naggar, A.K.; Sturgis, E.M. A comparison of the demographics, clinical features, and survival of patients with adenoid cystic carcinoma of major and minor salivary glands versus less common sites within the Surveillance, Epidemiology, and End Results registry. *Cancer* **2012**, *118*, 3945–3953. [CrossRef] [PubMed]
2. Schulz-Costello, K.; Fan, F.; Schmolze, D.; Arias-Stella, J.A., 3rd; Taylor, L.; Tseng, J.; Afkhami, M.; Rand, J.G.; Jones, V.; Farmah, P.; et al. Solid basaloid adenoid cystic carcinoma of the breast: A high-grade triple negative breast carcinoma which rarely responds to neoadjuvant chemotherapy. *Hum. Pathol.* **2025**, *157*, 105760. [CrossRef] [PubMed]
3. Kim, S.; Sheth, K.; Yu, X.; Porterfield, L.; Vaughan, E.M. Clinical course and treatment outcomes in solid-basaloid adenoid cystic carcinoma of the breast: A systematic review and case report. *Cancer Treat. Rev.* **2025**, *141*, 103028. [CrossRef] [PubMed]
4. Li, L.; Zhang, D.; Ma, F. Adenoid Cystic Carcinoma of the Breast May Be Exempt from Adjuvant Chemotherapy. *J. Clin. Med.* **2022**, *11*, 4477. [CrossRef] [PubMed] [PubMed Central]
5. Gupta, A.K.; Wilke, W.W.; Taylor, E.N.; Bodeker, K.L.; Hoffman, H.T.; Milhem, M.M.; Buatti, J.M.; Robinson, R.A. Signaling pathways in adenoid cystic cancers: Implications for treatment. *Cancer Biol. Ther.* **2009**, *8*, 1947–1951. [CrossRef] [PubMed]
6. Tchekmedyian, V.; Sherman, E.J.; Dunn, L.; Tran, C.; Baxi, S.S.; Katabi, N.; Antonescu, C.R.; Ostrovnaya, I.; Maidul Haque, S.; Pfister, D.G.; et al. Phase II Study of Lenvatinib in Patients With Progressive, Recurrent or Metastatic Adenoid Cystic Carcinoma. *J. Clin. Oncol.* **2014**, *37*, 1529–1537. [CrossRef] [PubMed]
7. Schlumberger, M.; Tahara, M.; Wirth, L.J.; Robinson, B.; Brose, M.S.; Elisei, R.; Habra, M.A.; Newbold, K.; Shah, M.H.; Hoff, A.O.; et al. Lenvatinib versus Placebo in Radioiodine-Refractory Thyroid Cancer. *N. Engl. J. Med.* **2015**, *372*, 621–630. [CrossRef] [PubMed]
8. Ho, A.L.; Dunn, L.; Sherman, E.J.; Fury, M.G.; Baxi, S.S.; Chandramohan, R.; Dogan, S.; Morris, L.G.; Cullen, G.D.; Haque, S.; et al. A phase II study of axitinib (AG-013736) in patients with incurable adenoid cystic carcinoma. *Ann. Oncol.* **2016**, *27*, 1902–1908. [CrossRef] [PubMed]
9. Gagnier, J.J.; Kienle, G.; Altman, D.G.; Moher, D.; Sox, H.; Riley, D. The CARE Guidelines: Consensus-based Clinical Case Reporting Guideline Development. *Glob. Adv. Health Med.* **2013**, *2*, 38–43. [CrossRef] [PubMed]
10. Hayato, S.; Shumaker, R.; Ferry, J.; Binder, T.; Dutcus, C.E.; Hussein, Z. Exposure-response analysis and simulation of lenvatinib safety and efficacy in patients with radioiodine-refractory differentiated thyroid cancer. *Cancer Chemother. Pharmacol.* **2018**, *82*, 971–978. [CrossRef] [PubMed] [PubMed Central]
11. Zhou, J.; Zhao, G.; Wang, S.; Li, N. Systemic therapy in the management of metastatic or locally recurrent adenoid cystic carcinoma of the salivary glands: A systematic review of the last decade. *Br. J. Cancer* **2024**, *131*, 1021–1031. [CrossRef] [PubMed]

12. Cortes, J.; Cescon, D.W.; Rugo, H.S.; Nowecki, Z.; Im, S.-A.; Yusof, M.M.; Gallardo, C.; Lipatov, O.; Barrios, C.H.; Holgado, E.; et al. Pembrolizumab plus chemotherapy versus placebo plus chemotherapy for previously untreated locally recurrent inoperable or metastatic triple-negative breast cancer (KEYNOTE-355): A randomised, placebo-controlled, double-blind, phase 3 clinical trial. *Lancet* **2020**, *396*, 1817–1828. [CrossRef] [PubMed]
13. de Sousa, L.G.; Jovanovic, K.; Ferrarotto, R. Metastatic Adenoid Cystic Carcinoma: Genomic Landscape and Emerging Treatments. *Curr. Treat. Options Oncol.* **2022**, *23*, 1135–1150. [CrossRef] [PubMed]

Disclaimer/Publisher's Note: The statements, opinions and data contained in all publications are solely those of the individual author(s) and contributor(s) and not of MDPI and/or the editor(s). MDPI and/or the editor(s) disclaim responsibility for any injury to people or property resulting from any ideas, methods, instructions or products referred to in the content.