Curr Oncol, Vol. 21, pp. e340-344; doi: http://dx.doi.org/10.3747/co.21.1756

CASE REPORT



Metabolic syndrome–related hepatocellular carcinoma treated by volumetric modulated arc therapy

J. Klein MD, L.A. Dawson MD,* T.H. Tran MRT,* O. Adeyi MD,† T. Purdie PhD,* M. Sherman MB BCh PhD,‡ and A. Brade MDCM PhD**

ABSTRACT

Hepatocellular carcinoma (HCC) is a leading cause of cancer mortality, and its incidence is increasing in developed countries. Risk factors include cirrhosis from viral hepatitis or alcohol abuse. Metabolic syndrome is a newly recognized, but important, risk factor that is likely contributing to the increased incidence of HCC.

Surgery is the therapy of choice for HCC, but local therapies are often contraindicated, usually because of advanced disease or comorbid conditions such as cardiac disease (which is associated with metabolic syndrome). Current radiation therapy techniques such as stereotactic body radiotherapy allow for treatment plans that highly conform to the target and provide excellent sparing of normal structures. Radiation therapy is emerging as a viable option in patients not eligible for surgery or other locoregional therapies.

Here, we report a case of a large HCC presenting in a patient with metabolic syndrome without significant alcohol history or biochemical liver dysfunction. The patient was not a candidate for locoregional therapies because of cardiac and renal comorbidities typical of patients experiencing the long-term sequelae of metabolic syndrome. Treatment using an arc-based volumetric-modulated arc therapy technique allowed for the highest dose of radiation to be delivered to the tumour while the peripheral radiation dose was minimized. A complete local response was confirmed by computed tomography imaging 21 months after treatment completion.

KEY WORDS

Hepatocellular carcinoma, liver cancer, metabolic syndrome, radiotherapy, SBRT, VMAT, IMRT

1. INTRODUCTION

Cirrhosis, mostly caused by hepatitis C or alcohol intake, is the predominant risk factor for hepatocellular carcinoma (HCC) in North America[1]; however, many cases have no obvious underlying cause[2]. Metabolic syndrome (MBS), a clinical syndrome related to obesity and insulin resistance, might cause HCC through the development of fatty liver disease[2,3]. Metabolic syndrome is also associated with increased cardiac disease[4]. The growing incidence of MBS suggests that the incidence of HCC in developed countries will continue to rise, increasing the demand for effective therapies in HCC[3].

Radiation therapy (RT) was historically dismissed for the treatment of HCC because of the difficulty in targeting the radiation dose to the tumour while sparing the relatively radiosensitive normal liver. However, potentially curative modalities such as surgical resection, liver transplantation, radiofrequency ablation, and transarterial chemoembolization are often limited by advanced disease or comorbidities such as those associated with MBS[1]. Systemic treatments are toxic, with poor response rates[5], although sorafenib is being combined with RT in the phase III Radiotherapy Oncology Group 1112 study after improved survival was observed in two randomized trials[6,7].

Stereotactic body radiotherapy (SBRT) is a technique that uses few fractions—usually 10 or fewer—to deliver high doses of highly conformal RT, minimizing dose to normal structures[8]. Stereotactic body radiotherapy has proved effective for HCC and is a good option for patients ineligible for other treatments.

2. CASE DESCRIPTION

A 75-year-old man with a body mass index (BMI) of 62.8 presented after non-contrast computed tomography (CT) imaging demonstrated a growing liver mass initially diagnosed as an adenoma. Medical history was significant for congestive heart failure, type 2 diabetes mellitus (DM) requiring insulin, sleep apnea, Parkinson disease, and chronic kidney disease (creatinine: 138 μmol/L; creatinine clearance: 44 mL/min/1.73 m^2). Metabolic syndrome was diagnosed based on his 65-inch waist circumference and

Copyright © 2014 Multimed Inc. Following publication in *Current Oncology*, the full text of each article is available immediately and archived in PubMed Central (PMC).

treatment for DM and hypertension[4]. He was referred to radiation oncology because cardiac and renal comorbidities precluded focal therapies, including surgery and transarterial chemoembolization.

Blood tests revealed Child–Pugh class A5 liver function, normal platelets (186.0×10^9/L), elevated serum alpha-fetoprotein (277 μg/L), and negative serology for hepatitis B and C. Computed tomography–guided biopsy diagnosed a well-differentiated HCC with marked steatosis (Figure 1). Triphasic CT demonstrated lobar redistribution consistent with cirrhosis. A 10.8-cm steatotic lesion was well visualized without contrast in liver segments 6 and 7, extending into segments 5 and 8 [Figure 2(A)].

Clinically, the patient had no complaints. Physical exam revealed a bilateral tremor, but no ascites, asterixis, hepatosplenomegaly, or jaundice. He denied alcohol consumption.

Initially, an SBRT plan was developed to deliver 39 Gy in 6 fractions using 8-beam intensity-modulated radiation therapy (IMRT). A 3-arc volumetric-modulated arc therapy (VMAT) plan permitted dose escalation to 45 Gy. The patient experienced only mild fatigue and dyspepsia during treatment.

Daily cone-beam CT with positioning adjustments to match bone and soft-tissue landmarks to the planning CT allowed for accurate tumour localization[9]. Because of orthopnea, we used an abdominal compression apparatus[10] (rather than our standard active breath-hold protocol) to manage intra-fraction breathing motion.

Follow-up imaging documented an excellent local tumour response. The tumour was not seen on the most recent non-contrast CT taken 21 months after treatment [Figure 2(B)]. Liver enzymes, international normalized ratio, partial thromboplastin time, and bilirubin levels remained normal. Alpha-fetoprotein was 36 μg/L.

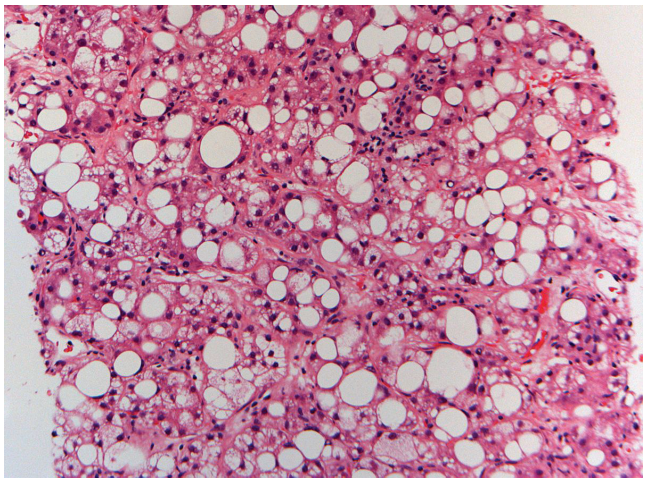

FIGURE 1 *Tissue sample from a computed tomography–guided biopsy (100× original magnification).*

3. DISCUSSION

3.1 Metabolic Syndrome As a Risk Factor for HCC

The incidence of HCC is rising in developed countries, having increased to 3.3 cases from 1.3 cases per 100,000 in the United States between 1978 and 2001[2]. Of HCC cases, 30%–40% arise in the setting of "cryptogenic cirrhosis," lacking established risk factors such as alcohol intake or hepatitis B or C infection[2]. Nonalcoholic fatty liver disease and nonalcoholic steatohepatitis (NASH), the liver manifestations of MBS, are the leading cause of chronic liver disease in the United States and might represent the cause of cryptogenic cirrhosis[11].

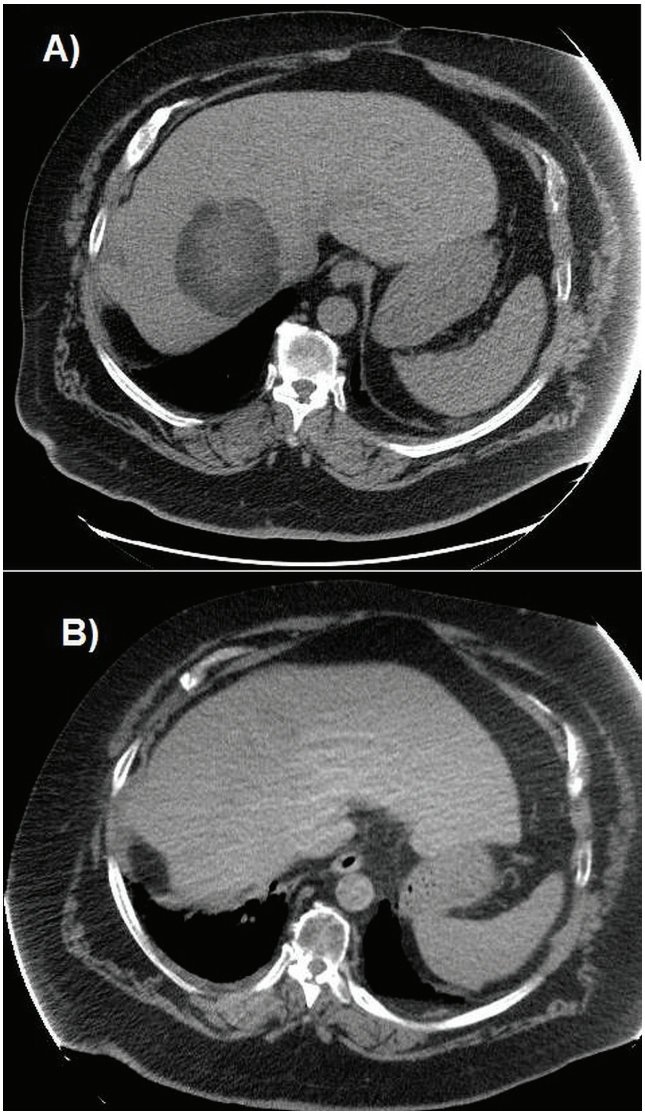

FIGURE 2 *Transverse slices from noncontrast diagnostic computed tomography (CT) images. (A) Pre-treatment planning CT image: The tumour is very easily seen despite lack of contrast. (B) CT image, 21 months after treatment; the tumour is no longer clearly visible.*

Copyright © 2014 Multimed Inc. Following publication in *Current Oncology*, the full text of each article is available immediately and archived in PubMed Central (PMC).

Most patients with nonalcoholic fatty liver disease will not develop advanced liver disease. The risk of developing NASH cirrhosis is variable, but has been estimated at 11% over 15 years. However, risk factors such as obesity and DM seem to increase that risk. Patients who develop cirrhosis have an approximately 7% risk of developing HCC over 6.5 years, with individual studies estimating risk to be between 2.4% and 12.8% over 3–10 years[12].

Compared with NASH cirrhosis, cirrhosis from hepatitis confers a 58%–172% increased risk of developing HCC[11]. However, the increasing prevalence of MBS (and subsequent nonalcoholic fatty liver disease) is likely contributing to an increasing incidence of HCC in developed countries that is expected to continue[3]. The average age of HCC diagnosis has been trending downward, and the increase in childhood obesity could exacerbate that trend[2].

Analysis of the U.S. Surveillance, Epidemiology, and End Results–Medicare database demonstrated an odds ratio of 2.13 for HCC in patients with MBS compared with matched control subjects[13]. A case–control study suggested that patients with 2 or more components of MBS experience a quadrupling of HCC risk[14].

Individual components of MBS are also potentially HCC risk factors. A systematic review estimated that DM increases the risk for HCC by a factor of between 2 and 4[15]. A meta-analysis of eleven studies demonstrated increased hazard ratios (HRS) for HCC among patients classified as overweight (BMI: 25–29.9; HR: 1.07) or obese (BMI: ≥30; HR: 1.85)[16]. A large prospective cohort study ($n > 900{,}000$) reported a liver cancer risk that was increased by a factor of 4.5 in patients with a BMI of 35–40 compared with patients having a BMI of 18.5–24.9[17].

Steatohepatitic HCC is a recently described variant estimated to represent 13.5% of HCC cases; it is predominantly associated with NASH cirrhosis. Figure 3 compares the histopathologic appearance of steatohepatitic HCC with that of conventional HCC[18].

Hepatitis-related HCC and MBS-related HCC might represent distinct clinical entities because the latter can develop without significant liver fibrosis or cirrhosis. Cullin7, found on the p-arm of chromosome 6, might represent a genetic marker for MBS-related HCC[19]. Future research will clarify the mechanisms associating MBS and HCC.

3.2 Radiation Therapy for HCC

The increasing incidence of NASH-related HCC will boost demand for treatments suitable for patients with significant comorbidities. Prospective studies of SBRT for HCC have demonstrated 1- and 2-year survivals of 75% and 67% respectively[20,21]. Patients with portal venous thrombosis have a poorer prognosis, with median survival reported to be between 5.3 and 13.1 months[22,23].

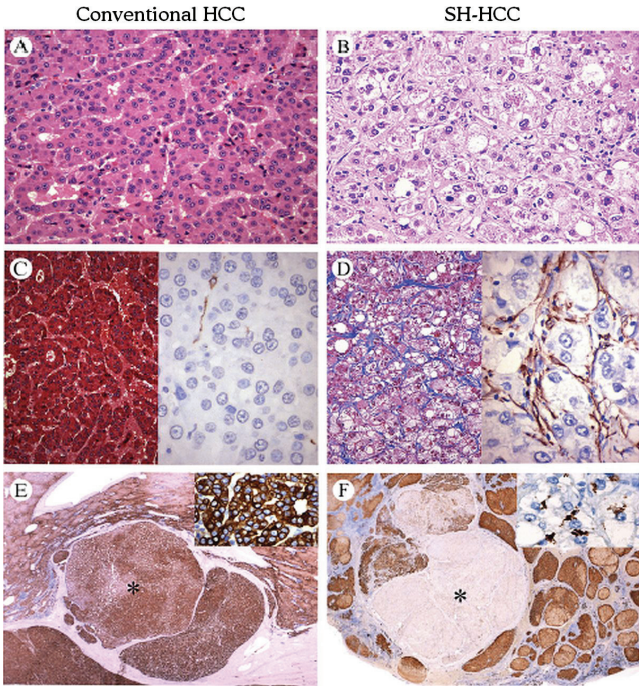

FIGURE 3 Histologic comparison between (A,C,E) conventional hepatocellular carcinoma (HCC) and (B,D,F) steatohepatitic (SH) HCC. (A) Conventional HCC cells show abundant eosinophilic cytoplasm with few inflammatory cells, little or no fibrosis, and (C) only sparse activated hepatic stellate cells. (E) Expression of cytoplasmic cytokeratin 8/18 is strong and diffuse. (B) In contrast, SH-HCC demonstrates cellular ballooning, Mallory–Denk bodies (MDBS), and inflammation, with prominent pericellular or septal fibrosis, and (D) a large number of activated stellate cells. (F) Staining for cytokeratin 8/18 highlights MDBS (magnified image, right upper corner). Reprinted from Salomao et al.*, 2012[18], with permission from Elsevier.*

The IMRT and VMAT technologies can both deliver characteristic high-dose conformal SBRT treatment, with a rapid fall-off in dose to the surrounding tissues. By exploiting 360-degree gantry rotation, VMAT can offer superior conformality, delivering RT across a continuous range of beam angles rather than a series of discrete angles, as with IMRT. However, VMAT requires additional planning expertise to implement[24].

Our institution's SBRT protocol prescribes individualized doses in 6 fractions over 2 weeks, based on the fraction of the whole liver being irradiated (V_{eff}). Safety has been established, with a median survival of 17 months in 102 patients, 55% of whom had portal venous thrombosis[25].

Figure 4 compares RT plans developed using IMRT and VMAT. Based on our protocol, doses of 39 Gy ($V_{\text{eff}} = 0.35$) and 45 Gy ($V_{\text{eff}} = 0.29$) were prescribed, respectively delivering maximum radiation doses of 5009 cGy and 5949 cGy to the tumour.

The present case represents our first application of VMAT for liver SBRT. Based on advantageous dosimetry and improved treatment delivery times, VMAT is now our centre's standard SBRT technique for HCC.

Copyright © 2014 Multimed Inc. Following publication in *Current Oncology*, the full text of each article is available immediately and archived in PubMed Central (PMC).

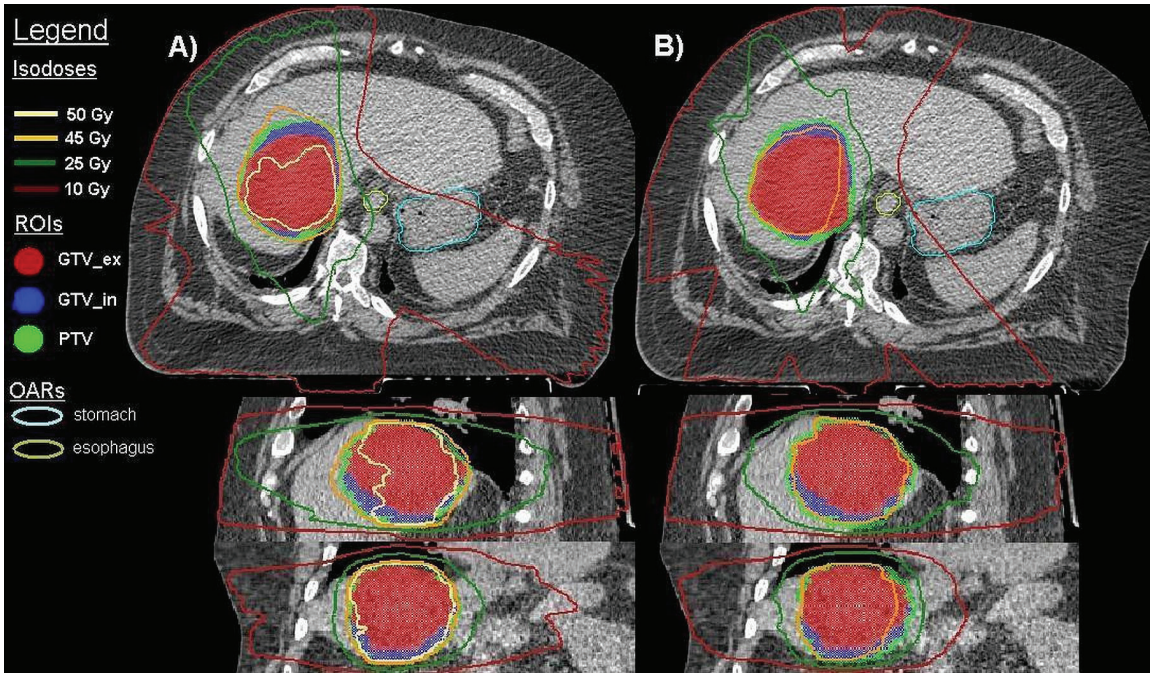

FIGURE 4 Two radiotherapy plans developed for treating hepatocellular carcinoma (HCC) in the reported patient. Axial (top), sagittal (middle), and coronal (bottom) slices from the helical radiotherapy simulation computed tomography images are shown. (A) Plan using volumetric modulated arc therapy (VMAT), which was eventually used to deliver the treatment. Note that much of the target volume receives more than 50 Gy. The effective volume of treated liver (V_{eff} = 0.29) corresponds to a prescription dose of 45 Gy (based on our centre's protocol). The maximum dose delivered to the tumour was 5949 cGy. (B) Plan using step-and-shoot intensity-modulated radiation therapy (IMRT), which was not used for treatment. Note that none of the target volume receives more than 50 Gy and that, compared with the VMAT plan, the IMRT plan encompasses more of the non-diseased liver within the 25 Gy and 10 Gy isodose lines. The 0.35 V_{eff} corresponds to a prescription dose of 39 Gy (based on our centre's protocol). The maximum dose delivered to the tumour was 5009 cGy. ROIs = regions of interest; GTV _ex = gross tumour volume during exhalation; GTV _in = gross tumour volume during inhalation; PTV = planning target volume; OARs = organs at risk.

4. CONCLUSIONS

Metabolic syndrome increases HCC risk and likely represents the cause of this patient's disease. An increasing incidence of MBS will likely contribute to an increasing HCC incidence and demand for HCC therapies. Metabolic syndrome is associated with cardiac comorbidity that can reduce the utility of local modalities such as surgery or transarterial chemoembolization in this patient population. Stereotactic body radiotherapy is effective for HCC and should be considered in patients ineligible for other treatment modalities.

5. ACKNOWLEDGMENTS

We sincerely thank the patient for allowing us to discuss his case.

6. CONFLICT OF INTEREST DISCLOSURES

LAD has received research grants from Bayer. The remaining authors have no financial conflicts of interest to declare.

7. REFERENCES

1. Llovet JM, Burroughs A, Bruix J. Hepatocellular carcinoma. *Lancet* 2003;362:1907–17.
2. El-Serag HB, Rudolph KL. Hepatocellular carcinoma: epidemiology and molecular carcinogenesis. *Gastroenterology* 2007;132:2557–76.
3. Stickel F, Hellerbrand C. Non-alcoholic fatty liver disease as a risk factor for hepatocellular carcinoma: mechanisms and implications. *Gut* 2010;59:1303–7.
4. Grundy SM, Cleeman JI, Daniels SR, *et al.* on behalf of the American Heart Association; National Heart, Lung, and Blood Institute. Diagnosis and management of the metabolic syndrome: an American Heart Association/National Heart, Lung, and Blood Institute Scientific Statement. *Circulation* 2005;112:2735–52. [Erratum in: *Circulation* 2005;112:e297–8]
5. Valle JW, Dangoor A, Beech J, *et al.* Treatment of inoperable hepatocellular carcinoma with pegylated liposomal doxorubicin (PLD): results of a phase II study. *Br J Cancer* 2005;92:628–30.
6. Llovet JM, Ricci S, Mazzaferro V, *et al.* Sorafenib in advanced hepatocellular carcinoma. *N Engl J Med* 2008;359:378–90.
7. Cheng AL, Kang YK, Chen Z, *et al.* Efficacy and safety of sorafenib in patients in the Asia–Pacific region with advanced

Copyright © 2014 Multimed Inc. Following publication in *Current Oncology*, the full text of each article is available immediately and archived in PubMed Central (PMC).

hepatocellular carcinoma: a phase III randomised, double-blind, placebo-controlled trial. *Lancet Oncol* 2009;10:25–34.
8. Bujold A, Massey CA, Kim JJ, *et al.* Sequential phase I and II trials of stereotactic body radiotherapy for locally advanced hepatocellular carcinoma. *J Clin Oncol* 2013;31:1631–9.
9. Letourneau D, Wong JW, Oldham M, *et al.* Cone-beam–CT guided radiation therapy: technical implementation. *Radiother Oncol* 2005;75:279–86.
10. Eccles CL, Patel R, Simeonov AK, Lockwood G, Haider M, Dawson LA. Comparison of liver tumor motion with and without abdominal compression using cine-magnetic resonance imaging. *Int J Radiat Oncol Biol Phys* 2011;79:602–8.
11. White DL, Kanwal F, El-Serag HB. Association between nonalcoholic fatty liver disease and risk for hepatocellular cancer, based on systematic review. *Clin Gastroenterol Hepatol* 2012;10:1342–59.e2.
12. Torres DM, Williams CD, Harrison SA. Features, diagnosis, and treatment of nonalcoholic fatty liver disease. *Clin Gastroenterol Hepatol* 2012;10:837–58.
13. Welzel TM, Graubard BI, Zeuzem S, El-Serag HB, Davila JA, McGlynn KA. Metabolic syndrome increases the risk of primary liver cancer in the United States: a study in the SEER–Medicare database. *Hepatology* 2011;54:463–71.
14. Turati F, Talamini R, Pelucchi C, *et al.* Metabolic syndrome and hepatocellular carcinoma risk. *Br J Cancer* 2013;108:222–8.
15. El-Serag HB, Hampel H, Javadi F. The association between diabetes and hepatocellular carcinoma: a systematic review of epidemiologic evidence. *Clin Gastroenterol Hepatol* 2006;4:369–80.
16. Larsson SC, Wolk A. Overweight, obesity and risk of liver cancer: a meta-analysis of cohort studies. *Br J Cancer* 2007;97:1005–8.
17. Calle EE, Rodriguez C, Walker–Thurmond K, Thun MJ. Overweight, obesity, and mortality from cancer in a prospectively studied cohort of U.S. adults. *N Engl J Med* 2003;348:1625–38.
18. Salomao M, Remotti H, Vaughan R, Siegel AB, Lefkowitch JH, Moreira RK. The steatohepatitic variant of hepatocellular carcinoma and its association with underlying steatohepatitis. *Hum Pathol* 2012;43:737–46.
19. Paradis V, Albuquerque M, Mebarki M, *et al.* Cullin7: a new gene involved in liver carcinogenesis related to metabolic syndrome. *Gut* 2013;62:911–19.
20. Andolino DL, Johnson CS, Maluccio M, *et al.* Stereotactic body radiotherapy for primary hepatocellular carcinoma. *Int J Radiat Oncol Biol Phys* 2011;81:e447–53.
21. Cardenes HR, Price TR, Perkins SM, *et al.* Phase I feasibility trial of stereotactic body radiation therapy for primary hepatocellular carcinoma. *Clin Transl Oncol* 2010;12:218–25.
22. Ishikura S, Ogino T, Furuse J, *et al.* Radiotherapy after transcatheter arterial chemoembolization for patients with hepatocellular carcinoma and portal vein tumor thrombus. *Am J Clin Oncol* 2002;25:189–93.
23. Han KH, Seong J, Kim JK, Ahn SH, Lee do Y, Chon CY. Pilot clinical trial of localized concurrent chemoradiation therapy for locally advanced hepatocellular carcinoma with portal vein thrombosis. *Cancer* 2008;113:995–1003.
24. Palma D, Vollans E, James K, *et al.* Volumetric modulated arc therapy for delivery of prostate radiotherapy: comparison with intensity-modulated radiotherapy and three-dimensional conformal radiotherapy. *Int J Radiat Oncol Biol Phys* 2008;72:996–1001.
25. Bujold A, Massey CA, Kim JJ, *et al.* Sequential phase I and II trials of stereotactic body radiotherapy for locally advanced hepatocellular carcinoma. *J Clin Oncol* 2013;31:1631–9.

Correspondence to: Anthony Brade, c/o Radiation Medicine Program, University Health Network, Princess Margaret Hospital, Suite 5-912, 610 University Avenue, Toronto, Ontario M5G 2M9.
E-mail: anthony.brade@rmp.uhn.on.ca

* Department of Radiation Oncology, University of Toronto, Princess Margaret Hospital, Toronto, ON.
† Department of Laboratory Medicine and Pathobiology, University of Toronto, Toronto General Hospital, Toronto, ON.
‡ Department of Medicine, University of Toronto, University Health Network, Toronto, ON.

Copyright © 2014 Multimed Inc. Following publication in *Current Oncology*, the full text of each article is available immediately and archived in PubMed Central (PMC).