A patient with multiple spontaneous arterial dissections

Dissected woman

Mattia Cattaneo[a*], Daniel Sürder[b], Rolf Wyttenbach[c], Mario Alerci[c], Pierluigi Pedrazzi[d], Marcel Arnold[e], Augusto Gallino[a]

[a] Department of Cardiology, Ospedale Regionale di Bellinzona e Valli – San Giovanni, Bellinzona, Switzerland; [b] Department of Cardiology, Fondazione Cardiocentro Ticino, Lugano, Switzerland; [c] Department of Radiology, Ospedale Regionale di Bellinzona e Valli – San Giovanni, Bellinzona, Switzerland; [d] Department of Neurology, Neurocentre of Southern Switzerland, Lugano, Switzerland; [e] Department of Neurology, Inselspital Universitätsspital Bern, Switzerland

Summary

A 45-year-old woman was admitted to our stroke unit because of acute focal neurological symptoms. A spontaneous left internal carotid artery dissection was later diagnosed. In the following 14 days the patient was affected by ST-segment elevation acute myocardial infarction due to distal posterior descending artery (PD) occlusion and acute right back pain due to spontaneous right renal artery dissection. A 6-month follow-up showed complete spontaneous recanalisation of the affected arteries, with the exception of the distal PD. Despite its exceptionality, this case underscores the need for comprehensive vascular evaluation in young and middle-aged patients presenting with spontaneous cervical artery dissection and clinical symptoms suggesting other organ involvement.

Key words: spontaneous arterial dissection; stroke; acute coronary syndrome; vascular imaging

Case report

A 45-year-old woman was admitted to our stroke unit because of acute right hemiparesis, aphasia and moderate frontal headache while running on a treadmill. She had no cardiovascular risk factors apart from previous smoking. Furthermore, no recent infections, blunt neck trauma, medical or surgical procedures or risk factors for bleeding were identified. Brain multidetector computed tomography (MDCT) showed neither acute ischaemic nor haemorrhagic lesions, while MDCT angiography and magnetic resonance imaging angiography (MRA) revealed a 1-cm long subocclusive dissection of the left internal carotid artery (LICA) at the level of the cervical-petrous segment junction (figs 1A–B). Aortic MDCT angiography excluded the presence of Stanford type A aortic dissection. Treatment with aspirin and neurological follow-up were implemented for the LICA spontaneous dissection [1].

Ten days later the patient was admitted because of acute chest pain at rest later diagnosed as ST-segment elevation acute myocardial infarction. Primary selective angiography of the right coronary artery, via the radial approach, disclosed distal posterior descending artery (PD) occlusion (fig. 1C; online-only Data Supplement Video 1). The lesion was carefully crossed with a guidewire, revealing a subocclusive stenosis along the entire distal PD (fig. 1D; online-only Data Supplement Video 2). On the basis of the characteristics of the lesion and the absence of any additional coronary atheromatosis, the diagnosis of spontaneous coronary artery dissection was retained [2]. Due to the small diameter of the vessel lumen, no intravascular imaging was performed and a conservative approach was chosen.

Four days later, the patient reported acute right back pain. Abdominal aorta MDCT angiography revealed spontaneous right renal artery dissection. It was confirmed by nonselective renal artery angiography, which also suggested fibromuscular dysplasia (FMD) because of the presence of a possible "string of beads" lesion, but only in a side branch of the renal artery (fig. 1E). A conservative approach was preferred [2, 3]. Since the arterial lesion was not pathognomonic for FMD, genetic testing for vascular Ehlers-Danlos syndrome (*COL3A1* mutation) was also performed, but the results were negative.

The patient underwent cautious cardiac rehabilitation, avoiding strong isometric efforts, and implemented measures for secondary prevention of cardiovascular disease. A 6-month follow-up encompassed cardiovascular imaging such as carotid and cerebral MRA, as well as cardiac and abdominal MDCT angiography. This showed complete spontaneous recanalisation of the affected arteries, with the exception of the distal PD. This is a rare case of three consecutive spontaneous arterial dissections affecting three different vascular beds and occurring within only 14 days. Despite its exceptionality, this case underscores the need for comprehensive vascular evaluation and the usefulness of multiple imaging modalities in young and middle-aged patients presenting with spontaneous cervical artery dissection and clinical symptoms suggesting other organ involvement.

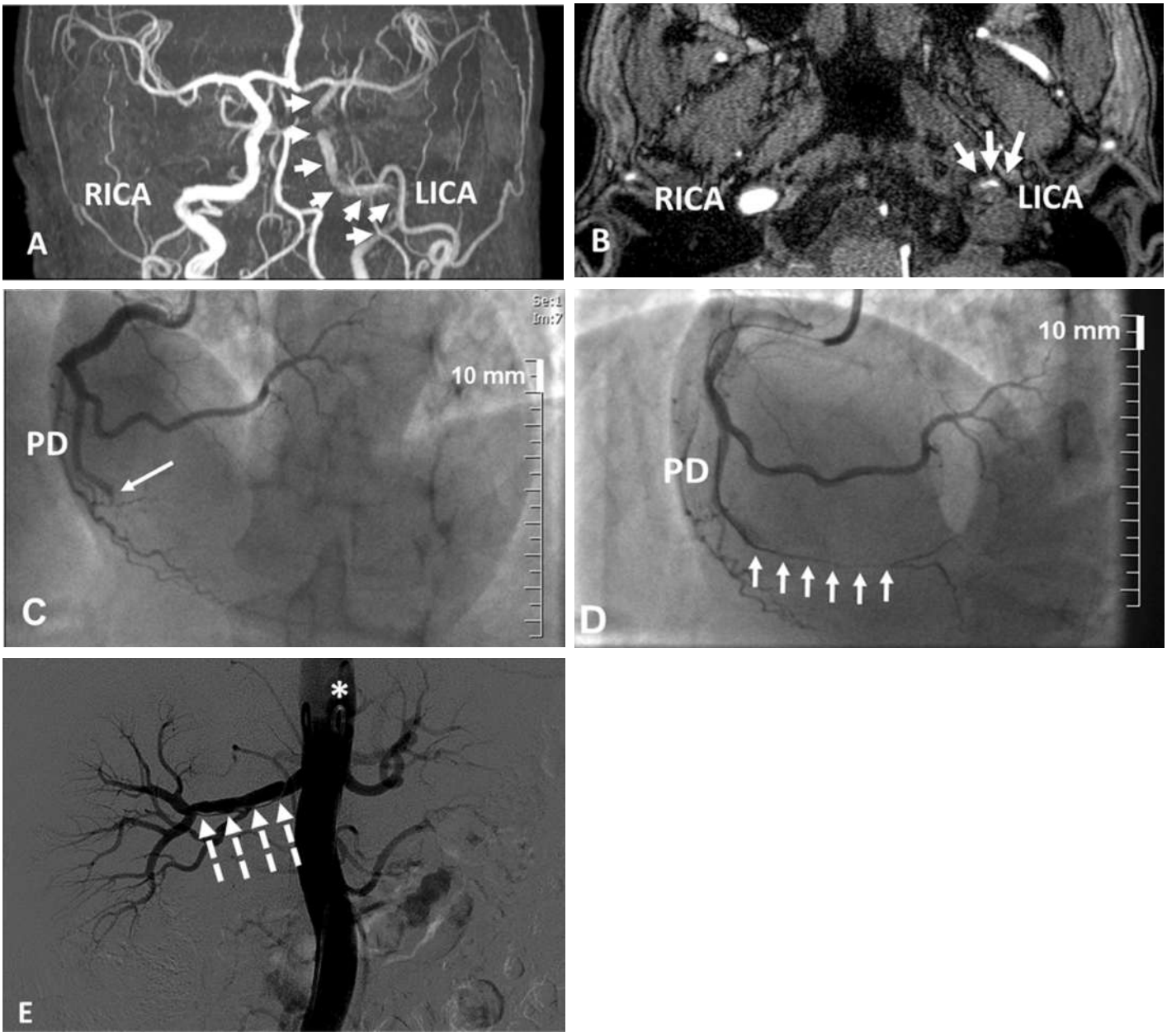

Figure 1: (A–B) Magnetic resonance (MR) angiography displaying subocclusive dissection of the left internal carotid artery. (A) Frontal plane reconstructed MR angiography of the dissected LICA: hypoperfusion is evident distally to the dissection (arrows). (B) Coronal plane MR angiography of the dissected LICA (dotted arrows) showing the almost occluded true lumen of the LICA (dotted arrows). LICA = left internal carotid artery; RICA = right internal carotid artery

(C–D) Selective coronary angiography of the right coronary artery disclosing possible posterior descending artery dissection. (C) Diagnostic injection demonstrating complete distal PD occlusion (big arrow). (See online-only Data Supplement Video 1.) (D) Severe and diffuse lumen narrowing (arrows) of the entire small PD after crossing the occlusion by the guidewire (*). (See online-only Data Supplement Video 2.) PD = posterior descending artery; PL = posterolateral artery. (See online-only Data Supplement Video 1.) (E) Nonselective right renal artery (RRA) angiography. It displays long dissection of the right renal artery (big dotted arrows) and indicates possible side-branch "string of beads" lesions (arrows). 4 F pigtail catheter used for non-selective RRA angiography (*).

Discussion

Spontaneous arterial dissection (SAD) is defined as a nontraumatic and noniatrogenic separation of the arterial walls, creating a false lumen. This separation can occur between the intima and media or between the media and adventitia [1, 2]. Spontaneous artery dissections are infrequent and underdiagnosed events affecting predominantly young and middle-aged patients and women [1–6]. The spontaneous dissection of a cervical artery accounts for only about 2% of all ischaemic strokes, but the proportion is much higher in young and middle-aged patients [1, 2]. It is difficult to determine the prevalence of coronary SAD ranging from 0.3 to 8% according to clinical setting, age and diagnostic method [2]. Renal SAD is an infrequent disease and epidemiology is based largely on case reports and series [1–6]. Peripartum and underlying heritable arteriopathies or FMD represent the major risk factors for SAD occurrence and recurrence [1–6].

The overall prognosis of cervical SAD is good, with a low mortality rate, good morbidity, and a low rate of recurrent dissection and of ischaemic and bleeding complications. Anticoagulant or antiplatelet treatment strategies have been implemented in its management. However, no large randomised trial has specifically addressed the management of cervical SAD [1]. Antiplatelet therapy is still considered the first choice, particularly for intracranial extension. Nonetheless, anticoagulation has also been used in the presence of floating thrombus, occlusion or progression on antiplatelet therapy [1]. Similarly, there are no prospective randomised data specifically addressing the management of coronary SAD by hard clinical endpoints [2, 3]. Therefore, uncertainty exists on whether the standard management of acute coronary syndrome may be beneficial for coronary SAD. Revascularisation procedures depend on the patient's performance status and affected coronary anatomy, but often conservative treatment is preferred for stable patients. The prognosis may be underestimated, since it relies mainly on post-mortem reporting, but female patients potentially have a poorer prognosis [2, 3]. The natural history of renal SAD is poorly understood owing to the infrequency of reporting and the lack of prospective data. Most renal dissections seem to be self-limiting, but malignant hypertension or renal failure secondary to ischaemia may occur [5–6]. Various individualised treatment options have been suggested for renal SAD based on lesion stability, renal function and the patient's performance status. These options include the conservative approach, medical therapy (such as anticoagulation), endovascular procedures such as arterial stenting or coiling, and surgical therapy such as vascular reconstruction or nephrectomy [5–6].

Correspondence:
Dr. Mattia Cattaneo, MD
Clinical and Research fellow
Department of Cardiovascular Medicine
Ospedale Regionale
di Bellinzona e Valli
San Giovanni
CH-6500 Bellinzona
mattia.cattaneo[at]eoc.ch

Disclosure statement
No financial support and no other potential conflict of interest relevant to this article was reported.

References

1 Yang-Ki K, Schulman S. Cervical artery dissection: Pathology, epidemiology and management. Thromb Res. 2009;123:810–21.
2 Yip A, Saw J. Spontaneous coronary artery dissection – A review. Cardiovasc Diagn Ther. 2015;5(1):37–48.
3 Giacoppo D, Capodanno D, Dangas G, Tamburino C. Spontaneous coronary artery dissection. Int J Cardiol. 2014;175(1):8–20.
4 Olin JW, Gornik HL, Bacharach JM, Biller J, Fine LJ, Gray BH, et al. Fibromuscular dysplasia: state of the science and critical unanswered questions: a scientific statement from the American Heart Association. Circulation. 2014;129:1048–78.
5 Edwards BS, Stanson AW, Holley KE, Sheps SG Isolated renal artery dissection: presentation, evaluation, management and pathology Mayo Clin Proc. 1982;57:564–71.
6 Lee SH, Lee HC, Oh SJ, Park MC, Park KJ, Moon YS, et al. Percutaneous intervention of spontaneous renal artery dissection complicated with renal infarction: a case report and literature review. Catheter Cardiovasc Interv. 2003;60(3):335–8.