A tachycardia with QRS duration narrower than that during sinus rhythm

Danielle Zaugg Longchamp, Etienne Pruvot

Service of Cardiology, Department of Intern Medicine, CHUV, Lausanne, Switzerland

Case presentation

An 83-year-old man with ischaemic heart disease and a triple bypass in 2007 presented to the emergency department with increasing shortness of breath and weight gain of 5 kg over one month. On physical examination the patient showed signs of acute heart failure. Left ventricular ejection fraction was poor (25%) and NT-pro BNP elevated (20058 ng/l, normal <738 ng/l). The 12-lead ECG (fig. 1) showed a regular tachycardia at a rate of 173 bpm with moderately prolonged QRS duration (140 ms) and right axis deviation. The infusion of amiodarone converted the arrhythmia into sinus rhythm. The 12-lead ECG in sinus rhythm (fig. 2) showed a left bundle brunch block with a QRS of 160 ms, whose duration was longer on averaged by 23 ms than that during tachycardia, and a 1st degree AV block (PR interval 240 ms).

Questions

What is the differential diagnosis of the 12-lead ECG (fig. 1)?
What is the mechanism of this arrhythmia?

Figure 1
12-lead ECG showing regular tachycardia at a rate of 173 bpm with moderately prolonged QRS duration of 140 ms.

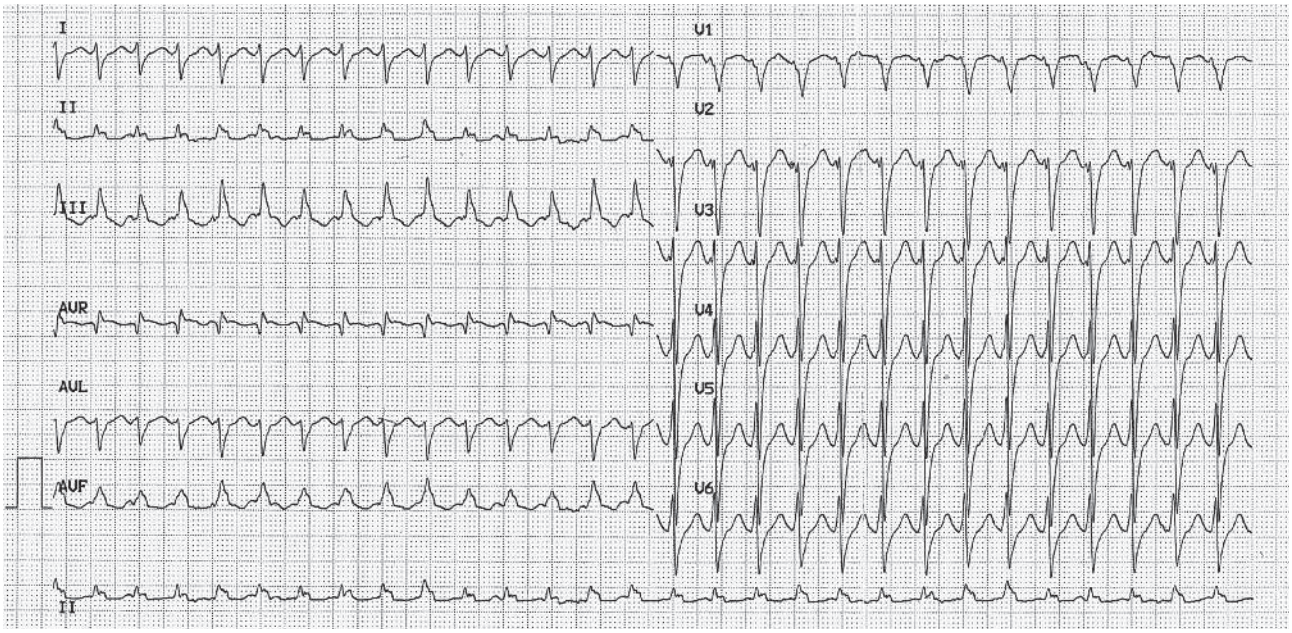

Funding / potential competing interests:
No financial support and no other potential conflict of interest relevant to this article were reported.

Correspondence:
Danielle Zaugg Longchamp, MD
Service of Cardiology, Department of Intern Medicine
CHUV
CH-1011 Lausanne
Switzerland
danielle.zaugg[at]chuv.ch

Figure 2
12-lead ECG in sinus rhythm showing LBBB morphology and a right axis deviation with a QRS duration of 160 ms.

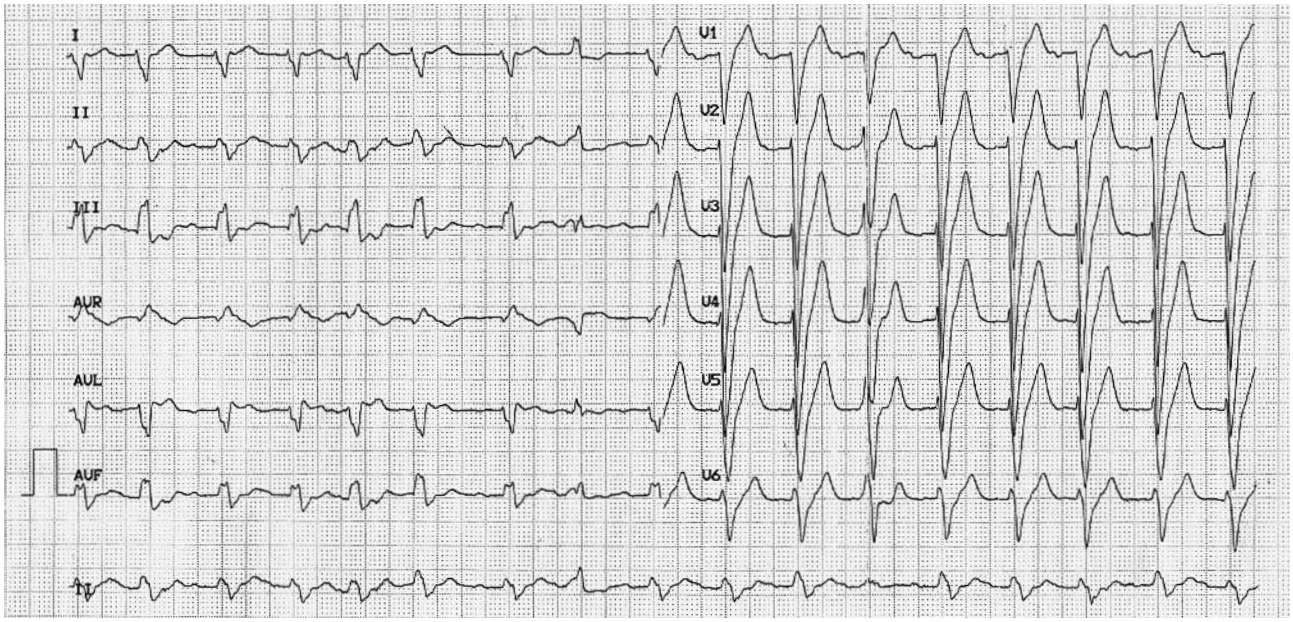

Comments

The differential diagnosis of the 12-lead ECG shown in figure 1 includes (1.) any supraventricular tachycardia (SVT) with functional or permanent fascicular block (i.e., posterior) such as an AV nodal reentrant tachycardia (AVNRT), an AV reciprocating tachycardia (AVRT), an atrial tachycardia or a flutter, (2.) an atrial arrhythmia with conduction over a bundle of Kent (parahissian), (3.) a purkinje fibre-mediated VT (reentry or focal), (4.) a nodofascicular tachycardia and (5.) an atriofascicular tachycardia.

Importantly, figure 1 also shows AV dissociation in leads II and V_1 that discards reentrant SVTs as a possible cause and raises the possibility of a rather narrow QRS VT. Also, it does not completely rule out an AVNRT, but makes it unlikely as rare cases of VA dissociation have been reported. In addition, the QRS duration in figure 1 is shorter than that in figure 2 without change in the main axis. The tachycardia exhibits a LBBB morphology, with an rS pattern in lead V_1, a near normal progression of the R wave in chest leads and a wide S wave in leads V_5 and V_6. This near normal pattern is suggestive of an activation that uses the upper septal His-Purkinje network. Taken together, these findings are suggestive of a purkinje-related arrhythmia (focal or reentry). Fascicular VT is a reentrant VT usually exhibiting an RBBB configuration and a superior axis or right axis deviation. In this case, one can reckon that the remote myocardial infarction might have substantially altered the conduction into the left ventricle and provoked a delayed left ventricular excitation and a posterior fascicular block, resulting in a LBBB type morphology during sinus rhythm [1, 2]. Fascicular VT is verapamil-sensitive, but in patients with poor left ventricular function, amiodarone is preferred [1, 2]. Although speculative (lack of mapping), the observation of a VT slightly narrower suggests that the circuit uses anterogradly the His-Purkinje conduction system, possibly below the site of the block responsible for the depolarisation delay in sinus rhythm. The clinical evolution of our patient was favourable after administration of amiodarone and treatment of the acute heart failure. A coronary angiogram had excluded a progression of the ischaemic disease. As the VT has not recurred, no electrophysiologic study has been performed yet.

References

1 Akihiko Nogami, M.D. Purkinje-related arrythmias Part I: Monomorphic ventricular tachycardias. PACE. 2011;34:624–50.
2 Hayashi M, Kobayashi Y, Iwasaki YK, Morita N, Miyauchi Y, Kato T. Novel mechanism of postinfarction ventricular tachycardia originating in surviving left posterior Purkinje fibers. Heart Rhythm. 2006;3:908–18.