

Available online at www.sciencedirect.com

ScienceDirect

journal homepage: <http://www.elsevier.com/locate/medici>

Original Research Article

Genetic linkage studies of a North Carolina macular dystrophy family

Mareta Audere^{a,1}, Katrina Rutka^{a,1}, Inna Inaskina^a, Raitis Peculis^a, Svetlana Sepetiene^b, Sandra Valeina^c, Baiba Lāce^{a,d,*}^a Latvian Biomedical Research and Study Center, Riga, Latvia^b Ophthalmology Clinic, Pauls Stradins Clinical University Hospital, Riga, Latvia^c Vision Center, Children's Clinical University Hospital, Riga, Latvia^d Centre Hospitalier De l'Université Laval, Québec, Canada

ARTICLE INFO

Article history:

Received 11 May 2015

Received in revised form

3 April 2016

Accepted 5 April 2016

Available online 19 April 2016

Keywords:

North Carolina macular dystrophy

Drusen

Proband

Parafoveal hemorrhage

Genome-wide microarray analysis

ABSTRACT

Background and objective: North Carolina macular dystrophy (NCMD) is a very rare autosomal dominant hereditary disease. Up to date there are three types of NCMD described and consequently named macular dystrophy, retinal: MCDR1, MCDR2 and MCDR3. The aim of this study was to perform linkage and copy number variation analysis for the family affected by NCMD followed by the selected candidate gene sequencing.

Materials and methods: This study concerned a 3-generation, non-consanguineous Latvian family with NCMD. Genome-wide scan, copy number variation and non-parametric linkage analysis was performed. Analysis resolved the locus of interest to the 5p15.33 region. Two of the genes, iroquois homeobox 2 (*IRX2*) and iroquois homeobox 4 (*IRX4*), were selected and sanger sequencing was performed.

Results: Linkage analysis indicated a region on chromosome 5 for the analyzed family, corresponding to a genetic locus previously described for MCDR3 (5p15-p13). Chromosomal aberrations were not identified in the affected family members. An upstream intron variant (NM_001278634: c.-139G > A (rs6876836)) in *IRX4* gene segregated with NCMD phenotype in the analyzed family.

Conclusions: It is unlikely to be the causative mutation of NCMD due to its high minor allele frequency 0.3532. Therefore, the role of *IRX2* and *IRX4* genes in the pathogenesis of NCMD has not been proved. Considerable variability in visual acuity between individuals of the same age group in all the families examined was noted. No overlap between NCMD grade and family generation was seen in the family described in the present study.

© 2016 The Lithuanian University of Health Sciences. Production and hosting by Elsevier Sp. z o.o. This is an open access article under the CC BY-NC-ND license (<http://creativecommons.org/licenses/by-nc-nd/4.0/>).

* Corresponding author at: Latvian Biomedical Research and Study Center, Ratsupites str. 1, Riga, Latvia. Tel.: +371 67808210.

E-mail addresses: mareta.audere@gmail.com (M. Audere), katrina.rutka@gmail.com (K. Rutka), inna@biomed.lu.lv (I. Inaskina), raitis@biomed.lu.lv (R. Peculis), dr.sepetiene@gmail.com (S. Sepetiene), sandrav@latnet.lv (S. Valeina), baiba.lace@biomed.lu.lv, baiba.lace@gmail.com (B. Lāce).

¹ These authors contributed equally to this work.

Peer review under the responsibility of the Lithuanian University of Health Sciences.

<http://dx.doi.org/10.1016/j.medici.2016.04.001>

1010-660X/© 2016 The Lithuanian University of Health Sciences. Production and hosting by Elsevier Sp. z o.o. This is an open access article under the CC BY-NC-ND license (<http://creativecommons.org/licenses/by-nc-nd/4.0/>).

1. Introduction

North Carolina macular dystrophy (NCMD) is an autosomal dominant dystrophy that was first reported as hereditary macular degeneration and aminoaciduria by Lefler et al. [1]. Extensive genealogical investigations in the first reported NCMD family and other families in the United States established a common ancestry to two Irish brothers who settled in North Carolina in the 1830s [2], although at the time the macular dystrophy was termed dominant foveal dystrophy [3] or central areolar pigment epithelial dystrophy [4,5].

The disease grade 1 is characterized by symmetric, tiny drusen-like yellow deposits that are found in foveal region. It can have a little impact on the vision, but also it may be found without any visual impairment at all [5,6]. Grade 2 has yellow flecks and intermediately decreased visual acuity. The third grade's clinical characteristics are colobomatous macular chorioretinal trophy that might be accompanied by pigment aggregations. Third grades visual impairment is severe [5]. Also peripheral retinal drusen may be present in all grades [6]. Progression of disease is believed to be possible only during the childhood (should be uncommon after the age of 12 years) [7]. Grading does not correlate with the successive progression of NCMD [5]. It is possible that even with a severe macular lesion relatively good visual acuity is retained [5]. If progression occurs, a subretinal neovascular membrane may develop and lead to fibrosis and noticeable loss of vision. This means that the patient may be largely asymptomatic until this happens [8].

Up to date there are three types of NCMD described and consequently named as macular dystrophy, retinal: MCDR1, MCDR2 and MCDR3. None of these types have been attributed to any particular gene; there are only linkage data available for the selected loci. Historically MCDR1 was analyzed more intensively and in the large kindred of 2000 individuals. The genetic locus 6q16 has been described and it most probably will contain MCDR1 causative gene [9]. MCDR2 type is caused by a mutation in *PROM1* gene on chromosome 4p15 [10]. In 2010 Rosenberg described a family in Scandinavia and performed linkage analysis for the ten members of family

[5]. The results overlap with the previously reported 5p13-p15 region for MCDR3 containing more than 55 genes [11].

The aim of this study was to perform linkage analysis for the family affected by NCMD followed by the selected candidate gene sequencing, and to have a clinical comparison between NCMD persons from the present study and previously reported cases.

2. Materials and methods

The study complies with the principles of the Declaration of Helsinki and was approved by the Central Medical Ethics Committee in Latvia. All subjects participating in this study were provided with information regarding the objectives of this study and issues regarding their possible participation in the study. All subjects or legal guardians of underage subjects included in this study have submitted a written informed consent form.

2.1. Subjects

This study concerns a three-generation, non-consanguineous Latvian family consisting of six family members, who agreed to participate in the study and donate blood samples (see the pedigree chart in Fig. 1). Other family members refused participation. One member (NC01, proband 1, born in 1994) of this family was independently referred to the Vision Center of the Children's Clinical University Hospital in Riga for a diagnostic examination. The findings initiated further examination of additional family members. Eight of them were found to have dystrophic changes in the macula congruent with the clinical characteristics of North Carolina macular dystrophy (NCMD). Subjects involved in this study underwent a standard examination, including a review of their visual symptoms, assessment of ocular alignment and motility and visual acuity, assessment of refraction, slit lamp examination, color vision screening, intraocular pressure measurement, color fundus photography. In addition, some of the patients underwent visual field assessment and optical coherence

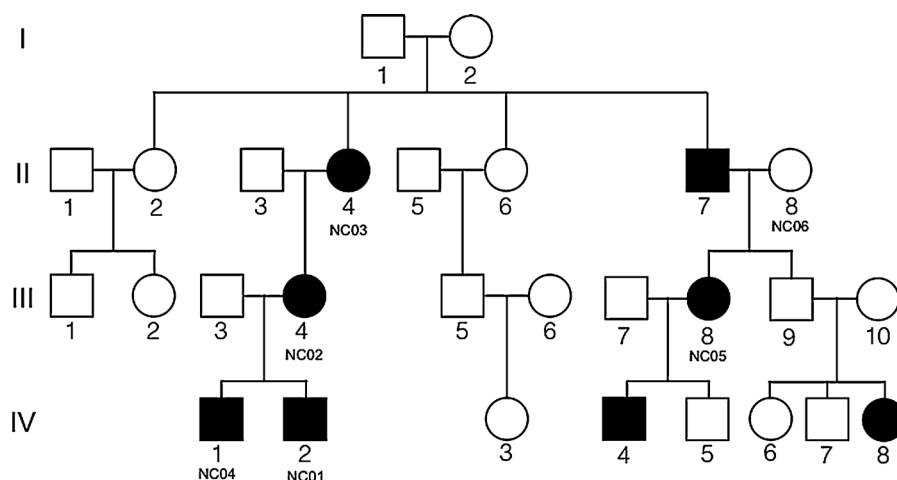


Fig. 1 – Pedigree chart of family in Latvia affected by North Carolina macular dystrophy (NCMD). Black colored symbols represent NCMD affected individuals and NCMD unaffected family members are represented by open symbols.

tomography. Venous blood samples were obtained from six family members (NC01–NC06) and DNA was prepared using standard methods.

Fig. 1 shows the pedigree chart of this family. An autosomal or X linked dominant inheritance is thought to be most likely due to the presence of the disease in three consecutive generations and equally affected females and males. Individual III9 was not enrolled into the study and refused clinical examination. Fig. 1 also reflects the identification codes assigned to the family members who gave venous blood samples, as well as their gender, clinical condition in relation to NCMD (Fig. filled in black – NCMD affected) and their place within the genealogy.

2.2. Genome-wide microarray analysis

A genome-wide scan was carried out in the Estonian Genome Center (Tartu University) and 733 202 single nucleotide polymorphisms (SNPs) were analyzed by Illumina HumanOmniExpress BeadChip 12 (Illumina, San Diego, CA, USA). Sample analysis was performed by manufacturer's instructions. Microarray data were subjected to copy number variation analysis to exclude chromosomal aberrations, followed with non-parametric linkage analysis using the Merlin software [12] and parametric linkage analysis under the model of autosomal or X linked dominant inheritance, which was done manually. The non-parametric linkage analysis by Merlin uses the Kong and Cox linear model [13]. Selected genes from the obtained results of region of interest were sequenced.

BeadChip data were processed in Illumina Genome Studio (Illumina). It was used to perform primary data analysis, normalization and genotype calling according to manufacturer's protocols. Log R ratios and B allele frequencies are also provided by Genome Studio Genotyping module for each probe and used in CNV calling by QuantiSNP2 software [14]. The default program settings were used to call CNVs.

2.3. Candidate gene sequencing analysis

LOD scores for the seven loci were equally similar, therefore for further studies, we overlapped our region of interest with the previous publications about linkage analysis of persons with North Carolina phenotype, and selected 5p15 region.

Basing on the results of the non-parametric linkage analysis the 5p13-p15 region was selected to carry out manual linkage analysis of polymorphisms within this region. Using information from the National Center for Biotechnology Information (NCBI) database regarding selected region, we identify 39 genes (SEMA5A, CTD-2201E9.1, SNHG18, SNORD123, TAS2R1, FAM173B, CCT5, CMBL, MARCH6, ROPN1L-AS1, ROPN1L, RPL30P7, ANKRD33B, DAP, CTNND2, LINC01194, RPS23P5, RPL29P13, DNAH5, TRIO, FAM105A, CCT6P2, EEF1A1P13, OTULIN, ANKH, RBBP4P1, MIR4637, UQCRBP3, HNRNPCKP5, SEPHS2P1, LOC101929359, LOC101929379, LOC100505806, LOC285692, LOC101929412, LOC645763, LOC100420683, LOC100422687, LOC100130744) localized within this region.

We hypothesized that early clinical presentation of macular dystrophy in our pediatric patients, are reason of impaired embryogenesis of the eye, and therefore we chose two genes (iroquois homeobox 2 (IRX2) and iroquois homeobox 4 (IRX4))

due to their association with eye structure development in embryogenesis [15,16]. Genes IRX2 and IRX4 localized in close proximity, but outside of co-segregating region in our family, however within the co-segregating region of the study in the larger Danish family with a maximum of the LOD score of 2.69 [5].

Amplification was carried out in a total volume of 50 µL using the GeneAmp® PCR System 9700 (Applied Biosystems, Foster City, CA, USA). Annealing temperatures and primer sequences are provided in Supplementary Table 1. PCR products were sequenced using the fluorescent Big Dye Terminator v. 3.1 Cycle Sequencing standard protocol on a 3130xl Genetic Analyzer (Applied Biosystems).

2.4. Phenotype description

Clinical data by carrying out patient examination was obtained from 6 NCMD affected family members, one of whom was not included in the genetic studies (IV-4, son of NC05). The clinical data of the NCMD affected subjects included in this study was compared with the clinical information included in the articles written by Michaelides et al. (2003) [11] and Rosenberg et al. (2010) [5]. The NCMD families were compared using the following criteria: visual acuity assessment, color vision screening, visual field assessment, disease grading based on fundus photography.

3. Results

3.1. Genetic linkage analysis

All six samples were genotyped using IlluminaOmniExpress BeadChip 12, which contains 730 525 markers.

A two-stage CNV review yielded 15 extremely reliable CNV calls with log Bayes factor above 35 deviating from two copy numbers (normal state) and 63 CNV calls with log Bayes factor above 10. There were no recurrent CNVs in an extremely confident group and four pairs of two-individual shared CNVs in the second group with maximum variation size 4356 designated by 8 probes. Two of these pairs were shared by healthy and affected family member. Therefore not one CNV can explain case status in this family. More detailed information regarding the CNV analysis is available in Supplementary Table 2.

3.2. Linkage disequilibrium analysis

Genome wide scan linkage analysis helped to identify several chromosomal positions with significant p value, but low LOD score due to the small number of informative meioses. Identified genetic loci are shown in Table 1.

3.3. Candidate gene sequencing

All the coding exons, promoter regions, exon and intron boundaries were sequenced for the IRX2 and IRX4 genes. A total of 11 unique sequence variations were identified within the IRX2 and IRX4 genes in the DNA samples of the six family members included in the present study. A published intron upstream variant (NM_001278634: c.-139G > A (rs6876836)) showed segregation with the phenotype in the Latvian NCMD

Table 1 – Genome-wide scan linkage analysis of the most significant data in family with North Carolina macular dystrophy.

Chromosomal locus	Position start (build 37.2 ver.)	Position finish (build 37.2 ver.)	Z score	Delta	LOD score	P value	Genes
18q22.2	67263136	67367633	2.462	1.126	0.577	0.05158	DOK6
7q33	133580447	147839308	2.452	1.126	0.576	0.05177	277 genes
17p12-17p11.2	14290820	16291752	2.445	1.126	0.575	0.05191	37 genes
3q24	145238164	145678873	2.437	1.126	0.574	0.05206	LARP7P4, GM2AP1, RPL21P39
20p12.2	10136402	10365407	2.442	1.126	0.574	0.05198	SNAP25, HIGD1AP15, RPL23AP6
4q28-q32	138794021	139019356	2.414	1.126	0.571	0.05252	LINC00616, SLC7A11
5p15.13-5p15.2	9438454	14970328	2.416	1.126	0.571	0.05248	39 genes

family – it was present in the DNA samples of the five NCMD affected family members (NC01–NC05) and was excluded in the DNA sample of the NCMD unaffected family member (NC06). An unpublished sequence variation (NM_001278634: c.1560 + 872G > C) was found in the *IRX4* 3' downstream sequence of the DNA sample of NC01. The remaining nine sequence variations were also published in the NCBI genome database and no correlation with any pathology was described. These sequence variations include c.765G > T (Glu255Asp, rs76906087) in the *IRX2* gene and c.-179T > G (rs11960636), c.-191G > T (rs11957344), c.90A > C (rs2232374), c.381A > G (rs4975753), c.1431C > T (rs2279589), c.*443.*444delTT (rs3830370), c.*542 + 331delG (rs11322851), c.*542 + 261T > G (rs4975709) in the *IRX4* gene.

3.4. Clinical data

Subject NC01 was a 13-year-old male with a visual acuity 0.10 in his right eye (0.63 with correction) and 0.20 in his left eye (0.33 with correction). In both eyes myopic astigmatism was detected. Assessment of the color vision did not show any

disturbances. Fundus photography revealed deep central chorioretinal atrophy with pigmentation (see Fig. 2). In optic coherent tomography (OCT) central macular chorioretinal atrophy was seen. Also places where choroidal neovascularization could develop were located. Visual field was not tested.

Subject NC02 was a 32-year-old female whose visual acuity was identical in both eyes being 0.80. Her color vision was normal. Fundus photography showed existence of nonprogressive central macular drusen (Fig. 2). In OCT drusen could be seen on Bruch's membrane. Visual field testing was not performed.

Subject NC03 was a 57-year-old female who also had the same visual acuity of 0.67 in both eyes, color vision without unusual findings. Fundus oculi examination revealed bilateral central macular non-progressive drusen (Fig. 2). OCT detected slightly reduced retinal pigment epithelium (RPE) and drusen on Bruch's membrane. Visual field was not tested (Table 2).

Subject NC04 was a 7-year-old male with a visual acuity 0.50 in the right eye and 0.29 in the left one. His binocular vision was 0.67. He had normal color vision. Visual field testing revealed bilateral small central scotomata that were more

Table 2 – Summary of the results of ophthalmological examination of the NCMD family members included in this study.

Patient		Visual acuity		Color vision	Visual fields	Fundus oculi	Grade
Sex/age		OD	OS				
NC01	Male/13	0.10 cc 0.63	0.20 cc 0.33	Normal	No data	Central deep chorioretinal atrophy with pigmentations	III
NC04	Male/7	0.50	0.29	Normal	Small central scotomata (OD>OS)	Central deep chorioretinal atrophy with pigmentations, there are places where CNV could develop, chorioretinal atrophy in retinal periphery	III
NC02	Female/32	0.80	0.80	Normal	No data	Non-progressive central macular drusen	I
NC03	Female/57	0.67	0.67	Normal	No data	Central macular non-progressive drusen in both eyes.	I
IV-4	Male/5	0.50	0.67	Normal	No data	Macular coloboma in both eyes, (OS>OD) OD: parafoveal hemorrhage, here could develop CNV in the future, parafoveal drusen. Chorioretinal atrophy in retinal periphery	III
NC05	Female/32	cc 0.20	cc 0.20	Normal	No data	Central macular chorioretinal atrophy with pigmentation in both eyes	II

The table summarizes clinical information (results of visual acuity, color vision, visual field and fundus oculi testing) regarding the subjects examined in the present study. Patients who submitted venous blood samples for genetic testing are indicated with an NC code. Ophthalmological examination was carried out also for an additional NCMD affected 4th generation family member (IV-4). OD, oculus dexter; OS, oculus sinister; cc, cum correctione. The disease grade was assigned for each patient basing on the findings of their fundus oculi examination.

explicit in his right eye. In fundus photography central deep chorioretinal atrophy with pigmentations and spots, where chorioidal neovascularization could develop, was observed together with peripheral retinal atrophy (Fig. 2). Optic coherent

tomography showed central macular chorioretinal atrophy and retinal layer thickness reduced to 87 μm .

Subject NC05 was a 32-year-old female who had bilateral myopic astigmatism that could be corrected to obtain visual

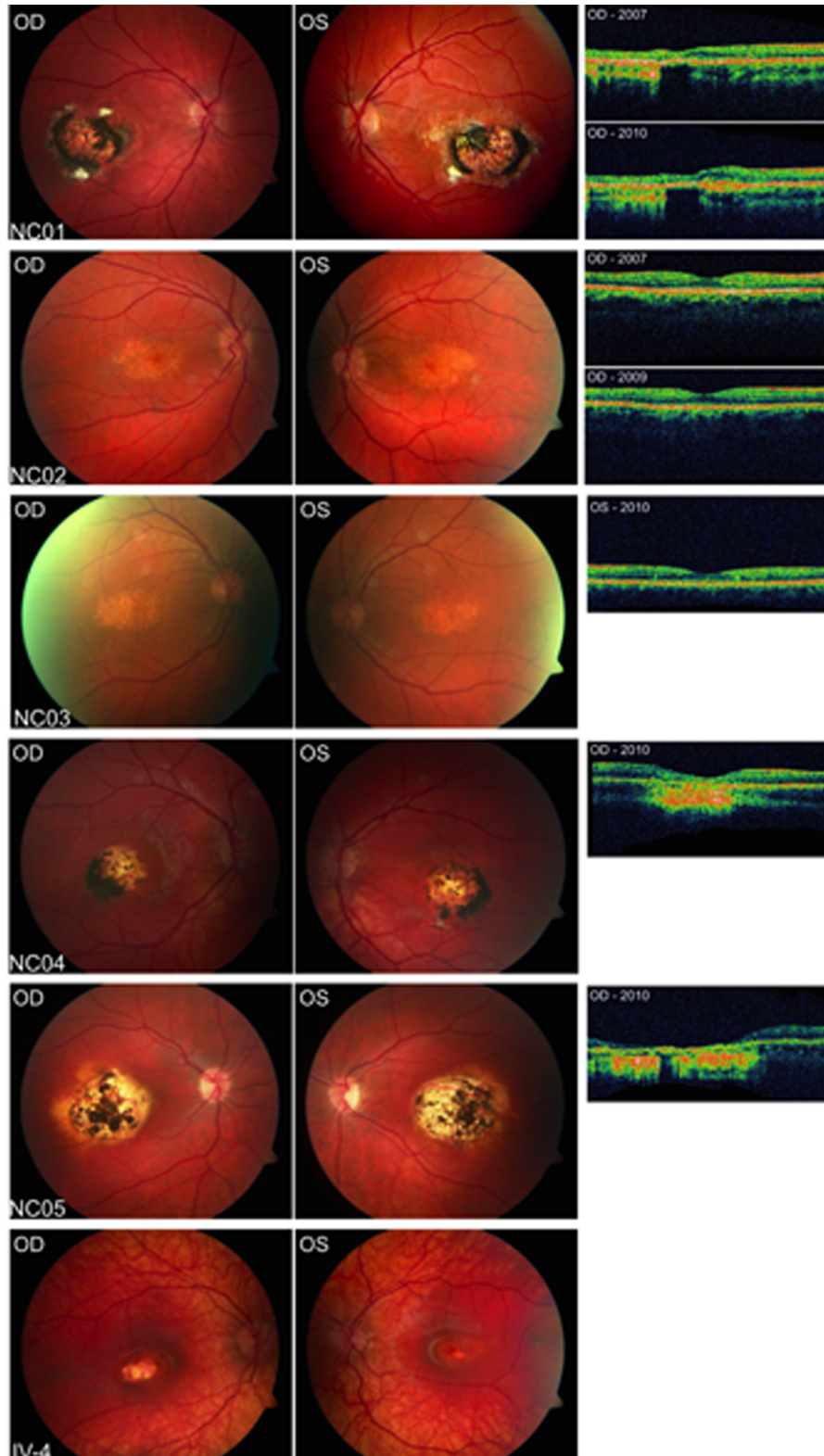


Fig. 2 – Fundus photography and optic coherent tomography of affected probands.

acuity 0.20. Color vision was without any deviation from normal. Like the previous subjects this one also had bilateral central macular chorioretinal atrophy with pigmentation (Fig. 2). OCT showed chorioretinal atrophy and a partially reduced retinal layer. Visual field was not tested.

Subject IV-4 was a 5-year-old male with visual acuity 0.50 in his right eye and 0.67 in his left eye. Color vision was normal. There were several things seen in fundus photography (Fig. 2). Firstly, there was a bilateral macular coloboma, which was more explicit in the left eye. Secondly, a parafoveal hemorrhage was detected in the right eye and that is important due to the possibility of the development of a chorioidal neovascular membrane. Also there were parafoveal drusen and peripheral chorioretinal atrophy. OCT was not performed for this subject. There were no data about visual field testing.

4. Discussion

After ophthalmological examination of several family members included in this study macular lesions were detected that are congruent with North Carolina Macular Dystrophy.

Genome wide scan microarray analysis did not identify copy number variations present in the affected and absent in unaffected family members. Therefore we can conclude, that unbalanced chromosomal aberrations larger than 2 kb are not the cause of NCMD in our family.

The linkage studies of this NCMD affected family did not confidently indicate any single informative region, however one of the highest LOD scores was generated for a region on chromosome 5 (5p15), which coincides with the described informative locus for MCDR3. The MCDR1 region on chromosome 6 showed an even less remarkable LOD score.

Basing on the information included in the NCBI human genome database regarding 39 genes located within this region, two genes (*IRX2* and *IRX4*) were selected for genetic sequencing due to their possible association with eye structure development in embryogenesis [15,16]. The results of genetic sequencing showed a published SNP (rs6876836) located in the 5' untranslated region of the *IRX4* gene of the five NCMD affected family members (NC01–NC05), but it was not found in the unaffected family member (NC06), thus, displaying genetic segregation with the NCMD phenotype. However, the minor allele frequency of this SNP is $C = 0.3532$, therefore, making it unlikely that this SNP is the causative mutation of a disease with such a low prevalence. This would probably hold true even taking into account that it is also most likely under diagnosed, therefore, having a higher prevalence than reported this far. It may be possible that the causative mutation lies in one of the other 25 genes located in the 5p15 region.

Visual acuity (VA) was decreased in all 6 NCMD affected subjects included in this study. The study by Michaelides et al. (2003) included 11 NCMD affected subjects; VA was assessed in 9 individuals, 5 of whom were reported to have decreased VA [11]. However, it was not explicitly stated that this was the best-corrected visual acuity. Rosenberg et al. (2010) describe 11 NCMD patients where 6 patients have decreased best-corrected visual acuity, three of which had

unilaterally decreased VA [5]. Though, it has to be mentioned that in Rosenberg's study one of the patients (II-1) with decreased VA had amblyopia and II-2 had hemorrhages and cotton wool spots due to undiagnosed arterial hypertension [5]. These factors could contribute to decreased VA regardless of the NCMD caused macular lesions. In all of the families there was fairly high visual acuity variability among individuals of the same age group. All six NCMD affected subjects in this study had normal color vision. Visual field testing was carried out for one of the NCMD affected individuals in this study, showing bilateral small central scotomata.

Minor phenotypical differences between the types of NCMD have been previously described. Normal color vision and non-progression of the macular lesions is more often characteristic of MCDR1, while color vision defects and progression of the disease is more often seen in individuals with MCDR3 [17]. However, the study by Michaelides et al. (2003) reports an NCMD affected family with a mixed phenotype of clinical characteristics (mild color vision abnormalities, one person with disease progression) of both MCDR1 and MCDR3, but their genetic linkage studies have excluded the location of the causative gene on chromosome 6 and have shown significant linkage to a region on chromosome 5 [11]. The family members participating in the present study were found to have normal color vision and no progression of macular lesions, but one of the participants showed a slight decrease in visual acuity. Thus, the clinical features resemble the phenotype of MCDR1. It seems that the MCDR1 and MCDR3 phenotypes are actually more overlapping than previously thought [17], thus, making it more difficult to clinically distinguish these two types of NCMD.

While our paper was under review, a recent article was published reporting variants for the MCDR1-linked NCMD upstream of the *PRDM13* and *CCNC* genes and MCDR3-linked NCMD to be associated with duplication in *IRX1* gene [18].

5. Conclusions

The most significant findings reported here are results that unbalanced chromosomal aberrations larger than 2 kb are not the cause of NCMD in our patients. The extensive sequencing of the genes *IRX2* and *IRX4*, did not reveal pathological sequence variations. From the clinical point of view, all six NCMD affected subjects in this study had normal color vision, decreased visual acuity and no progression of macular lesions.

Conflict of interest

All authors declare no conflict of interest.

Acknowledgements

The authors of this publication express their gratitude to all of the patients who agreed to participate in this study.

Appendix A. Supplementary data

Supplementary data associated with this article can be found in the online version, at [doi:10.1016/j.medici.2016.04.001](https://doi.org/10.1016/j.medici.2016.04.001).

REFERENCES

- [1] Lefler WH, Wadsworth JA, Sidbury JB. Hereditary macular degeneration and amino-aciduria. *Am J Ophthalmol* 1971;71:224–30.
- [2] Small KW, Hermesen V, Gurney N, Fetkenhour CL, Folk JC. North Carolina macular dystrophy and central areolar pigment epithelial dystrophy. One family, one disease. *Arch Ophthalmol* 1992;110:515–8.
- [3] Frank HR, Landers MB, Williams RJ, Sidbury JB. A new dominant progressive foveal dystrophy. *Am J Ophthalmol* 1974;78:903–16.
- [4] Hermesen VM, Judisch GF. Central areolar pigment epithelial dystrophy. *Ophthalmologica* 1984;189:69–72.
- [5] Rosenberg T, Roos B, Johnsen T, Bech N, Scheetz TE, Larsen M, et al. Clinical and genetic characterization of a Danish family with North Carolina macular dystrophy. *Mol Vis* 2010;16:2659–68.
- [6] Small KW. North Carolina macular dystrophy, revisited. *Ophthalmology* 1989;96:1747–54.
- [7] Reichel MB, Kelsell RE, Fan J, Gregory CY, Evans K, Moore AT, et al. Phenotype of a British North Carolina macular dystrophy family linked to chromosome 6q. *Br J Ophthalmol* 1998;82:1162–8.
- [8] Small KW, Killian J, McLean WC. North Carolina's dominant progressive foveal dystrophy: how progressive is it? *Br J Ophthalmol* 1991;75:401–6.
- [9] Yang Z, Tong Z, Chorich LJ, Pearson E, Yang X, Moore A, et al. Clinical characterization and genetic mapping of North Carolina macular dystrophy. *Vis Res* 2008;48:470–7.
- [10] Yang Z, Chen Y, Lillo C, Chien J, Yu Z, Michaelides M, et al. Mutant prominin 1 found in patients with macular degeneration disrupts photoreceptor disk morphogenesis in mice. *J Clin Invest* 2008;118:2908–16.
- [11] Michaelides M, Johnson S, Tekriwal AK, Holder GE, Bellmann C, Kinning E, et al. An early-onset autosomal dominant macular dystrophy (MCDR3) resembling North Carolina macular dystrophy maps to chromosome 5. *Invest Ophthalmol Vis Sci* 2003;44:2178–83.
- [12] Abecasis GR, Cherny SS, Cookson WO, Cardon LR. Merlin – rapid analysis of dense genetic maps using sparse gene flow trees. *Nat Genet* 2002;30:97–101.
- [13] Kong A, Cox NJ. Allele-sharing models: LOD scores and accurate linkage tests. *Am J Hum Genet* 1997;61(November (5)):1179–88.
- [14] Colella S, Yau C, Taylor JM, Mirza G, Butler H, Clouston P, et al. QuantiSNP: an Objective Bayes Hidden-Markov Model to detect and accurately map copy number variation using SNP genotyping data. *Nucleic Acids Res* 2007;35:2013–25.
- [15] Bosse A, Zülch A, Becker MB, Torres M, Gómez-Skarmeta JL, Modolell J, et al. Identification of the vertebrate Iroquois homeobox gene family with overlapping expression during early development of the nervous system. *Mech Dev* 1997;69:169–81.
- [16] Jin Z, Zhang J, Klar A, Chédotal A, Rao Y, Cepko CL, et al. Irx4-mediated regulation of Slit1 expression contributes to the definition of early axonal paths inside the retina. *Development* 2003;130:1037–48.
- [17] Small KW. North Carolina macular dystrophy: clinical features, genealogy, and genetic linkage analysis. *Trans Am Ophthalmol Soc* 1998;96:925–61.
- [18] Small KW, DeLuca AP, Whitmore SS, Rosenberg T, Silva-Garcia R, Udar N, et al. North Carolina macular dystrophy is caused by dysregulation of the retinal transcription factor PRDM13. *Ophthalmology* 2016;123(January (1)):9–18.