

CLINICAL CASE REPORT

Medicina (Kaunas) 2013;49(4):191–4

Endoscopic Removal of the Osteochondroma of the Fibular Head

Rimtautas Gudas, Arnoldas Pocius

Department of Orthopedics and Traumatology, Medical Academy, Lithuanian University of Health Sciences, Lithuania

Key Words: *osteochondroma; fibular head; endoscopic removal.*

Summary. *We report the case of the osteochondroma of the fibular head in a 40-year-old female patient who underwent an endoscopic extirpation of a relapsed benign tumor. Initially, open surgery was performed, and the tumor was removed 3 years ago. Following the reoccurrence of the symptoms 3 years after the initial open extirpation, an x-ray and computed tomography of the calf were performed. The tumor was endoscopically removed, and the diagnosis of a relapsed osteochondroma measuring 1.5×1.5×2 cm was established.*

Endoscopic surgery can be applied for a successful extirpation of the osteochondroma of the fibular head.

Introduction

Osteochondroma is the most frequent benign bone tumor (1–4). Osteochondromas account for approximately 38% to 43% of all benign bone tumors around the knee (1–4). Osteochondroma occurs in the areas of bone and cartilage. Tumors are most often found in the long bones, especially near the knee. Lesions occur only in bones that develop from cartilage (enchondral ossification). These tumors made up 35%–40% of all diagnosed benign bone tumors as well as 9%–10% of all bone tumors (1–4). The majority of osteochondromas are asymptomatic and are diagnosed incidentally (5, 6); however, some may cause various symptoms due to a mechanical impact to the adjacent tissues. A fracture can occur through the stalk of the lesion, which also causes pain. Osteochondromas are most likely caused by either a congenital defect or trauma of the perichondrium, which results in the herniation of a fragment of the epiphyseal growth plate through the periosteal bone cuff. Osteochondromas can either be flattened (sessile) or stalk-like (exostosis) and can occur in a juxta-epiphyseal location. Osteochondromas may also occur as a consequence of radiation therapy in children. After the closure of the growth plate in late adolescence, there is normally no further growth of the osteochondroma. Asymptomatic osteochondromas do not require treatment. If the lesion causes pain or neurologic symptoms due to compression, it should be excised at the base. Typically, in the presence of indications, osteochondromas are removed by open surgery (7). As long as the entire cartilage cap is removed, there should be

no recurrence. Patients with many especially large osteochondromas should undergo regular screening and x-ray examinations to early detect a malignant transformation. Hereditary multiple osteochondromatosis is an autosomal dominant condition that can lead to both sessile and pedunculated lesions. Lesions may occur in different bones or the same bone, and usually symptoms manifest in the first decade of life. The risk of malignant transformation to chondrosarcoma in hereditary multiple osteochondromatosis is unknown, but may be 25%–30% compared with approximately 1% for solitary osteochondromas. The risk of malignant degeneration increases when the number and size of osteochondromas increase. In general, a sessile lesion is more likely to degenerate into sarcoma than an exostosis. The surgical removal of the lesion is usually successful (7). This involves opening the skin over the tumor, locating the osteochondroma, and cutting it out. In cases of the inherited form where many lesions are present, new tumors may arise in the same area. There is a very small chance (5%) that the tumor will come back after it is removed surgically.

We would like to present a clinical case when the osteochondroma of the fibular head was removed by endoscopic surgery. To our knowledge, no other cases employing a similar surgical approach were published before.

Case Report

A 40-year-old woman presented with a 4-year history of the numbness of the anterior surface of the calf, burning pain, and twinkling of the muscles of the calf. The patient contacted our hospital in 2008 and was consulted by the orthopedist-traumatologist. An x-ray and computed tomography were performed, and the bone tumor of the fibular head

Correspondence to R. Gudas, Department of Orthopedics and Traumatology, Medical Academy, Lithuanian University of Health Sciences, Eivenių 2, 50028 Kaunas, Lithuania
E-mail: rimtautas.gudas@kaunoklinikos.lt

area was diagnosed (Fig. 1). The electromyoneurography test revealed the signs of the demyelination of the peroneal nerve. The tumor was removed in July 2008 during open surgery. The specimen of the tumor tissue was obtained during the surgery. The histological evaluation was performed, and the clinical diagnosis of osteochondroma was established. The postoperative period was uneventful, the unpleasant symptoms disappeared. However, the same symptoms reoccurred at the beginning of the 2011 year. The patient repetitively contacted the Clinic of Orthopedics and Traumatology at our Hospital. An x-ray and computed tomography of the left calf were performed, and the recurrence of the osteochondroma of the fibular head was confirmed (Fig. 2). It was decided to perform an endoscopic surgical removal of the osteochondroma in

October 2011. The postoperative follow-up x-ray did not indicate any signs of the tumor (Fig. 3). At a mean follow-up of 11 months, the patient was functionally pain free.

Surgical Approach. The patient was placed in the right lateral decubitus position. Spinal anesthesia was performed, and the tourniquet was applied in the middle portion of the thigh at the pressure of 300 mm Hg. Three 8-mm incisions at the lateral side of the calf were made. The endoscope was introduced, and the head of the fibula was accessed. The osteochondroma was found within the boundaries of healthy tissues (Fig. 4). The peroneal nerve was revised; no pathological findings were observed. The adjacent tissues were separated by the means of arthroscopic instruments, i.e., a shaver and a bore. The osteochondroma was removed within the

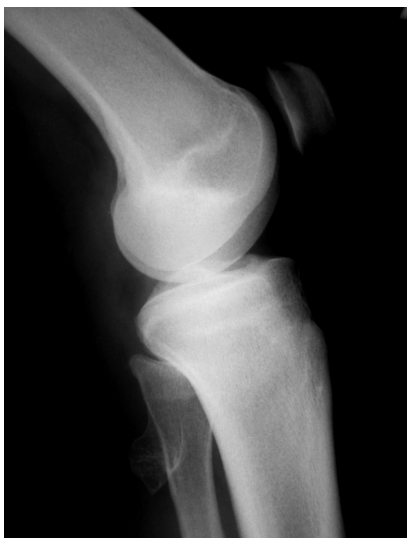

Fig. 1. An x-ray scan showing the bone tumor in the area of the fibular head

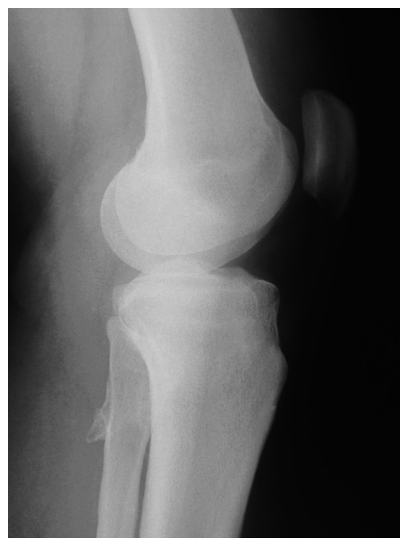

Fig. 2. An x-ray scan of the left calf performed 3 years after the initial operation, which shows the recurrence of the osteochondroma of the fibular head

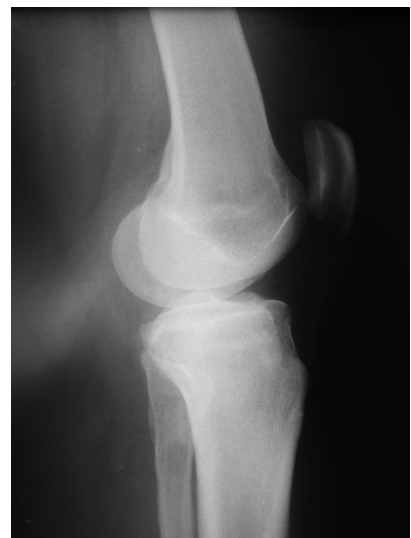

Fig. 3. A postoperative follow-up x-ray demonstrating the full extirpation of the tumor

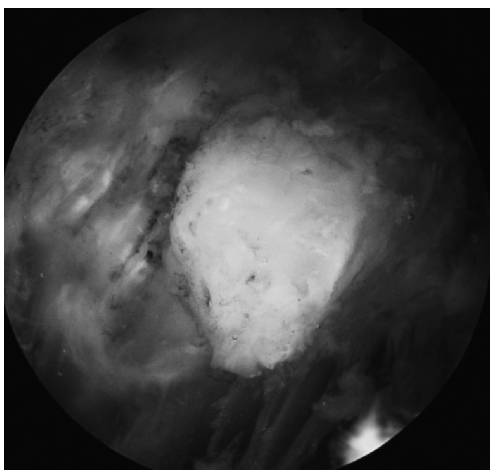


Fig. 4. An endoscopic view of the osteochondroma, which was found within the boundaries of healthy tissues

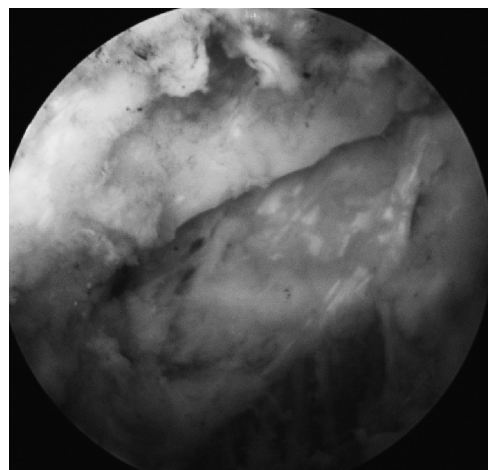


Fig. 5. An endoscopic view of the fully removed osteochondroma within the boundaries of healthy tissues

boundaries of healthy tissues (Fig. 5). The cavity was excessively washed, the incisions were stitched, and the sterile dressing was applied. The course of the surgery was smooth; no complications developed. The patient was allowed to fully step on that foot on the next day. The patient was discharged from the hospital, and the outpatient treatment was administered.

Discussion

Surgical complication rates for an open extirpation of an osteochondroma have been reported as high as 10% (7). The endoscopic techniques allow a surgical resection with small incisions and lower risk and lower postoperative morbidity rates. Historically, the extra-articular endoscopic resection of bone tumors was first introduced and applied in case of a chondroblastoma of the femoral head in 1995 (7). The literature sources emphasized the superiority of endoscopically assisted tumor resection to the traditional surgical treatment (8–12). By the use of endoscopy, the size of the incision, the amount of sacrificed soft tissue, and the blind dangerous areas can be efficiently reduced. Thus, the entire tumor resection is achieved even through a small incision. Consequently, the patient can achieve an early functional recovery and a cosmetic advantage. This reduces the length of hospital stay and decreases postoperative morbidity rates. The endoscopic technique allows performing resection as an outpatient procedure and involves a rapid functional recovery. Unfortunately, there are scarce data about the endoscopic treatment of osteochondromas, especially when revision surgery is indicated. In our case report, we have presented a complicated case of osteochondroma recurrence with the compression of the peroneus nerve and severe pain. An open surgical removal was performed at the first stage of the operation, but the osteochondroma of the same localization was diagnosed after the open surgical removal, and revision surgery was indicated in this special case. It is common to perform open surgery under such circumstances, but scar tissue formation may complicate open surgery or iatrogenic nerve and vessel injuries

can occur during open revision surgeries. In our case, the access to the tumor was also difficult and complicated using an open approach. Thus, when the revision surgery was planned, it was decided to remove the tumor by an endoscopic approach. The endoscopic approach allowed better visualization of the tumor itself and protection of the soft tissues around the tumor. Moreover, the integrity of the peroneus nerve was evaluated at the same time. The course of the surgery was smooth, and no complications developed. The endoscopic approach allowed us to feel more comfortable and safe during the whole operation, and the careful removal of the entire tumor was performed under the direct visualization by the arthroscopic equipment. Khapchik et al. (11) described the relation of major neurovascular structures to safe portal sites. The most frequently occurring complications after open surgery are the growth disturbance of the bone in children, bone fractures, lesions of nerves or vessels, and an incorrectly established initial diagnosis. Our approach confirmed that the completely endoscopic removal of the tumor is a safe and effective surgical procedure. We recommend an endoscopic technique for the excision of osteochondromas to prevent injury to the surrounding soft tissues. Further investigations are necessary in order to evaluate a possible incidence of postoperative complications. In addition, the recurrence rate, which is 2%–5% after open surgery, should be evaluated after the endoscopic operation as well.

Concluding Remarks

In our clinical case with a symptomatic osteochondroma of the proximal fibula close to the knee, endoscopic resection was performed, which resulted in low morbidity and a prompt functional recovery.

Endoscopic surgery can be applied for a successful extirpation of the osteochondroma of the fibular head.

Statement of Conflict of Interest

The authors state no conflict of interest.

References

1. Chin RK, Kharrazi FD, Miller BS, Mankin HJ, Cebhardt MC. Osteochondromas of the distal aspect of the tibia or fibula. Natural history and treatment. *J Bone Joint Surg Am* 2000;82:1269–78.
2. Mir BA, Wani MM, Halwai MA. Giant osteochondroma of proximal fibula in a skeletally mature patient. *Musculoskeletal Surg* 2011;95:41–4.
3. Day FN, Ruggieri C, Britton C. Recurrent osteochondroma. *J Foot Ankle Surg* 1998;37:162–4.
4. Wani IH, Sharma S, Malik FH, Singh M, Shiekh I, Salaria AQ. Distal tibial interosseous osteochondroma with impending fracture of fibula – a case report and review of literature. *Cases J* 2009;2:115.
5. Murphey D, Choi JJ, Kransdorf MJ, Flemming DJ, Gannon FH. Imaging of osteochondroma: variants and complications with radiologic-pathologic correlation. *Radiographics* 2000;20:1407–34.
6. Uri DS, Dalinka MK, Kneeland JB. Muscle impingement: MR imaging of a painful complication of osteochondromas. *Skeletal Radiol* 1996;25:689–92.
7. Gil-Albarova MA, Gil-Albarova R, Bregante-Baquero J. Fibular rotational osteotomy for the treatment of distal tib-

- ial osteochondroma: a technical modification for deformity correction and improved outcomes. *J Foot Ankle Surg* 2007;46:474-9.
8. Ayerza MA, Abalo E, Aponte-Tinao L, Muscolo DL. Endoscopic resection of symptomatic osteochondroma of the distal femur. *Clin Orthop Relat Res* 2007;459:150-3.
 9. Bracaglia R, Fortunato R, Marando A, Farallo E. Frontal exostose resection during an endoscopic subperiosteal lifting: case report. *Aesthetic Plast Surg* 1997;21:122-4.
 10. Eaves FF 3rd, Bostwick J 3rd, Nahai F. Instrumentation and setup for endoscopic plastic surgery. *Clin Plast Surg* 1995;22:591-603.
 11. Khapchik V, O'Donnell RJ, Glick JM. Arthroscopically assisted excision of osteoid osteoma involving the hip. *Arthroscopy* 2001;17:56-61.
 12. Fukunaga S, Futani H, Yoshiya S. Endoscopically assisted resection of a scapular osteochondroma causing snapping scapula syndrome. *World J Surg Oncol* 2007;5:37.

Received 20 February 2012, accepted 19 September 2012