

CLINICAL CASE REPORT

Medicina (Kaunas) 2013;49(2):67–70

A Mediastinal Mass Mimicking Asthma Symptoms

Valdonė Misevičienė¹, Liutauras Labanauskas¹, Rosita Kiudeliienė¹,
Rimantas Kėvalas¹, Jurgita Zaveckienė², Lina Jankauskaitė³

¹Department of Children's Diseases, Medical Academy, Lithuanian University of Health Sciences, Lithuania,

²Department of Radiology, Medical Academy, Lithuanian University of Health Sciences, Lithuania,

³Justus Liebig University Giessen, Germany

Key Words: *extramedullary sarcoma; mediastinal mass; superior vena cava syndrome; asthma; adolescent.*

Summary. *Extramedullary myeloid sarcoma is a rare form of myelogenous leukemia. It can involve any anatomical body part. Mediastinal involvement is reported in only few cases. We report on a case of extramedullary myeloid sarcoma presenting as a mediastinal mass in a previously healthy nonleukemic male teenager with primary asthmatic complaints and the signs of superior vena cava syndrome.*

Introduction

Extramedullary myeloid sarcoma (EMS) is a rare form of myelogenous leukemia. It can involve any anatomical part of the body, but skin, bones, and lymph nodes are the most commonly affected sites (1, 2). Mediastinal involvement is reported only in a few cases (3, 4). Rarely, it occurs in patients without the manifestation of acute leukemia in blood and bone marrow (1–5). There are no age limits, but it is still more prevalent in children younger than 15 years (1).

We hereby report a case of EMS presenting as a mediastinal mass in a 15-year-old previously healthy nonleukemic male patient with the primary asthmatic complaints of dyspnea and night cough, progressing with the signs typical of superior vena cava syndrome (SVCS).

Case Report

A 15-year-old previously healthy boy was admitted to the emergency room (ER) with typical asthmatic complaints of dyspnea and a chronic dry cough worsening at night.

From the anamnesis, it was found out that he was complaining about malaise and a bad mood for half a year. He gained 15 kg in 6 months without noticing an increased appetite and complained of physical load intolerance. He had been healthy until then. Dyspnea and cough intensified in the period of the previous 3 months. Since the parental history was positive for asthma and the sensitization to house dust mites was confirmed, allergic asthma was suspected. Consequently, the symptomatic treatment

was administered; however, it was ineffective. The boy's condition worsened with time. Weakness, as well as sweating, was increasing, and he noted facial swelling and flushing episodes, which were more pronounced in the morning, for about a month before the admission to the ER. Spirometry and chest x-ray were not performed during that period.

On a physical examination in the ER, no respiratory distress, lymphadenopathy, or other obvious pathology, except for increased arterial blood pressure (138/92 mm Hg), were documented. He was obese: his weight and height was 89 kg (97‰) and 179 cm (90‰), respectively. His face looked as if it was swollen and flushed although this was difficult to evaluate due to his obesity. The capillaries on the chest were dilated, and axillary hyperpigmentation was seen.

The complete blood count (CBC), as well as the C-reactive protein and urine test, showed no pathological findings. A chest x-ray revealed a mediastinal enlargement; however, due to insufficient inspiration and constitutional features, the evaluation was doubtful (Fig. 1). As the diagnosis was not clear, the patient was hospitalized to the Department of Pediatric Pulmonology for more thorough investigations into a suspected mediastinal mass, atypical infection, and asthma as well.

Empirical treatment with clarithromycin was started because of suspected atypical infections. His general condition was stable in the first week after the admission. He was coughing during the night, but no episodes of dyspnea were observed. The results of lung auscultation were normal. His face looked more swollen in the morning, but the swelling was not pronounced.

Despite the weak sensitization to house dust mites on skin prick tests, there were not enough data supporting the diagnosis of asthma or allergic rhinitis:

Correspondence to V. Misevičienė, Department of Children's Diseases, Medical Academy, Lithuanian University of Health Sciences, Eivenių 2, 50028 Kaunas, Lithuania
E-mail: valdonemis@yahoo.com

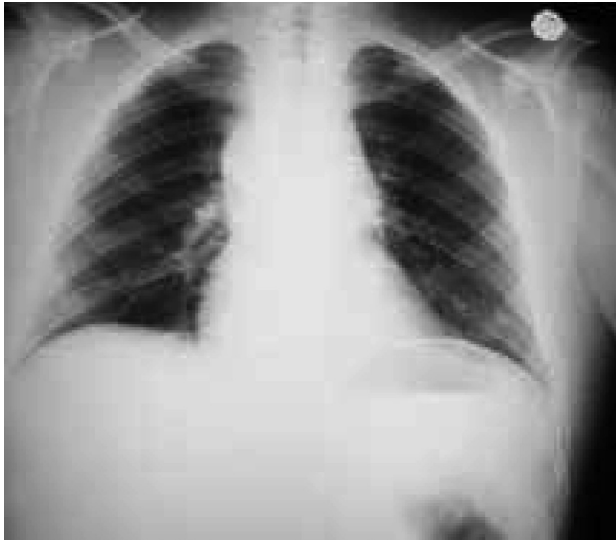

Fig. 1. Chest x-ray showing the increased mediastinum

the spirometry showed the signs of a stable obstruction in the large bronchi with no response to a bronchodilator (Fig. 2); the peak expiratory flow showed no variability and was significantly decreased (270 L/min vs. 518 L/min). IgM *Mycoplasma pneumoniae* was 15.2 U/mL (doubtful), but there were no other findings of possible atypical infections including tuberculosis.

The persistent mediastinal enlargement on a repeated chest x-ray (7 days after the admission) with the limited homogenous mass on the lateral view was confirmed (Fig. 3). For this reason, computed tomography (CT) of the chest was performed. It showed the mediastinal enlargement due to nonhomogeneous masses: lymphoid-like masses surrounding the aortic arch, spreading to all the superior mediastinum and tracheal bifurcation, circularly surrounding all the aortic arch branches, pressing the superior vena cava and the distal subclavian venous part, merging with subclavian lymph node conglomerates, and infiltrating the pericardium (Fig. 4).

Bone marrow and mediastinal lymph node biopsies were performed. These procedures were complicated by aggravated ventilation due to the tracheal obstruction and bleeding. The patient was admitted to the Pediatric Intensive Care Unit (PICU) and was given prolonged ventilation. The bone marrow biopsy showed erythropoietic hyperplasia, but there was no infiltration with tumor cells. While the results of lymph node biopsy were pending, empirical chemotherapy with dexamethasone, vincristine, and cyclophosphamide was started, but no improvement in the patient's general condition was observed. When the lymph node biopsy results were evident – cells stained positively for MPO, CD34, and TDT-339 – the tumor was diagnosed as an EMS or, in other words, the sarcoma of the primitive formed

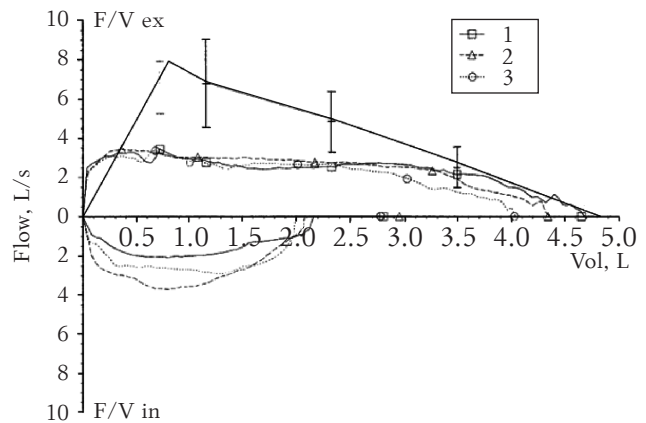


Fig. 2. Spirometry with the signs of stable obstruction in the large bronchi with no response to a bronchodilator

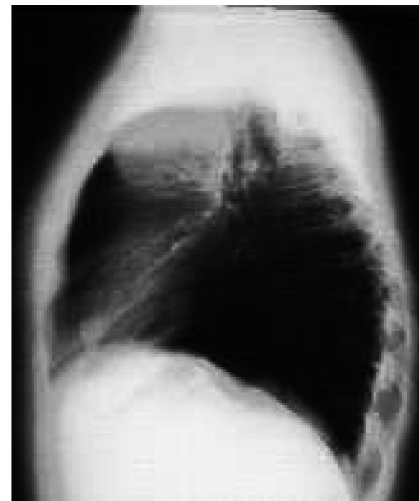
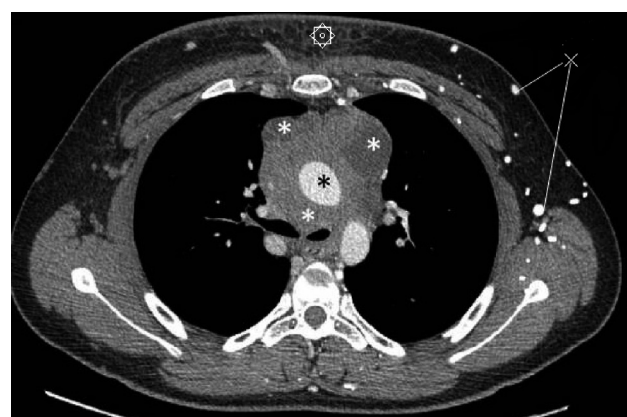
Fig. 3. Repeated chest x-ray showing a limited homogenous mass on the lateral view



- * Medial masses surrounding vascular structures, trachea, and main bronchi
- * Aorta
- ⊠ Subcutaneous edema
- ⊗ Subcutaneous veins

Fig. 4. Computed tomography scan of the chest

elements of the blood.

For further treatment, the teenager was transferred to the Leukemia Center. His general condition was critical: nosocomial pneumonia and sepsis (*Pseudomonas aeruginosa*) evolved, and the treatment with carbapenem was started. A repeated lymph node biopsy coincided with the abovementioned results: cells stained positively for MPO, as well as for CD34, TDT, and CD99. Meanwhile, leukemization (50% of blasts with a phenotype characteristic of a myelogenous origin) on the bone marrow aspiration was already noticed. Chemotherapy according to the scheme was started; however, there was no effect. The patient died 45 days after the admission to the ER.

Discussion

EMS, also known as granulocytic sarcoma or chloroma, is a rare extramedullary form of myelogenous leukemia, deriving from the primitive precursors of the granulocytic series of white blood cells. EMS is mostly found concurrently with or subsequently after previously diagnosed acute myelogenous leukemia (AML) (1, 3, 5–7). Rarely, it can antedate AML appearing as an isolated mass (1–2), thus, making the diagnosis challenging. As shown in our clinical case, the patient was a previously healthy nonleukemic boy. The initial symptoms and complaints presented themselves 6 months before the referral to the ER and were not characteristic of EMS, more resembling the classical presentation of pediatric asthma. Moreover, the confirmed sensitization to house dust mites and a positive parental history suggested that the diagnosis of asthma was very likely. Spirometry, according the guidelines of the Global Initiative for Asthma (8), is the recommended method to establish the diagnosis of asthma, but it was not performed since the patient was referred to consult an allergist only once. Besides, the chest x-ray is not a preferred investigation method for the diagnosis of asthma (8), being more required in unclear, severe cases of previously diagnosed asthma. The EMS in our case was located in the mediastinum, and according to different data, it is a very rare case of EMS with no specific warning signs (3, 4). The condition worsening and progression of the symptoms were lingering, and our patient developed SVCS 1 month before hospitalization. According to the literature, SVCS could represent an initial mode of EMS (3), but it is neither specific to nor pathognomic of only EMS, again being quite a rare syndrome in children (most often having a malignant lymphoma). Furthermore, the teenager was obese, which made the recognition of SVCS more complicated. The most informative signs helping to suspect EMS could be the abnormal results of peripheral blood and bone marrow

biopsies, in combination with objective findings and a clinical picture. Our patient developed changes in the CBC and bone marrow 7 months after the initial symptoms, and in about 1 month, the diagnosis of EMS was already made. In isolated EMS cases, bone marrow involvement is observed within 2 years (2, 7). Immunohistochemistry testing remains essential for making the right diagnosis of EMS (1, 5). Hence, the most common positive markers include CD68, CD34, CD43, lysozyme, etc. (1, 2, 4, 6, 7), which showed to be positive (CD34 and CD68) in the lymph node biopsy in our case. Talking about the prognosis, there are no particular studies with a comprehensive analysis of the prognosis and survival rate of EMS patients. To summarize all the data, the overall prognosis is poor (1, 2). Life expectancy according to different data sources (2, 6) is about 2 years. There are some studies reporting on patients with a life expectancy of more than 5 years (2). The most important factors that seem to have the greatest influence on overall survival include the character of the disease, i.e., whether it is an isolated EMS or diagnosed after the manifestation of AML (1, 2), timely diagnosis (6), and management (6, 7, 9, 10). It has been reported that the location as well as the histotype of EMS had no influence on the median survival rate (6). Most of the data suggest an isolated EMS to be a better prognostic factor (1), but in our case, the progression of the symptoms was very unusual, the clinical course was very vague, and the diagnosis was a real challenge; therefore, even with empirical chemotherapy, the pathology was progressing and led to a lethal outcome. Moreover, the mediastinum includes various important anatomical structures (the great veins, extrapericardial aorta and its branches, heart, trachea, esophagus, vagus nerves, etc.); thus, any mediastinal pathology should be taken into consideration since the symptoms do not always represent the severity of the disease. As shown in our case, the teenager presented with not pronounced, not even specific symptoms, but they subsequently led to complicated procedures. As mentioned before, treatment strategy is one of the factors having an impact on disease prognosis and survival. There is neither a specific treatment consensus nor a specific type of a chemotherapeutic regimen for an isolated EMS overall (1, 2, 6, 7, 9, 10). Most of the data suggest the AML induction therapy to be effective for EMS (1, 2, 9), while radiotherapy has been reported not to be effective comparing 2 study groups with chemotherapy alone and in combination with radiotherapy (1), but the localization of sarcoma is also significant when choosing therapy methods (2). One study showed patients who received a myeloablative allogeneic bone marrow transplant (AlloBMT) to have a better prognosis compared with those who

received a bone marrow transplant (6). In our case, there was no discussion about radiotherapy or All-BMT due to the patient's general condition with the concomitant pathologies he developed, although the effect of chemotherapy given was limited.

Concluding Remarks

Mediastinal myeloid sarcoma is a very rare form of myelogenous leukemia. As shown in our case, its presentation can be various, even mimicking allergic/nonallergic asthma. Thus, every seeming asthmatic child/teenager with the progression of the dis-

ease and atypical, bizarre signs should undergo more complete investigations, including a simple chest x-ray. Every specialist should be aware of SVCS, which could lead to further tests and could suggest malignant pathology, even if this syndrome is another rare disorder in children. As EMS is uncommon and no concrete treatment options are given, the international consensus on the management of EMS as well as an isolated EMS could be a recommendation.

Statement of Conflicts of Interest

The authors state no conflict of interest.

References

1. Avni B, Koren-Michkowitz M. Myeloid sarcoma: current approach and therapeutic options. *Ther Adv Hem* 2011; 2(5):309-16.
2. Kim SC, Natarajan-Ame S, Lioure B, Chenard MP, Duclos B, Herbrecht R, et al. Successful treatment of a granulocytic sarcoma of the uterine cervix in complete remission at six-year follow-up. *J Oncol* 2010;2010:1-3.
3. Nounou R, Al-Zahrani HH, Ajarim DS, Martin J, Iqbal A, Naufal R, et al. Extramedullary myeloid cell tumours localised to the mediastinum: a rare clinicopathological entity with unique karyotypic features. *J Clin Pathol* 2002;55(3):221-5.
4. Makis W, Hickeson M, Derbekyan V. Myeloid sarcoma presenting as an anterior mediastinal mass invading the pericardium: serial imaging with F-18 FDG PET/CT. *Clin Nucl Med* 2010;35(9):706-9.
5. Pullarkat V, Veliz L, Chang K, Mahrbacher A, Teotico AL, Forman SJ, et al. Therapy-related, mixed-lineage leukaemia translocation-positive, monoblastic myeloid sarcoma of the uterus. *J Clin Pathol* 2007;60(5):562-4.
6. Al-Khateeb H, Badheeb A, Haddad H, Marei L, Abbasi S. Myeloid sarcoma: clinicopathologic, cytogenetic, and outcome analysis of 21 adult patients. *Leuk Res Treatment* 2011;2011:523168.
7. Park HJ, Jeong DH, Song HG, Lee GK, Han GS, Cha SH, et al. Myeloid sarcoma of both kidneys, the brain, and multiple bones in a nonleukemic child. *Yonsei Med J* 2003;44(4): 740-3.
8. Global Initiative for Asthma (GINA). Global strategy for asthma management and prevention. Bethesda (MD): Global Initiative for Asthma (GINA); 2010. p. 103.
9. Tsimberidou AM, Kantarjian HM, Wen S, Keating MJ, O'Brien S, Brandt M, et al. Myeloid sarcoma is associated with superior event-free survival and overall survival compared with acute myeloid leukemia. *Cancer* 2008;113(6): 1370-8.
10. Yamauchi K, Yasuda M. Comparison in treatments of nonleukemic granulocytic sarcoma: report of two cases and a review of 72 cases in the literature. *Cancer* 2002;94(6): 1739-46.

Received 4 October 2012, accepted 28 February 2013