

Two Unusual Clinical Presentations of Broad-Ligament Leiomyomas: A Report of Two Cases

Pınar Yıldız¹, Hüseyin Cengiz², Gazi Yıldız¹, Aslı Demir Şam³, Ali Yavuzcan¹, Bilal Çelikbaş⁴, Levent Şahin⁵

¹Department of Obstetrics and Gynecology, Bucak State Hospital, Burdur,

²Department of Obstetrics and Gynecology, Bakırköy Dr. Sadi Konuk Teaching and Research Hospital, Istanbul,

³Department of Pathology, Bucak State Hospital, Burdur, ⁴Department of Surgery, Bucak State Hospital, Burdur,

⁵Department of Obstetrics and Gynecology, Anadolu Hospital, Antalya, Turkey

Key words: broad ligament; leiomyoma.

Summary. We report on two unusual clinical presentations of broad-ligament leiomyomas. The first case was a combination of broad-ligament leiomyoma and ectopic gestational sac at the same location. The other case was a broad-ligament leiomyoma presenting as an ovarian malignancy. The differential diagnosis of broad-ligament leiomyoma should be considered in cases of an adnexal mass. Additionally, a broad-ligament leiomyoma could be the reason for an ectopic pregnancy.

Introduction

The broad ligament is a peritoneal fold that attaches the uterus, fallopian tubes, and ovaries to the pelvic sidewall. Disorders of the broad ligament are rare. Tumors of the broad ligament are also uncommon. Leiomyoma is the most common solid tumor of the broad ligament. However, leiomyoma is the most common benign tumor of the uterus and the most common female genital neoplasm. Leiomyomas affect 30% of all women of reproductive age (1), but the incidence of broad-ligament leiomyoma is <1%. Leiomyomas can arise from any tissue, such as the uterus, that contains smooth muscle cells that can invade the broad ligament; leiomyomas can also originate from the broad ligament itself (2). These benign tumors are usually asymptomatic. We report two unusual clinical presentations of broad-ligament leiomyomas. The first case was a combination of broad-ligament leiomyoma and ectopic gestational sac at the same location. The other case was a broad-ligament leiomyoma presenting as an ovarian malignancy.

Case 1

A 19-year-old nulligravida woman presented with spotting after 5 weeks of amenorrhea. Transvaginal pelvic ultrasonography (US) showed a 1.4-cm ring structure at the right adnexal region. Additionally, a solid, homogenous mass of about 5×5 cm was near the sac. The endometrial thickness was 16.5 mm. Free fluid was found in the pouch of Douglas. No intrauterine gestational sac was noted on the scan (Fig. 1). The patient's first serum β -human chorionic gonadotropin (hCG) level was 9863.76 IU/L; the second β -hCG level increased to

12 992.41 IU/L after 48 hours. A repeat transvaginal pelvic US showed similar findings after 48 hours. An exploratory laparotomy was performed, with a preoperative diagnosis of an ectopic pregnancy with a solid adnexal mass of unknown origin. A gestational sac was seen at the ampullar part of the right tuba uterina perioperatively, and a solid 5×5×4-cm semimobile mass was observed just under the gestational sac. Both ovaries were within normal dimensions and structure. No connection was observed among the uterus, the ovary, and the mass. The ectopic gestational sac and mass were completely excised with the ampullar segment of the uterine tubes. An evaluation of the mass revealed a leiomyoma originating from the right broad ligament. Trophoblastic invasion was also seen (Fig. 2). Histopathology of the specimen showed smooth muscle with an implantation reaction and chorionic villi. Postoperative recovery of the patient was uneventful, and her β -hCG level was undetectable at the 3-week follow-up.

Case 2

A 42-year-old secundipara woman was admitted to our hospital with metrorrhagia. Minimal abdominal tenderness was noted in the left lower quadrant during examination. Examination by vaginal speculum revealed minimal vaginal bleeding. A bimanual pelvic examination revealed a large, immobile, 8×7-cm lobulated mass in the left adnexal region. A clinical diagnosis of a malignant ovarian tumor was made. The serum levels of cancer antigen (CA)-125 and CA-19-9 were 57.9 and 10.33 U/mL, respectively. US showed an 8×7-cm solid mass at the left adnexal region. Ascites were not detected. Magnetic resonance imaging of the abdomen also suggested a solid homogenous mass at the right adnexa. The liver and kidneys were normal, and no ascites or

Correspondence to A. Yavuzcan, Department of Obstetrics and Gynecology, Bucak State Hospital, Burdur, 15300 Bucak/Burdur, Turkey. E-mail: draliyavuzcan@yahoo.com

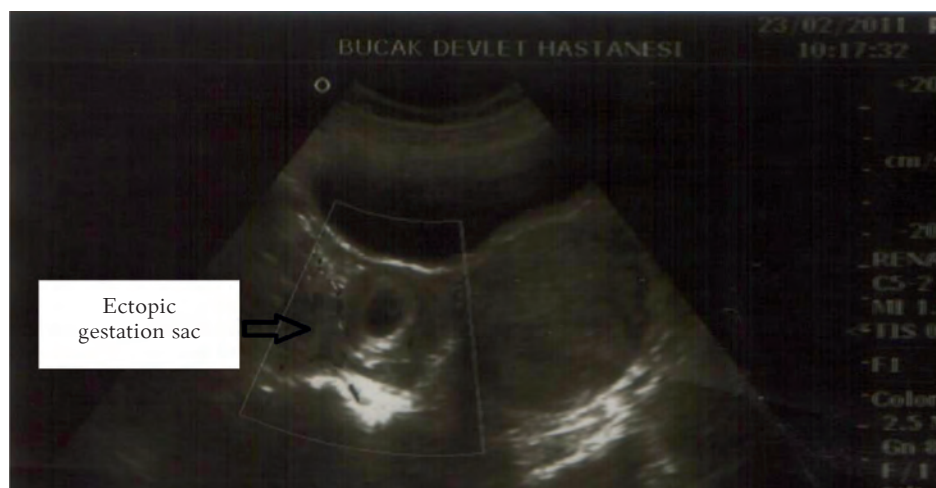


Fig. 1. Preoperative transvaginal pelvic ultrasonography view

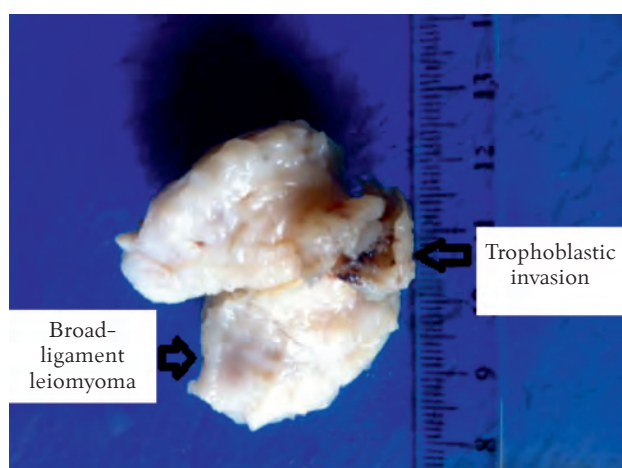


Fig. 2. Macroscopic view of the broad-ligament leiomyoma with trophoblastic invasion

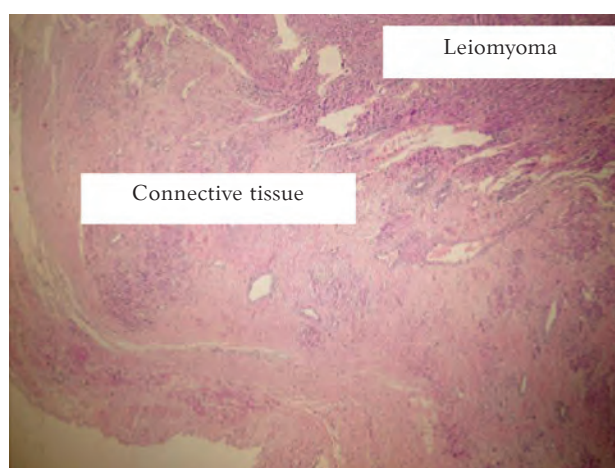


Fig. 3. Microscopic view of the leiomyoma and connective tissue belonging to the broad ligament
Hematoxylin and eosin, $\times 4$.

para-aortic or iliac lymphadenopathy was noted. The endometrial biopsy result was consistent with a secretory endometrium. An exploratory laparotomy was performed, with a preoperative diagnosis of a solid adnexal mass suggesting an ovarian malignancy, given the elevated CA-125 level and the solid nature of the mass. An 8×4×8-cm solid mass originating from the broad ligament and very close to the left ovary was found intraoperatively. Both ovaries were within normal dimensions and structure. No connection among the uterus, left ovary, and the mass was found. An examination of the mass arising from the left broad ligament indicated that it was a leiomyoma. The patient underwent a total abdominal hysterectomy and unilateral salpingo-oophorectomy. The final pathological examination revealed a leiomyoma without mitotic figures, nuclear atypia, or pleomorphism, but the mass showed an immunohistochemical reaction to desmin. Histopathology of the specimen showed leiomyomatosis within

the loose connective tissue and blood vessels of the broad ligament (Fig. 3). The patient was discharged 3 days after surgery following an uneventful postoperative course, and she was clinically asymptomatic 3 months after surgery.

Discussion

Many women develop leiomyomas as they grow older. In one study, the prevalence of US-identified tumors ranged from 4% in women aged 20–30 years to 11%–18% in women aged 30–40 years and 33% in women aged 40–60 years (3). Women often consult family physicians due to symptoms related to leiomyomas or after the lesions are diagnosed incidentally during physical or radiological examinations. The most common presentations of leiomyomas are menstrual disturbances and dysmenorrhea. Broad-ligament leiomyomas are usually asymptomatic. However, these lesions can present with pressure symptoms, such as bladder and bowel

dysfunction. If a broad-ligament leiomyoma reaches a significant size, it can distort the anatomy of the pelvis, pushing the uterus to the contralateral side, and it can potentially compress the ureter, which leads to hydronephrosis (2).

An ectopic pregnancy is defined as a pregnancy implanted outside the uterine cavity, and >98% of ectopic pregnancies implant in the fallopian tube. Approximately 1%–2% of all pregnancies in Europe and the United States are ectopic, and tubal ectopic pregnancy remains the most common cause of maternal mortality in the first trimester of pregnancy in the Western world. The major risk factors for a tubal ectopic pregnancy include tubal damage as a result of surgery or infection (particularly *Chlamydia trachomatis*), smoking, and in vitro fertilization (4). Current data addressing the underlying cause of tubal ectopic pregnancy are mostly descriptive. However, these data support the hypothesis that an ectopic pregnancy is caused by a combination of (i) retention of the embryo within the fallopian tube due to impaired embryo-tubal transport and (ii) alterations in the tubal environment allowing early implantation to occur (5). Our patients did not report a history of surgery, infection, or any other risk factor. However, a broad-ligament leiomyoma was found just under the ampullar segment of tuba. Embryo-tubal transport was probably interrupted by this lesion. A broad-ligament leiomyoma causing obstruction of the tuba uterina is a fairly rare condition.

A preoperative disease classification for patients with adnexal masses, in particular discrimination between benign and malignant ovarian tumors, is important for optimal patient management. At present, it is unclear whether a subjective evaluation of a US image (i.e., pattern recognition) of an adnexal (i.e., ovarian, paraovarian, or tubal) mass or determining serum CA-125 levels is the best method to distinguish benign from malignant tumors (6). CA-125 is a glycoprotein that is assessed by the monoclonal antibody OC 125. An elevated CA-125 serum level of at least 30 U/mL often indicates the presence of

malignancy (7). Few studies have focused on CA-125 serum levels in women with benign adnexal tumors. However, the level of serum CA-125 is often elevated in women with endometriosis or endometriomas. Jacobs and Bast found that CA-125 serum levels exceeded 35 U/mL in approximately 10% of women with benign tumors and in a higher percentage of women with serous benign tumors than among those with cystic teratomas (8). A patient's age and menopausal status are important factors to consider when identifying an adnexal abnormality, as the associated risk of malignancy increases from 13% in premenopausal women to 45% in postmenopausal women (9). Although nearly all women diagnosed with ovarian carcinoma initially present with an adnexal mass, only a small proportion of all masses detected are malignant, and the expeditious triage of these patients is the most important component of their treatment regimen. However, a broad-ligament leiomyoma is not involved in the differential diagnosis of an adnexal mass. Gardner et al. proposed the definition of broad-ligament tumors, requiring that they "occur in or on the broad ligament, but are completely separated from and in no way connected with either the uterus or the ovary" (10). In our case, a broad-ligament leiomyoma was present with a preoperative diagnosis of a solid adnexal mass suggesting ovarian malignancy given the elevated CA-125 level and the solid nature of the mass. Intraoperatively, there was no connection among the uterus, the left ovary, and the mass.

Conclusions

In conclusion, we reported two cases of leiomyoma in the broad ligament of two adult women. The differential diagnosis of broad-ligament leiomyoma should be considered in cases of an adnexal mass. Furthermore, a broad-ligament leiomyoma could be the reason for an ectopic pregnancy.

Statement of Conflict of Interest

The authors state no conflict of interest.

References

1. Parker WH. Uterine myomas: an overview of development, clinical features, and management. *Obstet Gynecol* 2005;105:216–7.
2. Bardawil T, Chelmsow D. Broad ligament disorders. Medscape Reference. Updated 5 March 2011. Available from: URL: <http://emedicine.medscape.com/article/275773-overview#aw2aab6b3>
3. Lurie S, Piper I, Woliovitch I, Glezerman M. Age-related prevalence of sonographically confirmed uterine myomas. *J Obstet Gynaecol* 2005;25:42–4.
4. Varma R, Gupta J. Tubal ectopic pregnancy. *Clin Evid (Online)* 2009;20:1406.
5. Shaw JL, Dey SK, Critchley HO, Horne AW. Current knowledge of the aetiology of human tubal ectopic pregnancy. *Hum Reprod Update* 2010;16:432–44.
6. Van Calster B, Timmerman D, Bourne T, Testa AC, Van Holsbeke C, Domali E, et al. Discrimination between benign and malignant adnexal masses by specialist ultrasound examination versus serum CA-125. *J Natl Cancer Inst* 2007;99:1706–14.
7. Paramasivam S, Tripcony L, Crandon A, Quinn M, Hammond I, Marsden D, et al. Prognostic importance of preoperative CA 125 in International Federation of Gynecology and Obstetrics stage I epithelial ovarian cancer: an Australian multicenter study. *J Clin Oncol* 2005;23:5938–42.
8. Jacobs I, Bast RC Jr. The CA 125 tumour-associated antigen: a review of the literature. *Hum Reprod* 1989;4:1–12.
9. Drake J. Diagnosis and management of the adnexal mass. *Am Fam Physician* 1998;57:2471–6.
10. Gardner GH, Greene RR, Peckham R. Tumors of the broad ligament. *Am J Obstet Gynecol* 1957;73:536–55.

Received 13 November 2011, accepted 10 April 2012