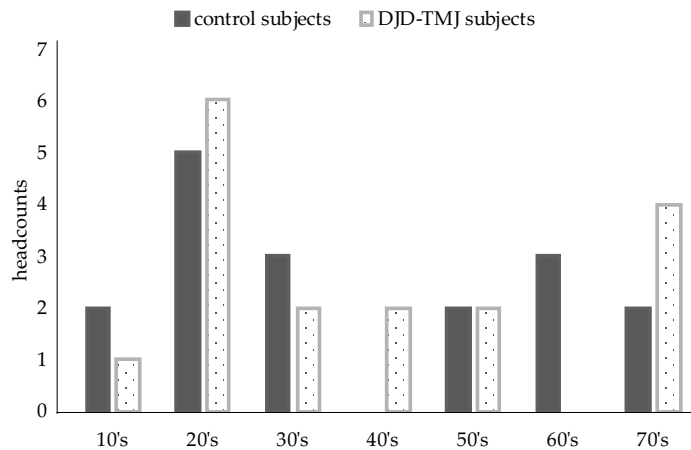


### Supplementary Figure S1

Age distribution of all DJD-TMJ and control subjects.



### Supplementary Figure S2

Frontal view of panoramic radiograph of another representative DJD-TMJ patient than those shown in Figure 8. The letter "R" indicates right side. The bilateral resorptions of mandibular heads are indicated by arrows. Note that the right mandibular head is more severely damaged.

