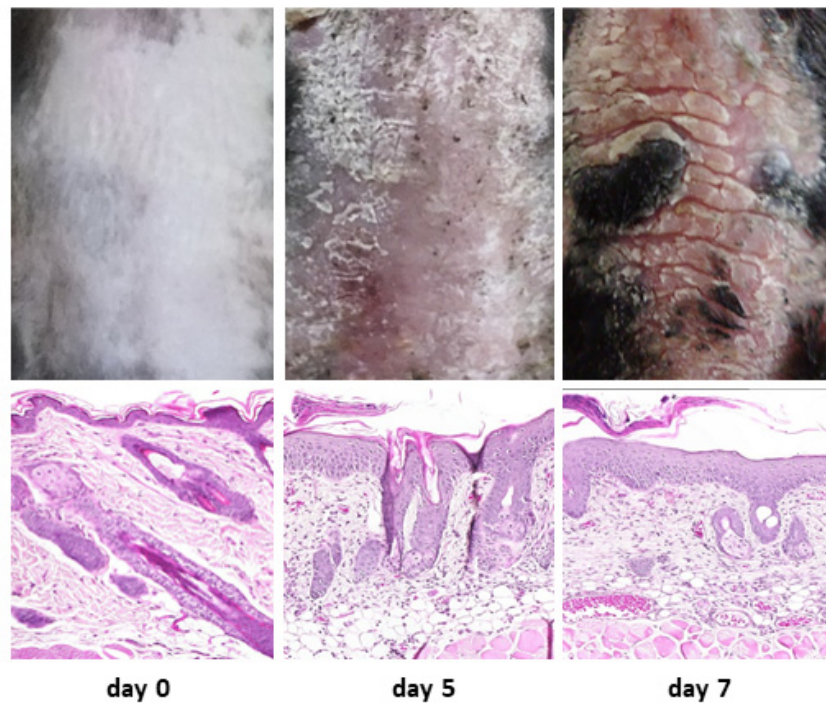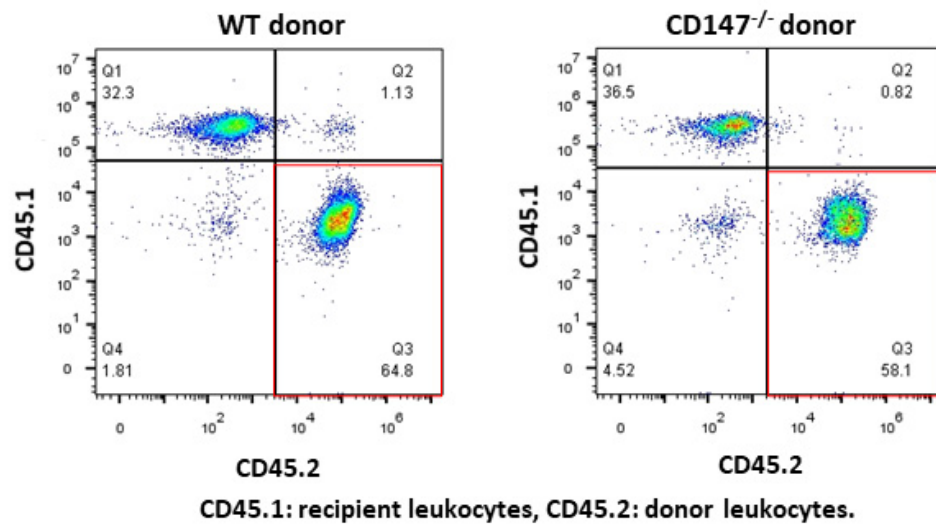


**Figure S1.** Induction of psoriatic lesions by imiquimod in psoriasis model mice. The 7-day application of 62.5 mg of 5% IMQ cream to the shaved back of mice induced psoriatic lesions with hyper-parakeratosis, acanthosis, and dermal infiltration of inflammatory cells.



**Figure S2.** The donor bone marrow chimeric mice lacked CD147 hematopoietic cells of myeloid lineage. In the recipient mice, successfully engrafted donor myeloid cells were 64.8% from WT donor mice and 58.1% from CD147<sup>-/-</sup> mice.