

Supplementary Figure legends

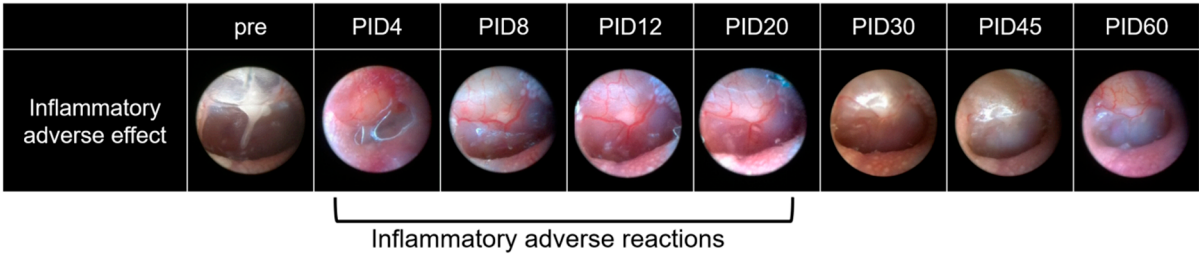


Figure S1. Typical endoscopy findings indicating inflammatory adverse reactions after dual-vehicle injection. Bulging of the pars flaccida and erythematous change of the tympanic membrane were identified between post-injection day (PID) 4 and 20, which slowly recovered after PID30.

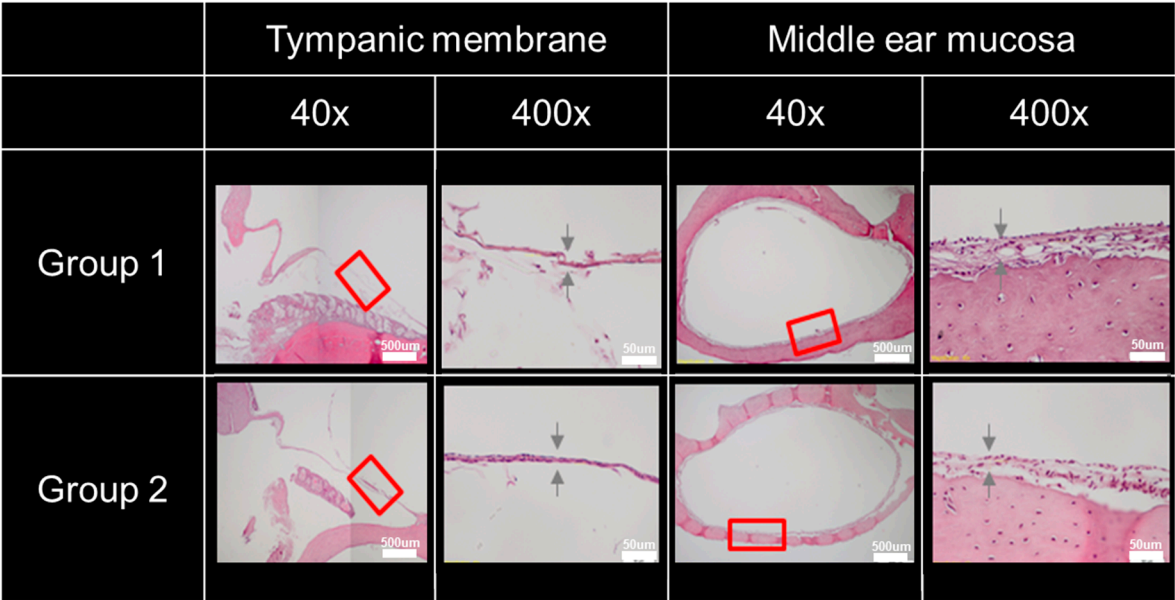


Figure S2. Histopathology of the tympanic membrane (TM) and middle ear mucosa. There were no differences in the TM and mucosa at the base of the bulla between groups 1 and 2. The thickness of the TM was $12.4 \pm 14.9 \mu\text{m}$ in group 1 and $13.3 \pm 12.8 \mu\text{m}$ in group 2. The thickness of the mucosa at the base of the bulla was $22.3 \pm 7.3 \mu\text{m}$ in group 1 and $24.0 \pm 16.0 \mu\text{m}$ in group 2.