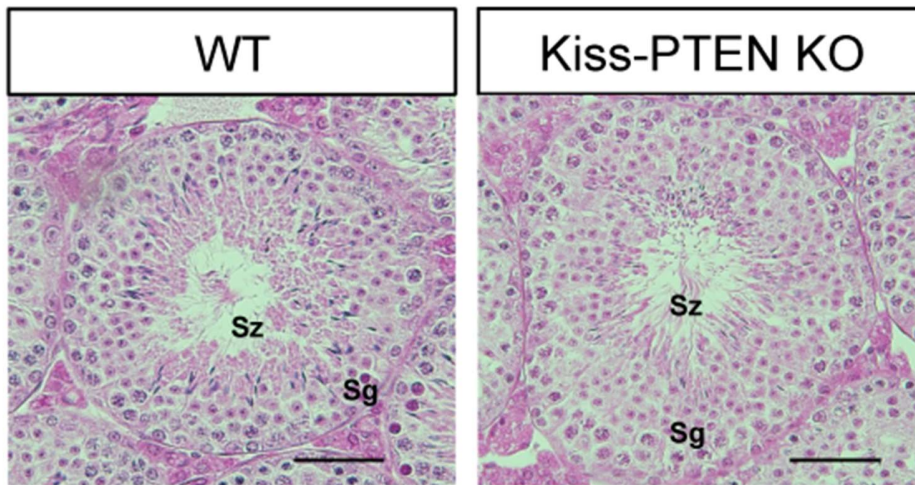
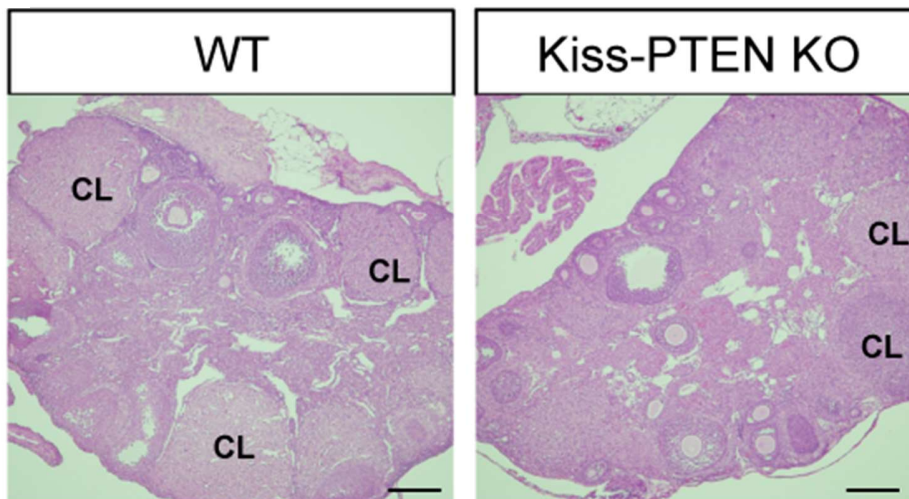


A.



B.



Supp. Fig. 1. (A) Representative photomicrographs of adult WT and Kiss-PTEN KO testicular tissue (cross-section) showing normal seminiferous tubules and spermatogenic cells (Sg, spermatogonia; Sz, spermatozoa). (B) Representative photomicrographs of adult WT and Kiss-PTEN KO ovaries (CL, corpus luteum). Scale bars: (A) = 50 μ m; (B) = 200 μ m.