

*Case Report*

# Claudication-Like Vision Impairment from Spontaneous Dissection of Internal Carotid Artery

**Bo-Yang Ni** <sup>1,2</sup> and **Yaw-Tsan Ho** <sup>1,\*</sup>

<sup>1</sup> Department of Emergency Medicine, Taipei Tzu Chi Hospital, Buddhist Tzu Chi Medical Foundation, New Taipei 231, Taiwan; tcutcu59@livemail.tw

<sup>2</sup> Department of Emergency Medicine, School of Medicine, Tzu Chi University, Hualien 970, Taiwan

\* Correspondence: yth471105@tzuchi.com.tw; Tel.: +886-2-6628-9779; Fax: +886-2-6628-9009

Received: 30 March 2018; Accepted: 14 May 2018; Published: 16 May 2018



**Abstract:** Among young adults, a carotid artery dissection is one of the etiologies of morbidity. In the general population, the incidence of stroke due to dissection is around 2.5%, whereas a carotid dissection accounts for 19.5% of ischemic stroke in young adults. This could be due to injury or spontaneity, with the etiology controlled by several factors. A carotid artery dissection is a separation of arterial layers, which results in a tear in the arterial wall, causing invasion of blood into the wall of artery and leading to intra-luminal stenosis or aneurysmal dilatation. We describe a patient presented with claudication-like vision impairment. The image studies revealed spontaneous internal carotid artery dissection with severe occluded left internal carotid artery. With medical therapy with antiplatelets and anticoagulants, she was managed successfully with endovascular stenting with good neurological recovery to date. We also reviewed current reported studies of the dissection of the petrous portion of the internal carotid artery in Medline from 1960 to the present.

**Keywords:** carotid artery dissection; vision change

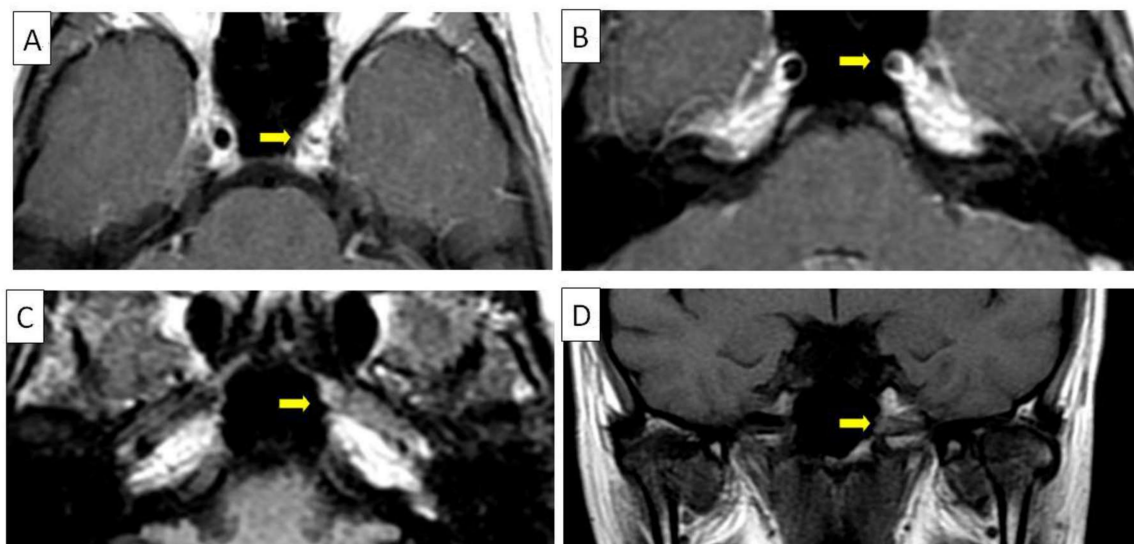
## 1. Introduction

Spontaneous carotid artery dissection is a common cause of ischemic stroke in young adults. One-fifth of young adults with ischemic stroke suffered this due to carotid artery dissection [1]. This creates a potential space between the intima tear, and results in stenosis or aneurysm [2]. Nevertheless, the main cause of ischemic events is thought to be thromboembolism instead of low perfusion [3]. Thus, antiplatelets and anticoagulation remain standard therapy for carotid artery dissection [4]. In addition, there are a number of case reports documenting the efficacy of endovascular therapy to restore perfusion in patients with moderate–severe stenosis or occlusion in the location of carotid artery dissection [5–8]. This paper describes a patient who presented with claudication-like vision impairment and was diagnosed via image studies. After medical therapy with antiplatelets and anticoagulants, she was managed successfully with good neurological recovery to date. We also analyzed current reported studies of the dissection of the petrous portion of the internal carotid artery in Medline from 1960 to the present and highlighted early diagnosis and timely intervention for improving neurological outcome.

## 2. Case Report

A 37-year-old healthy Taiwanese female beauty artist had sudden blurred vision in the left eye when eating dinner without weakness, neck pain or headache. She had been to the local hospital. The retinal, eye field, and eye acuity examination were called negative by the ophthalmologist in the local hospital. Optic neuritis was then suspected. Two days later, the blurred vision improved. However, the more distance she walked, the more her vision blurred. In the end, she could only sense

light in her left eye. After rest, the blur vision resolved. Three days after the first event, she was awakened by occipital headache and her vision blurred again. Thus, she went to our emergency department, and neurologic examinations revealed pupil light reflex +/+, +/+, 3 mm/OU, no ptosis, no limb weakness, no facial palsy or slurred speech, the finger-nose-finger test intact, and visual field intact determined by the neurologist. Our ophthalmologist confirmed the negative result of the retinal examination (no disc swelling). The best-corrected visual acuity was 6/6 OD, 6/120 OS. She had no recent trauma history, even massage. There was no remarkable history in her family. The laboratory results showed no significant abnormality, including normal coagulation. All fibrinogen, prothrombin time (10.6 s, normal range 8.0–12.0 s, INR 1.01), partial thromboplastin time (28.5 s, normal range 23.9–35.5 s), D-dimer, leukocyte, erythrocyte, hemoglobin, and platelet counts were within normal ranges. There was no significant abnormality in the computed tomography of the brain. After rest, all her symptoms entirely resolved. The results of a chest X-ray and electrocardiography were negative. Due to persistent claudication-like visual impairment and no evidence of ophthalmologic problem or intracranial hemorrhage, cerebrovascular disease was a concern. Magnetic resonance angiography showed severe stenosis in the left petrous internal carotid artery and right proximal A1 and decreased branches of the left middle cerebral artery (MCA) (Figure 1). There was no evidence of acute infarction. Heparin and aspirin were prescribed. During hospitalization, duplex ultrasonography disclosed a high resistant decreased flow in the left cervical internal carotid artery with a reversed left ophthalmic arterial flow, suggesting a distal internal carotid artery tight stenosis or occlusion. The carotid angiography showed a segmental critical stenosis of the left distal internal carotid artery (horizontal petrous portion) with contrast stasis within false lumen, which may be secondary to dissection. Thoracic aortography showed a type I aortic arch and no critical stenosis of bilateral proximal carotid and vertebral arteries. The stent was performed, and post-stenting left carotid angiograms showed the patency of left internal carotid artery without residual stenosis. Four days after discharge, there was no more visual change. The next follow-up ultrasonography was arranged for 3 months later. Oral informed consent was obtained from the patient.



**Figure 1.** (A) An axial image discloses a thrombus in the pseudo-lumen in the left internal carotid artery (arrow); (B) another axial image revealed the pseudo-lumen in the left internal carotid artery (arrow); (C) intimal dissection with irregular wall thickening in the horizontal portion of left intrapetrous internal carotid artery (arrow); (D) a coronal image showed the wall thickening in the horizontal portion of left intrapetrous internal carotid artery (arrow).

### 3. Discussion

Medline was used to review cases of intrapetrous internal carotid artery dissection reported since 1960. Search keywords were “spontaneous”, “dissection” or “dissecting”, “intrapetrous” or “petrous” and “internal carotid artery”. Thirteen patients with spontaneous intrapetrous internal carotid artery dissection were identified in the English-language literature [9–19]. In total, 13 patients, including this patient, are reviewed in this report (Table 1). The mean patient age was  $43.8 \pm 11.4$  (range 27–75) years. Then patients had one-sided headache. Only four patients had an ischemic stroke. Anticoagulants were prescribed to 11 patients and aspirin for two. All seven patients who received a follow-up image showed recanalization. Clinical symptoms recovered satisfactorily in 12 cases; two patients had persistent partial Horner’s syndrome; one patient died due to massive subarachnoid hemorrhage. Dissection confined to the petrous internal carotid artery is rare, which is probably due to the immobility of the petrous portion fixed in the carotid canal. [14] The symptoms could only be presented with headaches without other neurologic deficit, whereas others had partial Horner’s sign (miosis, ptosis without anhidrosis) or ischemia-related symptoms. Diagnosis could be elusive. Dissections of the intracranial internal carotid artery, especially at the supraclinoid portion, usually caused infarcts in reported cases [18,20]. However, only 4 of 13 reported cases with intrapetrous dissection had cerebral infarct.

**Table 1.** Clinical profiles of intrapetrous internal carotid artery dissection in 13 patients.

	Age/Sex	Clinical Symptoms	Stroke	Diagnosis Methods	Therapy	Outcome	Recanalization	Reference
1	43/F	Partial Horner’s syndrome	NA	Angiography	C	Persisted	NA	[9]
2	34/F	Headache, transient blurred vision and paresthesia	No	MRI, Doppler, Angiography	C	Recovered	3 months	[10]
3	41/F	Headache, and partial Horner’s syndrome	No	MRI, Doppler	C	Recovered	2 months	[11]
4	42/M	Headaches, and pulsatile tinnitus	No	Angiography	C	Recovered	NA	[12]
5	42/M	Headache, limb-weakness and numbness	Temporoparietal infarct	Angiography	C	Recovered	NA	[12]
6	47/F	Orbital pain	no	MRI/MRA, Doppler	C	Recovered	2.5 months	[13]
7	42/M	Headaches, limb-weakness and cortical dysfunction	Borderzone infarct	MRI/MRA, Doppler	A	Recovered	2 months	[14]
8	38/F	Headache, neck pain, and partial Horner’s syndrome	No	MRI, Angiography	A	Persisted	4 months	[15]
9	52/M	Headache	No	MRI/MRA, Angiography	C	Recovered	1 month	[16]
10	75/M	Limb-weakness and difficult speech	Left basal ganglia	MRI/MRA, SPECT	Stent	Recovered	3 months	[17]
11	27/M	Limb-weakness	Right basal ganglia	MRI, Angiography	Bypass	Recovered	Bypass	[18]
12	49/F	Headache, eye pain, nausea and Horner’s syndrome	NA	MRI/MRA, Angiography	C	Died	NA	[19]
13	37/F	Headache, Claudication-like visual change	No	MRI/MRA, Doppler Angiography,	Stent	Recovered	Not yet	this case

M = male; F = female; NA = not available from the literature review; A = aspirin; C = anticoagulant.

Treatment for patients with intracranial or intrapetrous internal carotid artery dissection remains controversial. No conclusive evidence exists confirming the benefit of carotid stenting in such patients. Most reviewed cases were treated with an anticoagulant and, in this case, aspirin, heparin and stenting; all seven patients who received follow-up study had spontaneous partial recanalization within 1–4 months after symptoms onset, and except one who died of massive SAH, all 12 patients improved without stroke recurrence. To date, there has been no case report of spontaneous petrous carotid artery dissection, documenting the symptom in our case: the claudication-like vision impairment. The intermittent claudication is defined as a reproducible discomfort of a defined group of muscles that is induced by exercise and relieved with rest. Although the supply of blood may be adequate to meet the demands of inactive muscle, a mismatch develops between the supply of blood and increased demand induced by activity. This mismatch may also lead to atypical lower extremity pain [21]. The cause is usually attributed to atherosclerosis and associated thrombosis in arteries, leading to stenosis and thus tissue ischemia. Our case presented claudication-like visual impairment, which was also due to stenosis, but the origin was artery dissection. This event was spontaneous for our patient. The etiology might be genetic, familial or heritable disease. However, her family history and occupation were not remarkable. She was otherwise healthy. Her etiology of the event may be idiopathic.

In summary, the classical manifestation of internal carotid artery dissection was unilateral headache accompanied by some ischemic symptoms (such as Horner syndrome, visual impairment, tinnitus, and limb-weakness). Thus, when some ischemic symptoms occur with one-sided headache, the internal carotid artery dissection should be considered. Intracranial carotid artery dissection could be fatal, but intrapetrous internal carotid artery dissection seems to be mild after adequate therapy such as anticoagulant, stenting, or bypass surgery.

**Author Contributions:** B.-Y.N. wrote the paper and contributed to the organization of figures; B.-Y.N. and Y.-T.H. provided conceptual input; Y.-T.H. proofread and organized the manuscript. All authors reviewed the final version of the manuscript.

**Conflicts of Interest:** The authors declare no conflict of interest.

## References

1. Provenzale, J.M. Dissection of the internal carotid and vertebral Arteries: Imaging features. *AJR Am. J. Roentgenol.* **1995**, *165*, 1099–1104. [[CrossRef](#)] [[PubMed](#)]
2. Thanvi, B.; Munshi, S.K.; Dawson, S.L.; Robinson, T.G. Carotid and vertebral artery dissection syndromes. *Postgrad. Med. J.* **2005**, *81*, 383–388. [[CrossRef](#)] [[PubMed](#)]
3. Morel, A.; Naggara, O.; Touzé, E. Mechanism of ischemic infarct in spontaneous cervical artery dissection. *Stroke* **2012**, *43*, 1354–1361. [[CrossRef](#)] [[PubMed](#)]
4. Lyrer, P.; Engelter, S. Antithrombotic drugs for carotid artery dissection. *Cochrane Database Syst. Rev.* **2010**, *35*, CD000255. [[CrossRef](#)] [[PubMed](#)]
5. Albuquerque, F.C.; Hu, Y.C.; Dashti, S.R.; Abla, A.A.; Clark, J.C.; Alkire, B.; Theodore, N.; McDougall, C.G. Craniocervical arterial dissections as sequelae of chiropractic manipulation: Patterns of injury and management. *J. Neurosurg.* **2011**, *115*, 1197–1205. [[CrossRef](#)] [[PubMed](#)]
6. Ansari, S.A.; Parmar, H.; Ibrahim, M.; Gemmete, J.J.; Gandhi, D. Cervical dissections: Diagnosis, management, and endovascular treatment. *Neuroimaging Clin. N Am.* **2009**, *19*, 257–270. [[CrossRef](#)] [[PubMed](#)]
7. Bosiers, M.; Callaert, J.; Deloose, K.; Verbist, J.; Keirse, K.; Peeters, P. The role of carotid artery stenting for recent cerebral ischemia. *J. Cardiovasc. Surg.* **2010**, *51*, 293–304.
8. Cerutti, D.; Bonafe, A.; Pelouze, G.A.; Kassem, Z.; Filipov, R.; Runavot, G.; Cassarini, J.F.; Sablot, D. Endovascular stent-assisted angioplasty after cervical arteries dissection. *Rev. Neurol.* **2010**, *166*, 333–336. (In French) [[CrossRef](#)] [[PubMed](#)]
9. Bilbao, R.; Amoros, S.; Murube, J. Horner syndrome as an isolated manifestation of an intrapetrous internal carotid artery dissection. *Am. J. Ophthalmol.* **1997**, *123*, 562–564. [[CrossRef](#)]

10. Robertson, D.I.; Stuckey, S.L. Isolated intrapetrous carotid canal atraumatic internal carotid artery dissection: MRI and digital subtraction angiography findings. *J. Med. Imaging Radiat. Oncol.* **2003**, *47*, 462–464. [[CrossRef](#)]
11. Mainardi, F.; Maggioni, F.; Dainese, F.; Amista, P.; Zanchin, G. Spontaneous carotid artery dissection with cluster-like headache. *Cephalalgia* **2002**, *22*, 557–559. [[CrossRef](#)] [[PubMed](#)]
12. Saeed, S.R.; Hinton, A.E.; Ramsden, R.T.; Lye, R.H. Spontaneous dissection of the intrapetrous internal carotid artery. *J. Laryngol. Otol.* **1990**, *104*, 491–493. [[CrossRef](#)] [[PubMed](#)]
13. Guillon, B.; Biousse, V.; Massiou, H.; Bousser, M.G. Orbital pain as an isolated sign of internal carotid artery dissection. A diagnostic pitfall. *Cephalalgia* **1998**, *18*, 222–224. [[CrossRef](#)] [[PubMed](#)]
14. Huang, Y.C.; Chen, C.M.; Lai, S.L.; Lee, T.H.; Chen, S.T.; Chin, S.C.; Chen, Y.C. Spontaneous intrapetrous internal carotid artery Dissection: A case report and literature review. *J. Neurol. Sci.* **2007**, *253*, 90–93. [[CrossRef](#)] [[PubMed](#)]
15. Selky, A.K.; Pascuzzi, R. Raeder’s paratrigenial syndrome due to spontaneous dissection of the cervical and petrous internal carotid artery. *J. Head Face Pain* **1995**, *35*, 432–434. [[CrossRef](#)]
16. Biggs, K.L.; Chiou, A.C.; Hagino, R.T.; Klucznik, R.P. Endovascular repair of a spontaneous carotid artery dissection with carotid stent and coils. *Vasc. Surg.* **2004**, *40*, 170–173. [[CrossRef](#)] [[PubMed](#)]
17. Imai, K.; Mori, T.; Izumoto, H.; Takabatake, N.; Kunieda, T.; Yamamoto, S.; Watanabe, W. Successful stenting seven days after atherothrombotic occlusion of the intracranial internal carotid artery. *J. Endovasc. Ther.* **2006**, *13*, 254–259. [[CrossRef](#)] [[PubMed](#)]
18. Nussbaum, E.S.; Janjua, T.M.; Defillo, A.; Lowary, J.L.; Nussbaum, L.A. Emergency extracranial-intracranial bypass surgery for acute ischemic stroke. *J. Neurosurg.* **2010**, *112*, 666–673. [[CrossRef](#)] [[PubMed](#)]
19. Le Reste, P.J.; Ferre, J.C.; Gauvrit, J.Y.; Morandi, X.; Hamlat, A. Spontaneous bilateral intrapetrous carotid dissection complicated by a ruptured dissecting aneurysm. *J. Neuroradiol.* **2010**, *38*, 193–195. [[CrossRef](#)] [[PubMed](#)]
20. Chaves, C.; Estol, C.; Esnaola, M.M.; Gorson, K.; O’Donoghue, M.; De Witt, L.D.; Caplan, R.L. Spontaneous intracranial internal carotid artery Dissection: Report of 10 patients. *Arch. Neurol.* **2002**, *59*, 977–981. [[CrossRef](#)] [[PubMed](#)]
21. Neschis, D.G.; Golden, M.A. *Clinical Features and Diagnosis of Lower Extremity Peripheral Artery Disease*; Uptodate: Waltham, MA, USA, 2017.



© 2018 by the authors. Licensee MDPI, Basel, Switzerland. This article is an open access article distributed under the terms and conditions of the Creative Commons Attribution (CC BY) license (<http://creativecommons.org/licenses/by/4.0/>).