

SUPPLEMENTARY MATERIAL

Figure S1. Example of co-registration of segmented ischemic core volume on CTP (red) and follow-up infarct volume on DWI (blue) projected on smoothened CTP CBV map (grey) in a case with moderate volumetric and spatial accuracy.

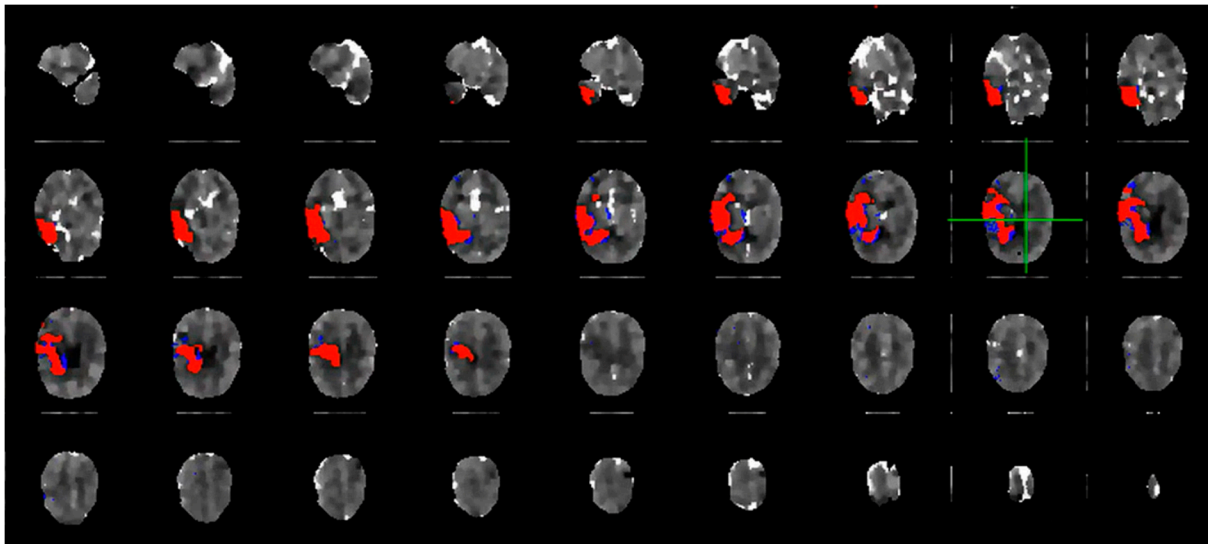


Figure S2. Flowchart of patient selection.

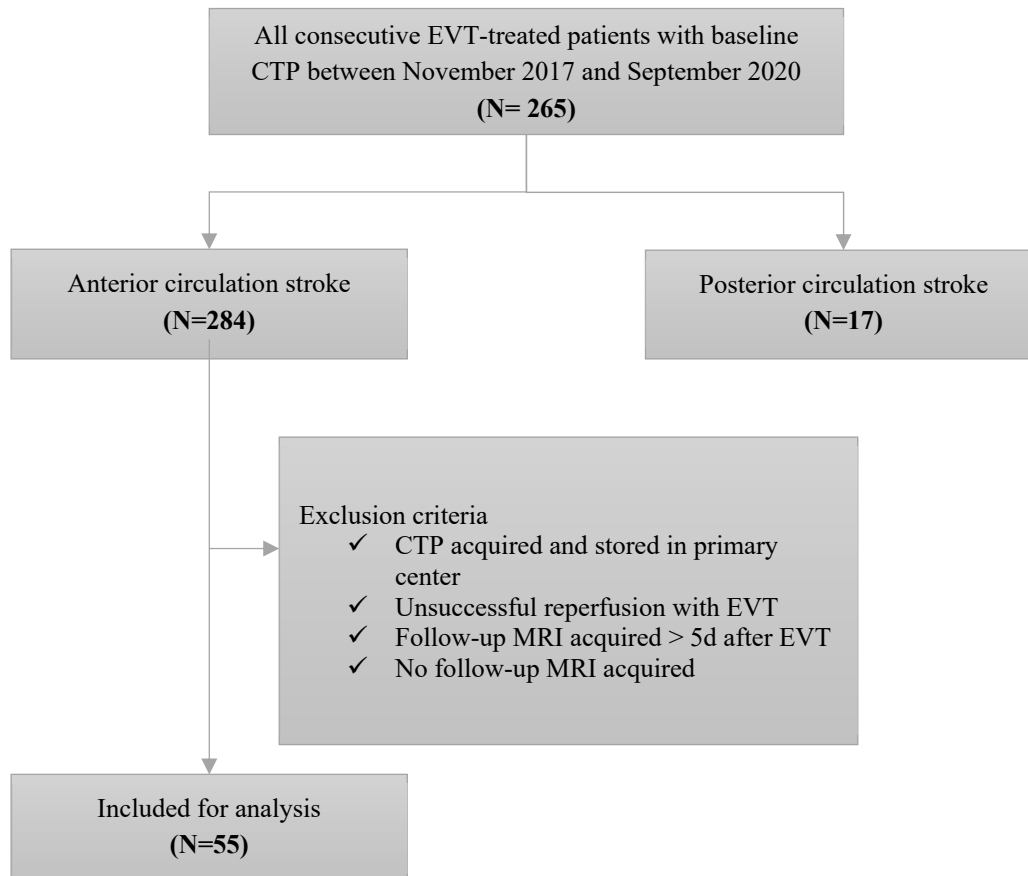


Figure S3. Scatter plots show the agreement between the estimated CTP ischemic core volume and the follow-up DWI infarct volume for (A) method 1, (B) method 2, (C) method 3 and method 4 (D). The dotted line represents the identity line. Points below this line indicate a larger CTP ischemic core volume compared to the follow-up DWI lesion, i.e. overestimation by CTP. Points above the identity line indicate underestimation by CTP or infarct growth between baseline and follow up imaging. CTP = CT perfusion; DWI = diffusion weighted imaging

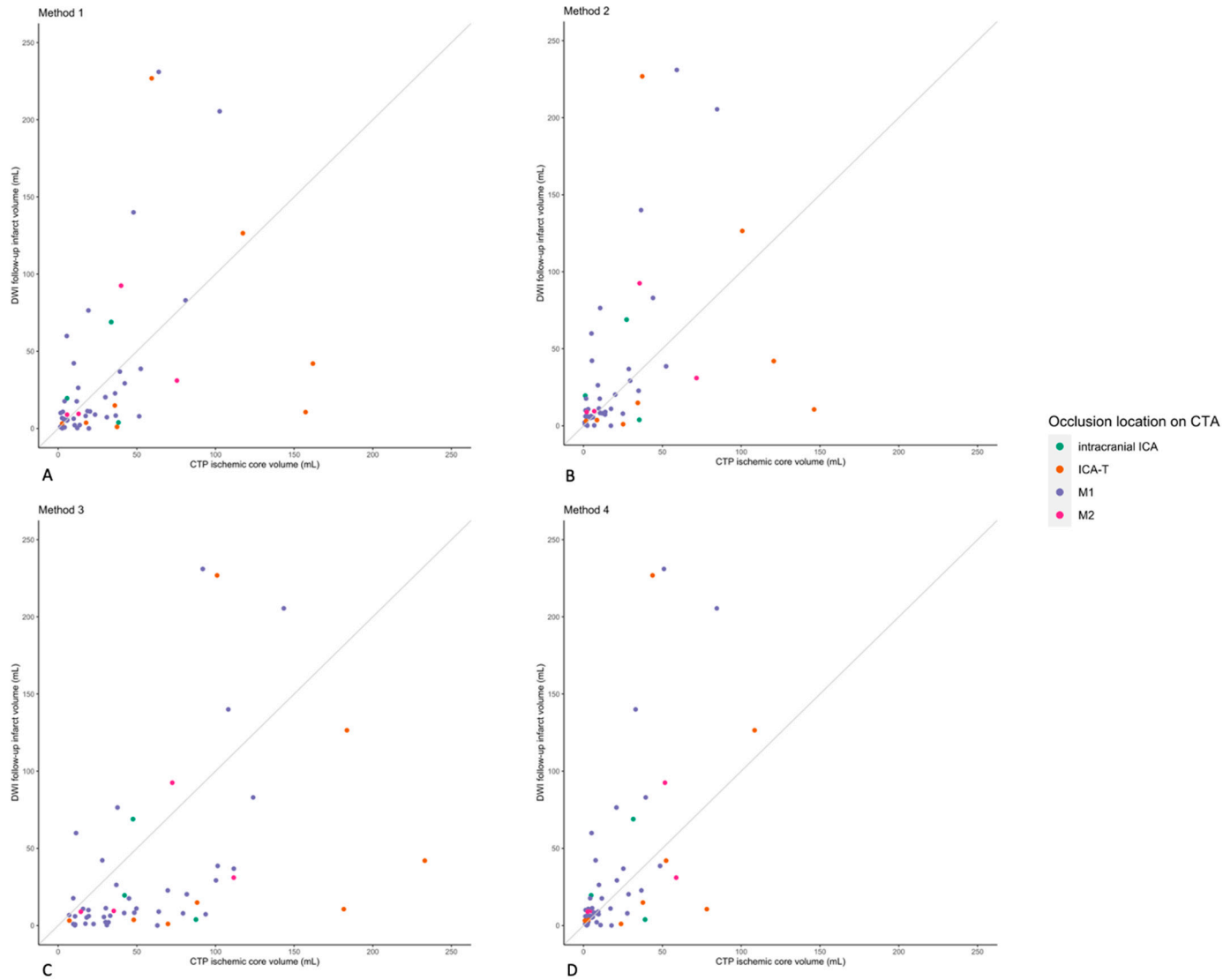


Figure S4. Boxplots of ischemic core overestimation per occlusion location. Boxplots represent median and interquartile range. Negative values represent overestimation of ischemic core.

