

Supplementary

Figures S1-S3

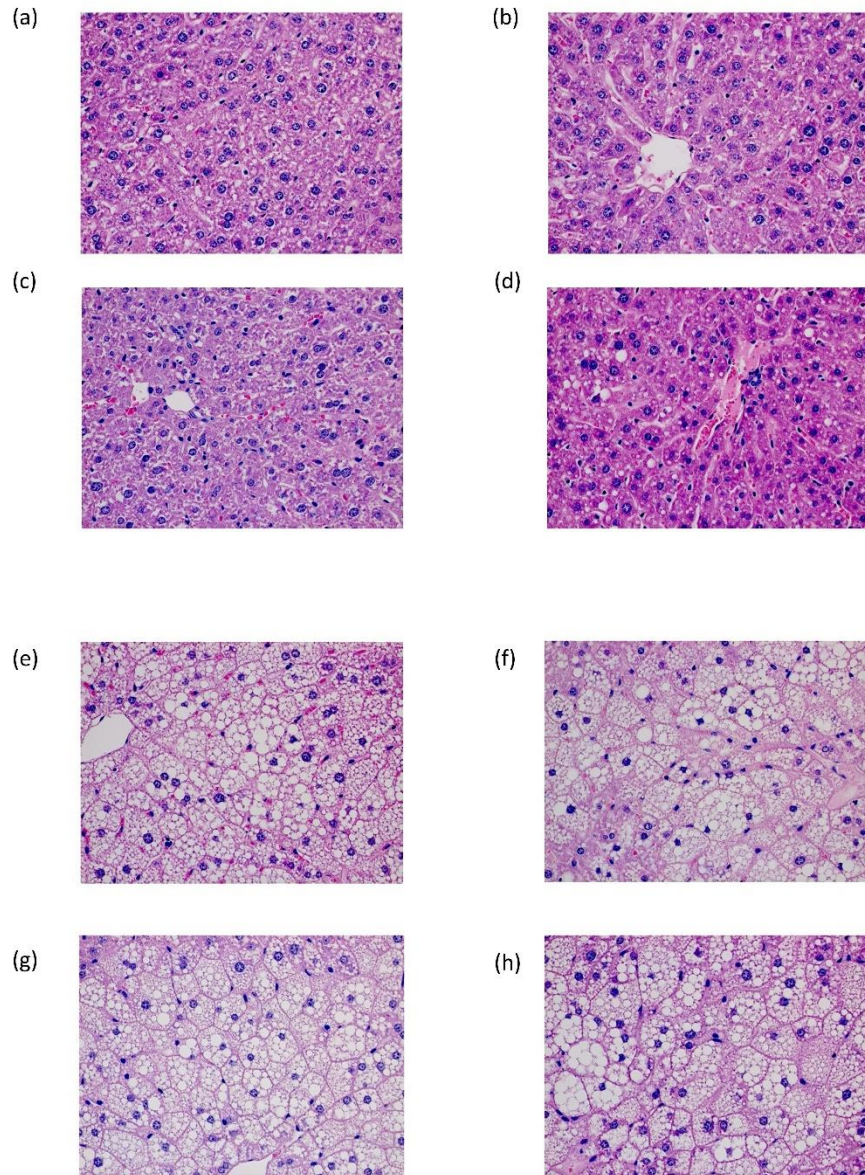


Figure S1. Liver histology of the mouse model. (a-d) Liver biopsy of NAFL sample 2-5 with hematoxylin-eosin staining, scale bar 20 μm ; (e-h) Liver biopsy of NASH sample 2-5 with hematoxylin-eosin staining, scale bar 20 μm .

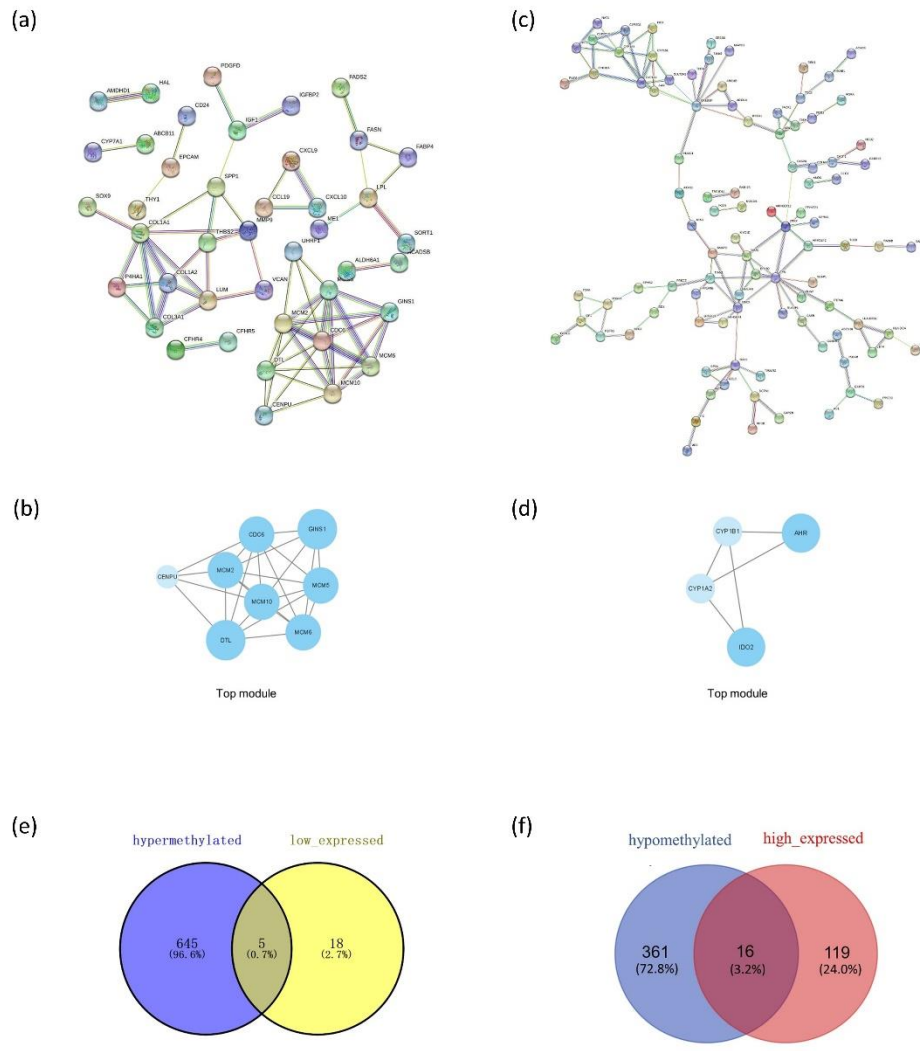


Figure S2. The network of PPI analysis. (a) PPI network of the DEGs in the Normal vs NASH group; (b) Top module of the DEGs in the Normal vs NASH group; (c) PPI network of the DMGs in the Normal vs NASH group; (d) Top module of the DMGs in the Normal vs NASH group; (e) Identification of hypermethylated and low expressed genes; (f) Identification of hypomethylated and high expressed genes.

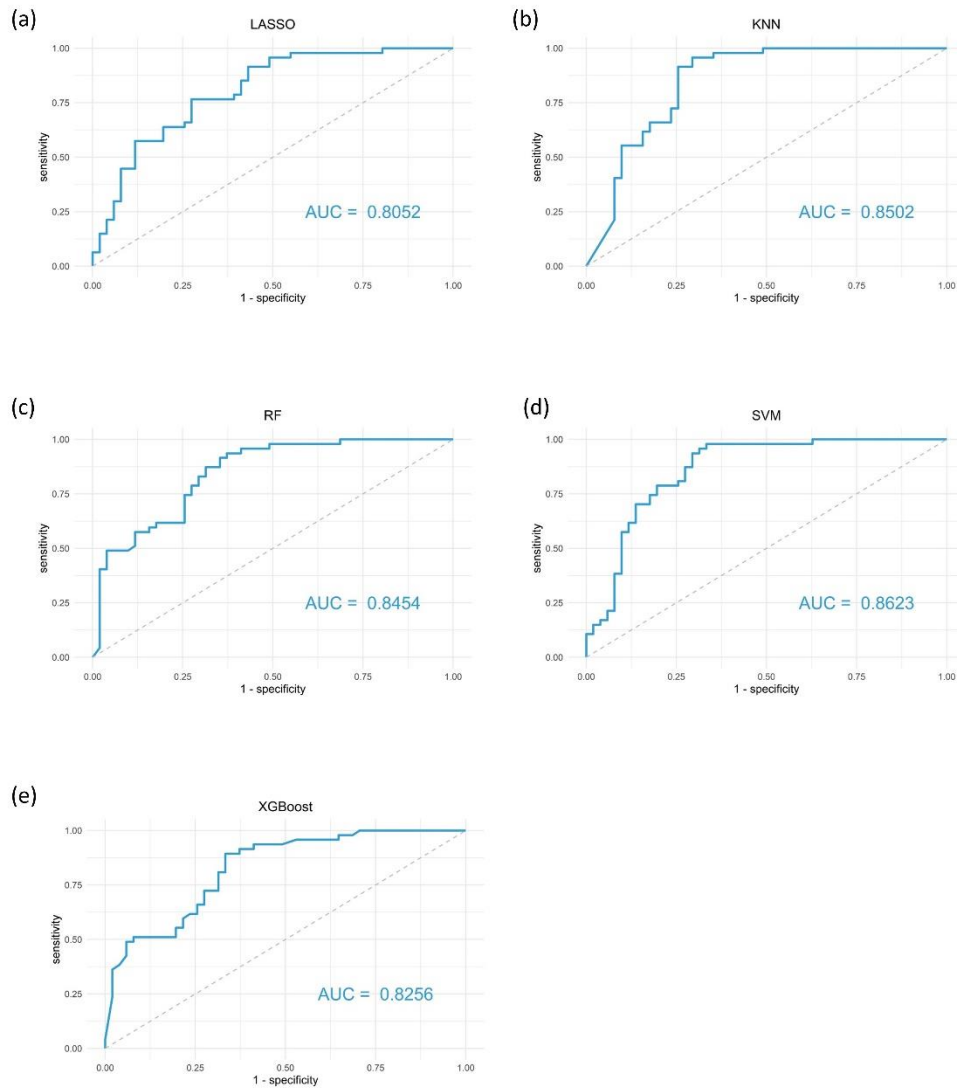


Figure S3. Receiver operating characteristic curves of different diagnostic models. (a) Receiver operating characteristic curve of the LASSO model; (b) Receiver operating characteristic curve of the KNN model; (c) Receiver operating characteristic curve of the RF model; (d) Receiver operating characteristic curve of the SVM model; (e) Receiver operating characteristic curve of the XGBoost model.