

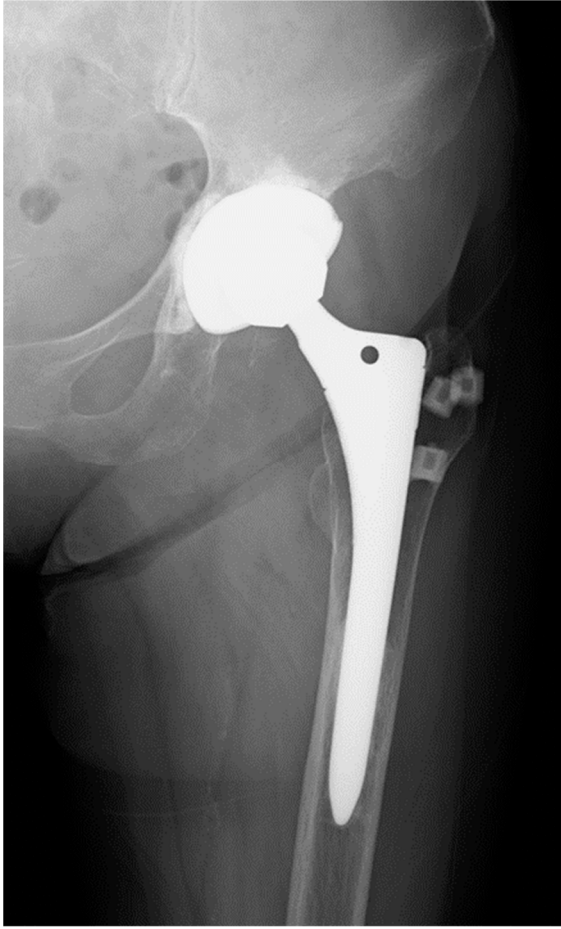Figure S1. Radiographs of the left hip of a 74-year-old woman.

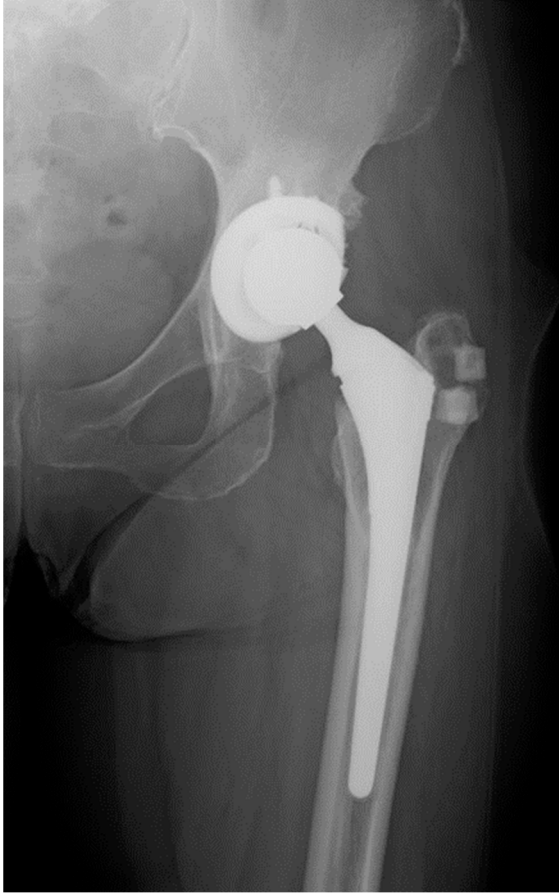


Figure S2. Radiographs of the left hip of a 63-year-old woman.

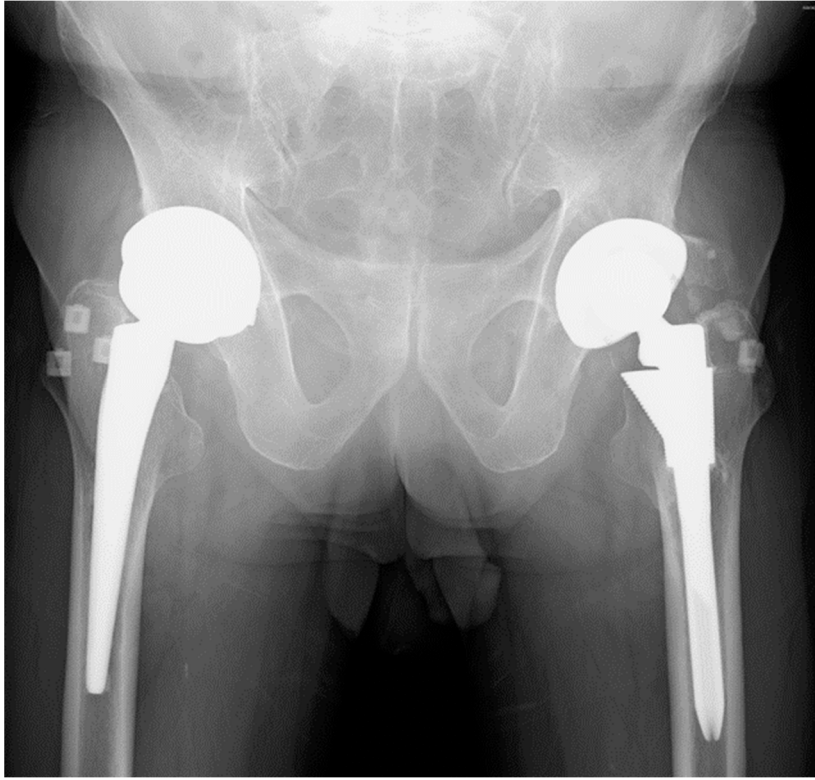


Figure S3. Radiographs of the both hips of a 71-year-old man.

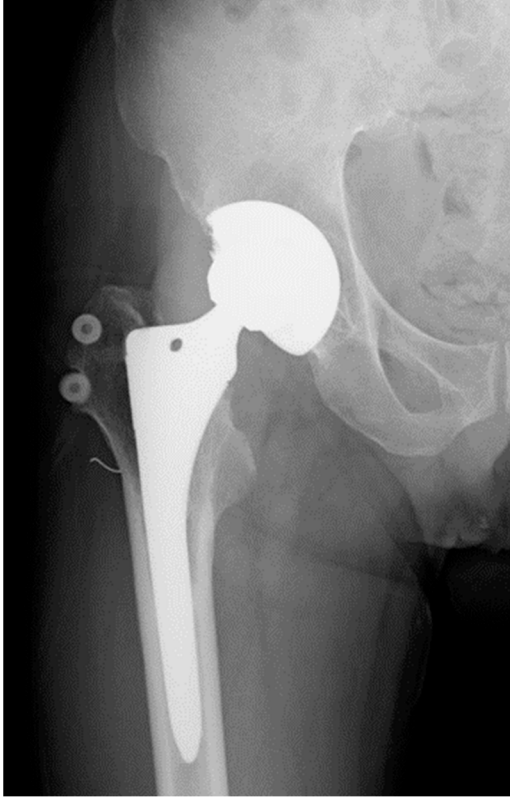

Figure S4. Radiographs of the right hip of a 57-year-old man.

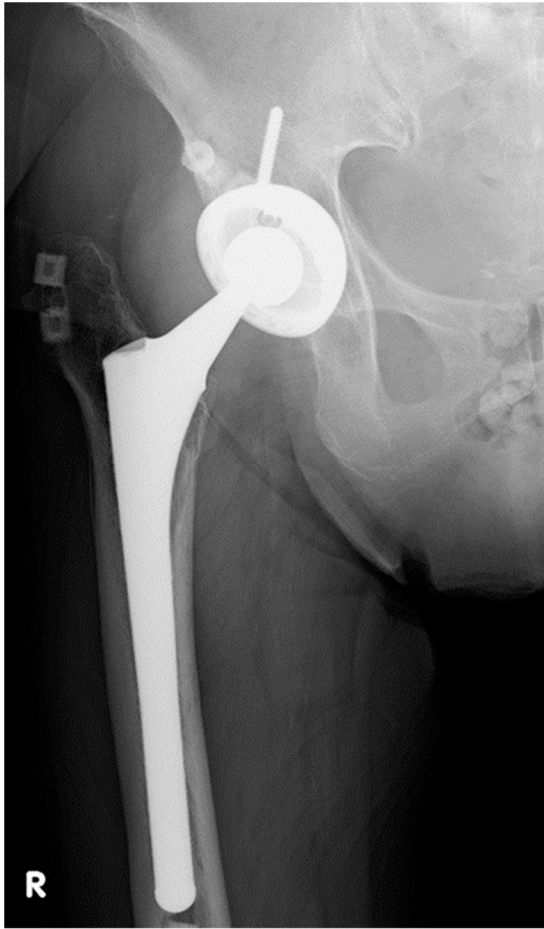


Figure S5. Radiographs of the right hip of a 69-year-old woman.