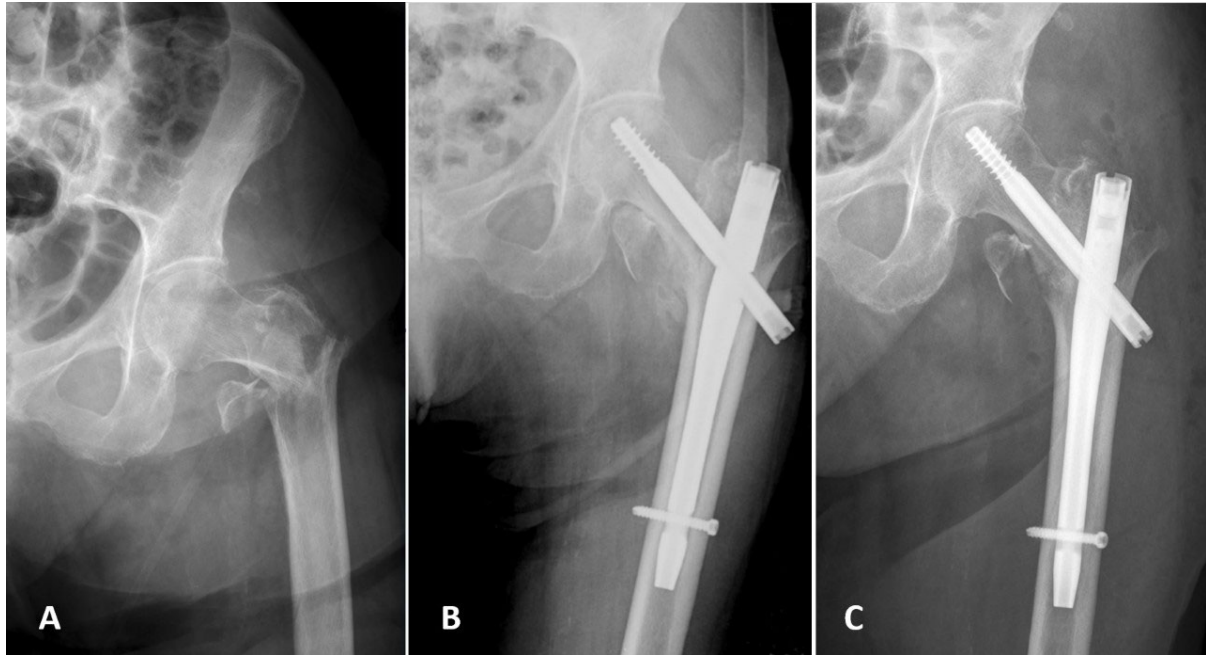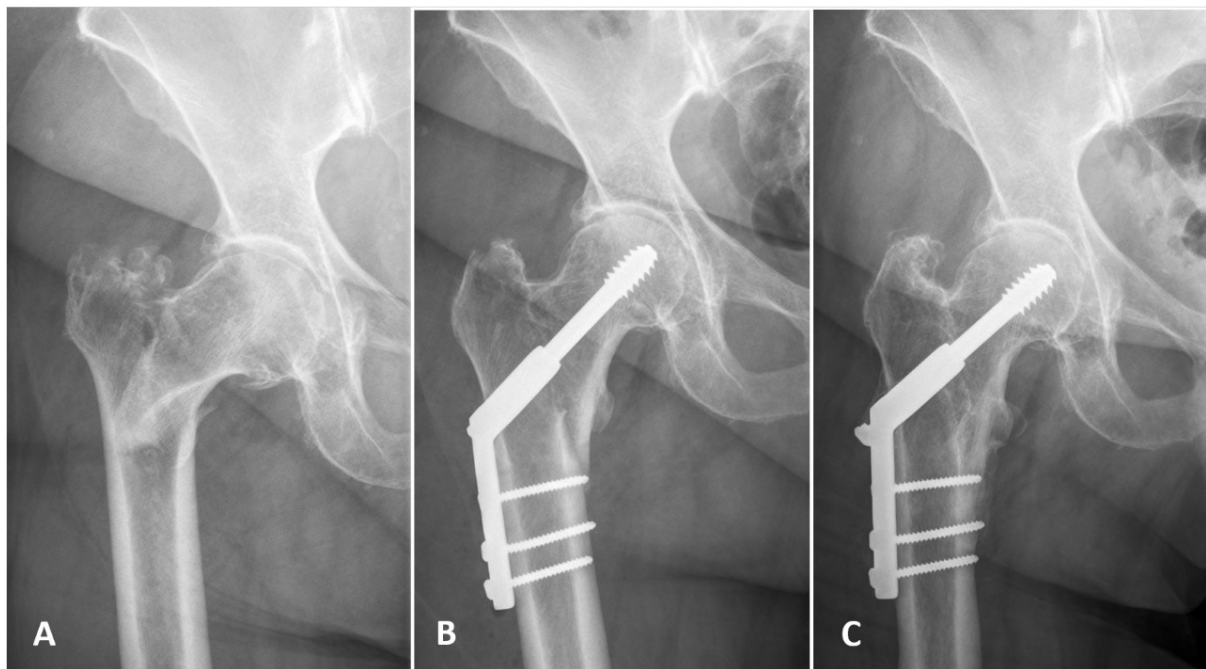


**Figure S1.** A 79-year-old female who sustained a left pertrochanteric fracture (type A2 - AO/OTA classification). **A**—fracture before surgery; **B**—one day after the stabilization with dynamic hip screw (DHS) system; and **C**—one-year follow-up.



**Figure S2.** A 88-year-old female who sustained a right pertrochanteric fracture (type A3 - AO/OTA classification). **A**—fracture before surgery; **B**—two days after the stabilization with gamma nail fixation (GNF) system; and **C**—one-year follow-up.