

LEGEND OF TABLES

Supplementary Table S1. Complications of surgical procedures in “Treated uterine septum versus controls (untreated septum)” section.

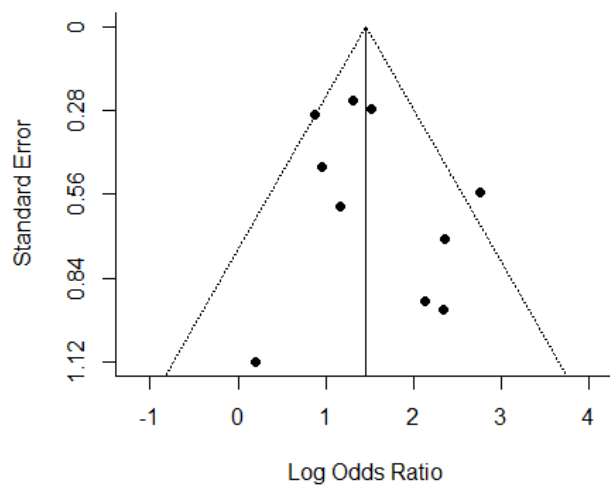
Study	Sample Size: case/control	Complications
Heinonen et al. 1997, J Am Assoc Gynecol Laparosc	19/19	Three patients: - One uterine perforation but surgical intervention was unnecessary. - Two patients with abnormal bleeding treated by inserting a Foley catheter into the uterine cavity.
Valli et al. 2004, J Am Assoc Gynecol Laparosc	28/15	One case of a small fundal perforation that required a laparoscopic suture
Ban-Frangez et al. 2009, Eur J Obstet Gynecol	106/212	N/A
Lin et al. 2009, Int J Gynaecol Obstet	21/15	No complications
Pang et al. 2011, Int J Gynecol Obstet	46/32	N/A
Tonguc et al. 2011, Int J Gynecol Obstet	102/25	N/A
Sugiura-Ogasawara et al. 2014, Journal of Obstetrics and Gynaecology	109/15	N/A
Rikken et al. 2020, Human Reproduction	151/106	Seven patients: - Three women with uterine perforation, in - One woman with intravasation - Three women with excessive bleeding
Whelan et al. 2020, American College of Obstetricians and Gynecologists	21/11	N/A

Supplementary Table S2. Complications of surgical procedures in “Before and after septum removal” section.

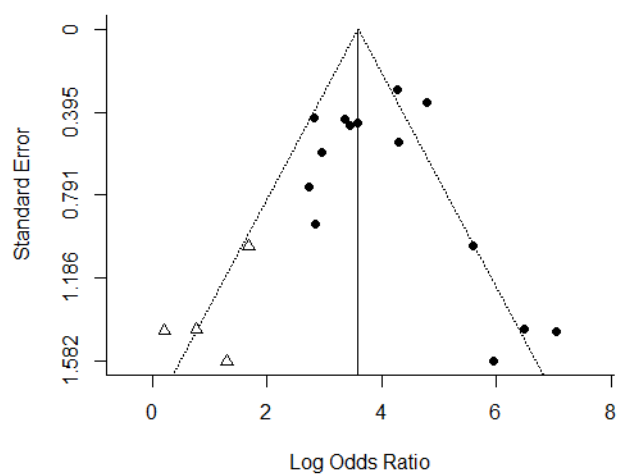
Sudy	Simple size	Complications
Valle et al. 1986, Obstet Gynecol	124	No complications
Guarino et al. 1989, Acta Eur Fertil	19	N/A
Choe et al. 1992, Fertil Steril	14	Two patients: - One case was complicated by a small perforation that did not require any treatment of the uterus during procedure. - Second case developed uterine synechiae in the left cornual area postoperatively on HSG.
Grimbizis et al. 1998, Hum Reprod	57	During the procedure, two operations were complicated by small perforations that did not require any further treatment.
Jourdain et al. 1998, Int J Gynaecol Obstet	17	No complications
Porcu et al. 2000, Eur J Obstet Gynecol Reprod Biol	63	One case of abnormal bleeding was controlled by endoscopic coagulation.
Venturoli et al. 2002, Arch Gynecol Obstet	141	No complications
Saygili-Yilmaz et al. 2003, Arch Gynecol Obstet	361	Fifteen patients: -Five patients with fluid overload syndrome -Ten patients with uterine perforation (five of these cases were repaired by laparoscopy right after the septum incision. The other five however, had to be repaired by laparotomy due to the size of the perforation >1 cm).
Yang et al. 2006, Photomed Laser Surg	46	N/A
Wang et al. 2009, Fertil Steril	25	No complications
Roy et al. 2011, Arch Gynecol Obstet	152	Five patients. - One patient with difficult dilatation leading to cervical injury - Two patients with uterine perforation (laparoscopy by bipolar coagulation). - Two patients had excessive bleeding at the end of the procedure which was managed by the tamponade of Foley's
Sendag et al. 2010, Clin Exp Obstet Gynecol	30	N/A
Gergolet et al. 2012, Reproductive BioMedicine Online	72	No complications
Bendifallah et al. 2013, J Minim Invasive Gynecol	128	Four patients with uterine perforation
Gundabattula et al. 2014, J obstet Gynecol	124	N/A

Paradisi et al. 2014, Arch Gynecol Obstet	112	No complications
John et al. 2015, J Minim Invasive Gynecol	286	One patient with uterine perforation
Freud et al. 2015, J Matern Fetal Neonatal Med	28	N/A
Wang et al. 2019, Medicine (Baltimore)	121	No complications

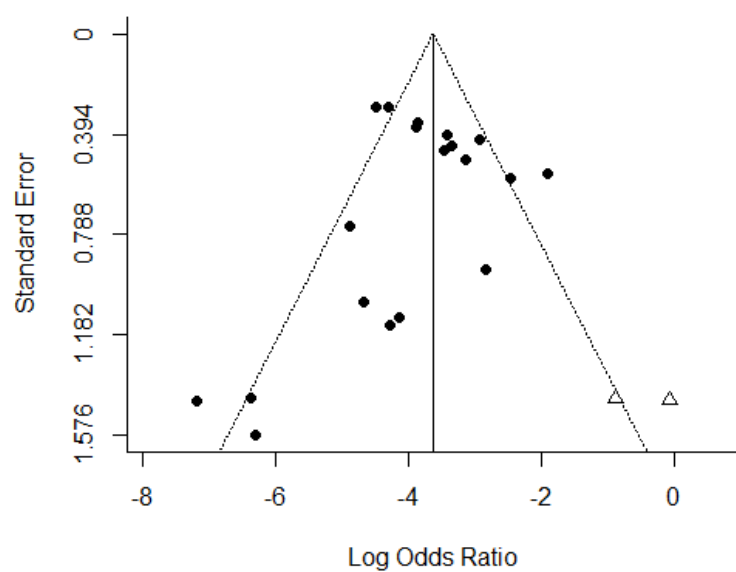
LEGEND OF FIGURES:



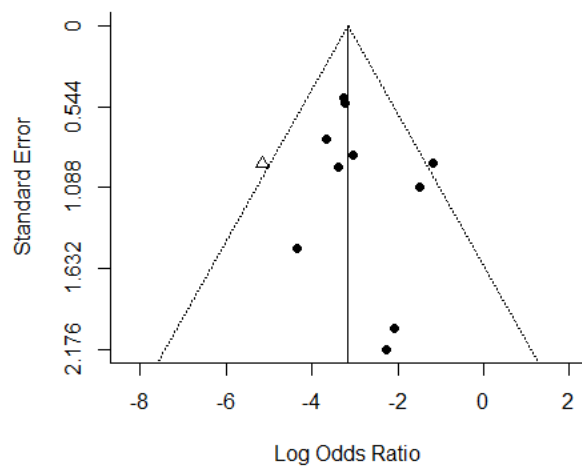
Supplementary Figure S1. Funnel plot of studies comparing spontaneous abortions in I-II trimesters between septate uterus vs. controls (no septate uterus).



Supplementary Figure S2. Funnel plot of studies comparing live birth rate before vs. after the removal of septate uterus



Supplementary Figure S3. Funnel plot of studies comparing spontaneous abortions in I-II trimesters before vs. after the removal of septate uterus.



Supplementary Figure S4. Funnel plot of studies comparing preterm labour before vs. after the removal of septate uterus