

Case Report

Ultrasound-Assisted Removal of a Wooden Foreign Body Embedded in the Neck

Daniele Vitali [†], Pietro Orlando ^{*,†}, Giandomenico Maggiore, Oreste Gallo  and Ilaria Bindi

Department of Otorhinolaryngology, Careggi University Hospital, Largo Brambilla 3, 50134 Florence, Italy

* Correspondence: pietro.orlando@unifi.it[†] These authors contributed equally to this work.

Abstract: Objectives: The deep submucosal migration of ingested foreign bodies into the pharyngolaryngeal mucosa is a sporadic event, and its management can be very challenging. In the case of the failure of endoscopic retrieval, open surgical techniques are usually required, and intraoperative ultrasonography can become a useful adjunct for identifying their precise localization. Methods: An 84-year-old woman presented with new-onset dysphagia and odynophagia after the accidental ingestion of a fragment of a toothpick a few hours before in the absence of hoarseness or respiratory distress. Ultrasonography and an unenhanced CT scan of the neck revealed a 3 cm linear foreign body embedded into the neck between the left pyriform sinus and the esophageal wall. Results: We report the removal of a fragment of a wooden toothpick deeply lodged between the left pyriform sinus and the esophageal wall, which was managed via an open transcervical approach with the aid of intraoperative ultrasound guidance. Conclusions: We suggest that both preoperative and intraoperative ultrasonography should represent the first-line imaging technique for deeply embedded neck foreign bodies.

Keywords: foreign bodies ingestion; foreign bodies migration; larynx; intraoperative ultrasonography; otorhinolaryngologic surgical procedures; open technique



Citation: Vitali, D.; Orlando, P.; Maggiore, G.; Gallo, O.; Bindi, I. Ultrasound-Assisted Removal of a Wooden Foreign Body Embedded in the Neck. *Surg. Tech. Dev.* **2024**, *13*, 1–8. <https://doi.org/10.3390/std13010001>

Academic Editors: Egidio Riggio and Gopal C. Kowdley

Received: 15 July 2023

Revised: 2 September 2023

Accepted: 8 December 2023

Published: 19 December 2023



Copyright: © 2023 by the authors. Licensee MDPI, Basel, Switzerland. This article is an open access article distributed under the terms and conditions of the Creative Commons Attribution (CC BY) license (<https://creativecommons.org/licenses/by/4.0/>).

1. Introduction

Foreign body (FB) ingestion is a very frequent reason for access to the emergency department in both the pediatric and adult populations. Fortunately, only about 10–20% of patients who ingest or inhale a FB need medical intervention [1,2]. In the vast majority of cases, FBs can be easily removed via transnasal or transoral routes with or without the aid of flexible fiberoptic laryngoscopy. On the contrary, when the FB is completely embedded in the pharyngolaryngeal mucosa or deeply migrated into the neck's soft tissue (muscles, paraglottic space, retropharyngeal space, and thyroid gland), open surgical techniques are usually required [3–7]. In particular, FBs that penetrate the laryngeal lumen can become life-threatening emergencies because of the risk of sudden respiratory distress. Such cases occur in less than 4% of the published clinical case series, while the penetration and migration of FBs into the neck's soft tissues appear to be exceedingly rare [1–4]. Historically, conventional X-ray, computed tomography (CT), and magnetic resonance (MR) have been successfully used for the detection of a FB, each one with its own advantages and disadvantages depending on hospital availability, the patient's characteristics (e.g., ferromagnetic implants, claustrophobia, inability to collaborate...), the suspected anatomical location of the FB and its material [8]. Over the last decade, the use of ultrasound-assisted techniques has greatly improved the surgical and non-surgical success rate of FB removal; compared to other imaging techniques, an ultrasound (US) is cheaper, faster, and able to detect a wide range of different materials such as wood, glass, metal, and plastic [9,10]. However, its use in the otolaryngology head and neck surgery field remains scant. Herein, we present the first case of an intraoperative US-assisted removal of

an ingested wooden toothpick that pierced the pharyngeal wall and penetrated into the neck's soft tissue, thus requiring an open transcervical approach. We also reviewed other methods to identify an extraluminally migrated FB.

2. Detailed Case Description

An 84-year-old woman presented at the emergency department of our University Hospital complaining of sudden dysphagia and odynophagia onset after the accidental ingestion of a fragment of a toothpick a few hours before. Her past medical history only included arterial hypertension that was under medical treatment, and no cognitive impairment or other psychiatric comorbidities were known at that moment of the visit. On admission, there was no evidence of hoarseness, retractions, wheezing, or respiratory distress at the inspection, and her vital signs were normal. Her hemogram did not show any indirect signs of blood loss or infection. A fully detailed head and neck evaluation, including an oropharyngoscopy, cervical palpation, and a trans-nasal fiberoptic exam of the upper aerodigestive tract (UADT), did not reveal any FB in these anatomical regions which are known to be frequent sites of FB embedding (i.e., palatine tonsils, glosso-epiglottic valleculae, the base of the tongue, and pyriform sinuses). In addition, there was no edema of the pharyngeal walls nor pooling saliva in the hypopharynx; her neck did not present any mass or tenderness, and the mobility of the vocal cords was maintained. The patient only complained of a persistent stinging discomfort that she fingered just below the cutaneous projection of her left hyoid greater horn. Actually, during the flexible fiberoptic laryngoscopy, a circumscribed millimetric hyperemic area was evident in her left medial pyriform sinus wall that corresponded to the skin point fingered by the patient. A simple swallowing water test was negative, and cervical palpation did not find any masses, tenderness, signs of infection, or subcutaneous emphysema. We opted for careful monitoring in the emergency department. As symptomatology grew, we repeated the flexible fiberoptic examination of the UADT about 12 h later. We detected the increasing edema of the left arytenoid cartilage and the presence of minimal granulation tissue on the medial wall of her left pyriform sinus. The mobility of the vocal cords was preserved, and no other signs or symptoms were identified at this second examination. Thus, an unenhanced CT scan of the neck was requested, revealing at the axial section a 3 cm linear FB lodged into the soft tissue of the neck, medial to the inferior portion of the left pyriform fossa, and extending up to the superior margin of the thyroid cartilage. There were radiological indirect signs of localized edema and the obliteration of the left pyriform fossa, but no evidence of abscess (Figure 1). Moreover, the FB fragment seemed to be located less than 1 cm in distance from the internal jugular vein. To better study the relationships between the FB and the major neck vessels, we performed an US examination with an 8 MHz probe (Esaote MyLabtm40, Esaote S.p.A., Genova, Italy), identifying the wooden FB as a hyperechoic line, comprising radiolucent material, with a mild posterior hypoechoic halo, the plausible result of recent inflammation (Figure 2). On the same day, the patient was scheduled for a suspension micro-laryngoscopy and a rigid esophagoscopy under general anesthesia. During the exploration, no FB was detectable, and we only noticed an even greater edema of the left arytenoid and pyriform fossa and the presence of a small area covered by a fibrinous membrane on the medial wall of the patient's left pyriform sinus, which we speculated to be the possible site of toothpick penetration and migration into the neck. The remaining mucosa of the UADT was unharmed. Based on radiological and endoscopic findings, it was confirmed that the toothpick was deeply embedded between the left pyriform sinus and the esophageal wall; thus, we opted for an open transcervical approach under US guidance to appropriately remove the FB. We marked the skin overlying the hyperechoic line visible by the US and performed a 5 cm incision overlying the FB along the anterior border of the sternocleidomastoid muscle. After raising the subplatysmal flap, thanks to the assistance of the US, the FB was localized deeply under the omohyoid muscle, just a few millimeters from the internal jugular vein. The prelaryngeal muscles were laterally retracted, and the larynx was moved forward and medially to better visualize

the toothpick. Via blunt dissection, the FB was exposed and then entirely removed, as demonstrated by the US (Figure 3). No perioperative complications were reported. The patient did not need a tracheostomy nor postoperative observation at the intensive care unit after surgery, as she did not have hemodynamic instability, respiratory distress, or a cervical abscess. In the following days, broad-range antibiotic therapy was intravenously administered, consisting of amoxicillin/clavulanic acid 875/125 mg TID and metronidazole 500 mg TID. Enteral nutrition was guaranteed via a nasogastric feeding tube. To be safely discharged, on the 6th postoperative day, a neck CT scan was obtained, as well as a PO Gastrografin swallow test. The latter revealed a small fistula tract lateral to the left arytenoid and medial to the left superior thyroid lobe. Consequently, antibiotic therapy and enteral nutrition were maintained in the following days. After 72 h, a second radiological control demonstrated the complete closure of the pharyngeal wall interruption. The patient started to drink some sips of water and gradually resumed her usual oral feeding. She was discharged on the 10th postoperative day with no home therapy.

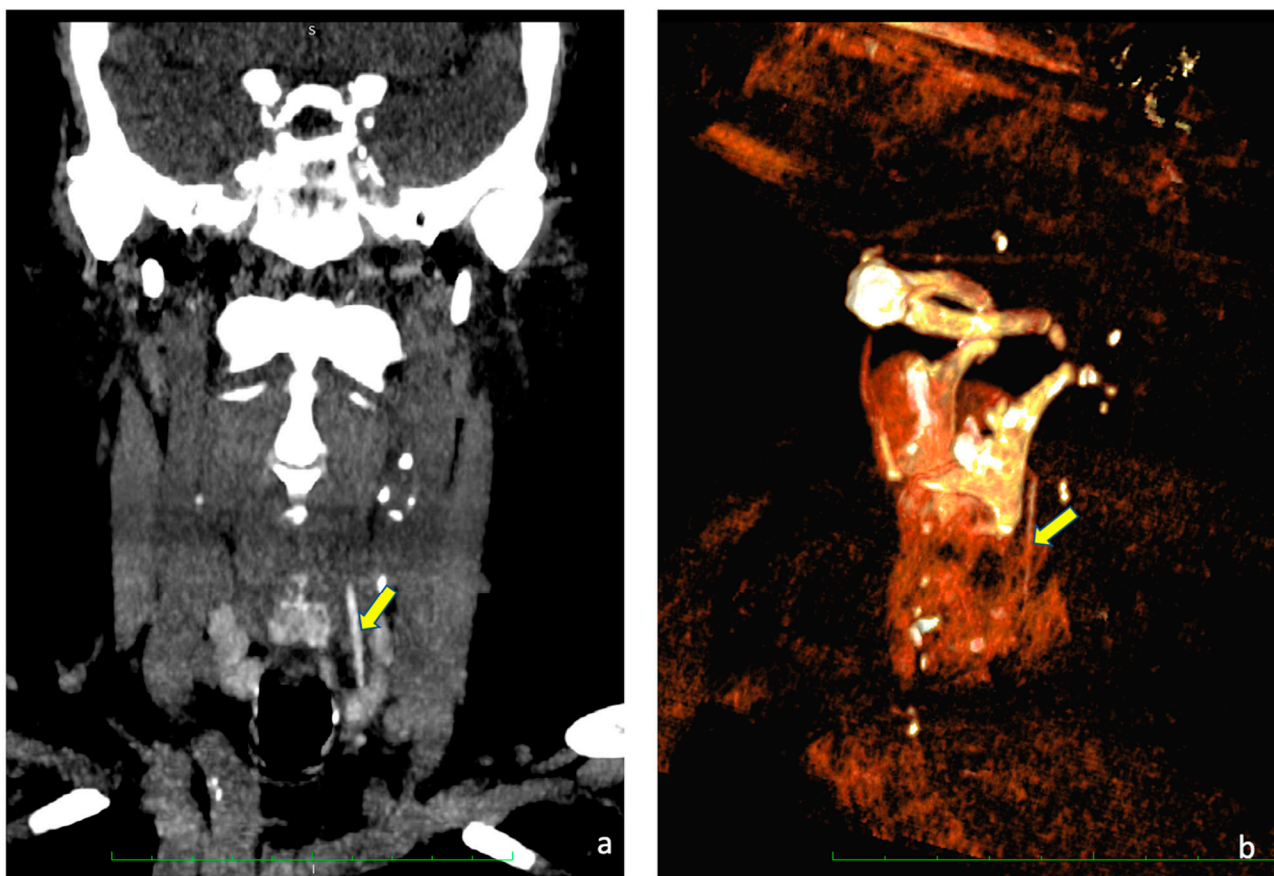


Figure 1. (a) CT scan of the neck, coronal view. (b) 3D reconstruction. In both pictures, the yellow arrow points toward the toothpick.

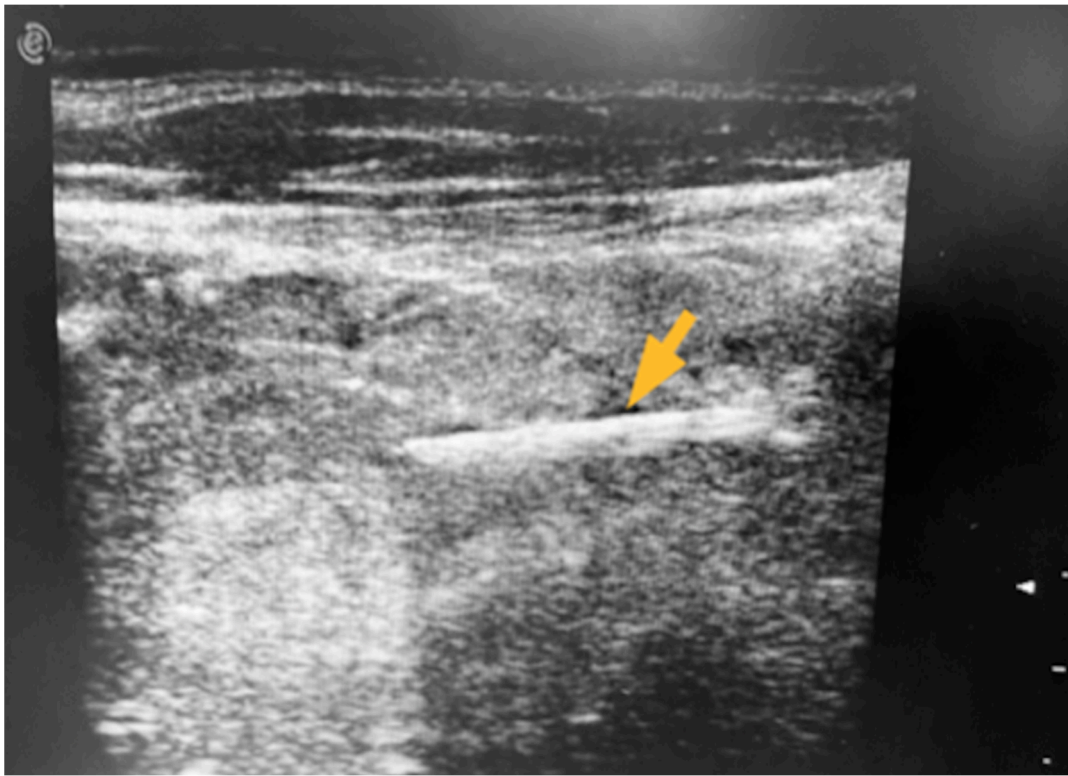


Figure 2. Intraoperative US: the FB was detected as a hyperechoic line with a mild posterior hypoechoic halo (arrow).

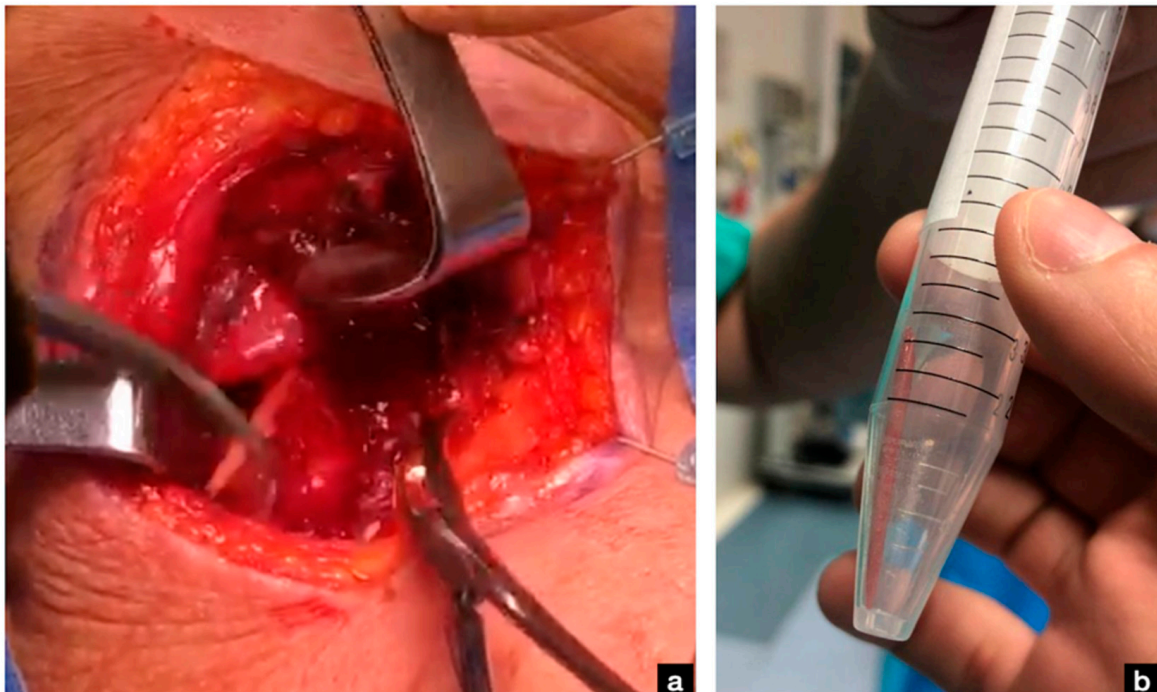


Figure 3. (a) Intraoperative view of the transcervical removal of the FB. (b) The entire 3 cm wooden FB is shown after extraction.

3. Discussion

A FB in the neck is a very common cause of emergency department admission [11]. The vast majority of FBs are derived from penetrating injuries, while only a very small

percentage of cases are derived from a swallowed FB perforating the UADT and migrating into the neck structures [12]. The misidentification of a FB is not so uncommon, even for a well-trained clinician [13]. A very recently published study by Chen et al. found a sensitivity and a negative predictive value (NPV) of 25% and 57% for flexible fiberoptic laryngoscopy alone in the detection of ingested FBs [14]. In addition, the correct localization is made even more challenging by the little correlation between the subjective and actual location of a swallowed FB, as reported by Yang and Yang [15]. If missed, a retained FB may lead to inflammation, delayed healing, vessel and esophagus lacerations, difficult-to-treat infections in the neck structures, and even septic shock and death [3,16,17]. Thus, precautionary broad-range antibiotic treatment is indispensable in the case of doubtful organic FB ingestion/inhalation [18]. As of today, no internationally accepted guidelines nor expert consensus about the retrieval of FBs embedded into the neck's soft tissue are available [19]. If the FB is not clearly detectable at the endoscopic exam of the UADT and the patient complains of worsening symptoms, it becomes essential to investigate further. Vital signs should always be assessed to identify possible hemodynamic and respiratory instability. Likewise, a hemogram should be performed to check for a decrease in hemoglobin and/or white blood cell (WBC) count improvement. Finally, one or sometimes more than one imaging technique may be necessary, as the crucial point for the management of a FB embedded in the neck is its proper localization since their migration routes may be unforeseeable. An X-ray alone is suboptimal for radiopaque objects because of its low sensitivity (41%) and NPV (33%) and is even unnecessary for fishbones. A CT scan demonstrated a higher sensitivity and NPV but lower specificity than an X-ray [14,19,20]. The US may identify both radiolucent and radiopaque materials, demonstrating to be superior to the other common imaging techniques in the identification of wooden objects [21,22]. In addition, it can be used even intraoperatively, giving immediate feedback about the complete FB removal. Nonetheless, the US technique is highly examiner-dependent and may fail in the detection of a FB obscured by bone or air [8]. Otherwise, in the case of a risk of sudden respiratory obstruction and/or neck abscess, a CT scan remains the gold standard. However, artifacts from metallic dental implants may impede FB localization in the upper tract of the neck. With this in mind, a neck US should be considered the first-line imaging modality in the emergency department. It is fast, cheap, and easily available even in the smallest emergency settings.

In the present case, the most likely entry site of the toothpick was the medial wall of the patient's left pyriform sinus. In Italy, it is very common to cook meat rolls that are "locked" by one or more toothpicks. After the preparatory and propulsive stages of deglutition, the pharyngeal phase differs between solid and liquid intakes. The path of entry in the superior esophageal sphincter (UES) for solid bolus occurs through the midline within the pharynx as a single column. On the contrary, liquids enter the pharynx from both sides of the glottis as two separated columns, accumulate in the pyriform sinuses, and rejoin as a single column before entering the UES [23,24]. Therefore, we believe that the patient ingested the toothpick fragment while eating and tried to push it down in the stomach by drinking, thus carrying the FB to her left pyriform sinus. Subsequently, involuntary contractions of the hypopharyngeal and cricopharyngeal muscles led to FB migration deeply into the extra-UAET soft tissues. In the case of an ingested FB that is not detectable at the endoscopic exam, we prefer to perform both an US and CT to empower diagnostic accuracy and drive the surgical approach. Furthermore, the US may be useful even during surgery to guide blunt dissection and confirm the complete excision of the FB, particularly for the youngest surgeons and residents. After surgery, in-hospital stay management consists of a 6-day period of enteral nutrition and EV broad-range antibiotic therapy to rest the pharyngoesophageal tract and prevent infections; on the 6th postoperative day, a PO Gastrografin swallow test to discard possible fistulas and a CT scan to exclude neck infections are performed. When a small fistula is detected (as in the present case), a conservative strategy, including a compressive neck bandage and the prolongation of enteral nutrition and antibiotic therapy, is carried out until the complete healing of the

fistulous tract is demonstrated at a second swallow test performed 72 h later. In case of failed closure, hyperbaric oxygen or vacuum-assisted therapies may be useful to avoid surgical repair [25].

Open surgical techniques are usually required in case of endoscopic retrieval failure and/or when the FB lies near major vessels or other vital structures, and many approaches have been described [18]. Hemithyroidectomy has been proposed for the retrieval of a FB stuck in the thyroid gland [26]. For FB located in the paraglottic space, both anterior and posterior approaches to the laryngeal cartilages have been described [27–30]. With technological advances, imaging-guided approaches have been promisingly introduced. The US has been successfully used by various authors to pinpoint the FB and to preserve vessels and other anatomical structures, thus decreasing the rate of perioperative complications to confirm the complete removal of the FB and minimize the length of the cervical incision, thus corresponding to the aesthetic sequelae of an open approach [27,31,32]. Other authors opted for a percutaneous fluoroscopically guided localization of the extraluminally migrated FB that allowed the real-time assessment of the FB, a lower rate of postoperative complications, and a shorter hospital stay [16,33–35]. Finally, Wu et al. used CT-guided neck navigation to identify the exact site of where to incise the pharyngeal mucosa for chicken bone extraction [36]. To the best of our knowledge, this is the first case of a wooden FB ingested that has migrated deeply into the neck and been removed with the intraoperative assistance of an US. We only found one more paper reporting a toothpick that likely penetrated the anterior wall of the stomach and reached the liver, developing a pyogenic liver abscess [37].

4. Conclusions

The ingestion or inhalation of a FB is a very common reason for ENT emergency admission. Fortunately, only a small number of patients experience severe complications or extraluminal FB migration, thus requiring surgery. In the case of an unsuccessful trans-oral endoscopic attempt, which still represents the gold standard surgical technique, an open trans-cervical approach is needed. The appropriate localization of the FB is pivotal for its complete and safe removal. In this regard, we believe that the US technique should represent the first-line imaging exam in the absence of deep neck abscess or respiratory distress, preferring a CT scan in similar scenarios. Moreover, we strongly recommend performing surgery with the intraoperative aid of the US, as it may detect several different materials, drive neck dissection in a real-time fashion, and give immediate feedback about a complete excision.

Author Contributions: D.V.: study conceptualization, writing, editing; P.O.: writing, editing, images acquisition; G.M.: writing, editing; O.G.: study conceptualization; review of the draft; I.B.: writing, editing, study conceptualization. All authors read the paper, knew that their data are used for research. All authors have read and agreed to the published version of the manuscript.

Funding: This study did not receive any funding source.

Institutional Review Board Statement: The study was approved by the local ethics committee. The project identification code is RIF CEAVC 19928, and it was approved on 7/06/2022 by the local ethics commitment of the Careggi University Hospital of Florence.

Informed Consent Statement: Informed consent was obtained from the patient included in the present article.

Data Availability Statement: Data sharing is not applicable to this article as no datasets were generated or analyzed during the current study.

Conflicts of Interest: The authors declare no conflict of interest.

References

1. Zaytoun, G.M.; Rouadi, P.W.; Baki, D.H.A. Endoscopic Management of Foreign Bodies in the Tracheobronchial Tree: Predictive Factors for Complications. *Otolaryngol. Head Neck Surg.* **2000**, *123*, 311–316. [\[CrossRef\]](#) [\[PubMed\]](#)
2. Cohen, S.R.; Herbert, W.I.; Lewis, G.B., Jr.; Geller, K.A. Foreign bodies in the airway. Five-year retrospective study with special reference to management. *Ann. Otol. Rhinol. Laryngol.* **1980**, *89 Pt 1*, 437–442. [\[CrossRef\]](#) [\[PubMed\]](#)
3. Pai, K.; Pillai, S.; Bhandarkar, A.; Anand, A.; Sabhahit, H. Migrating Ingested Foreign Body of the Upper Aerodigestive Tract with Resultant Septic Shock: Case report and literature review. *Sultan Qaboos Univ. Med. J.* **2013**, *13*, 606–610. [\[CrossRef\]](#) [\[PubMed\]](#)
4. Birk, M.; Bauerfeind, P.; Deprez, P.H.; Häfner, M.; Hartmann, D.; Hassan, C.; Hucl, T.; Lesur, G.; Aabakken, L.; Meining, A. Removal of foreign bodies in the upper gastrointestinal tract in adults: European Society of Gastrointestinal Endoscopy (ESGE) Clinical Guideline. *Endoscopy* **2016**, *48*, 489–496. [\[CrossRef\]](#)
5. Sehgal, I.S.; Dhooria, S.; Ram, B.; Singh, N.; Aggarwal, A.N.; Gupta, D.; Behera, D.; Agarwal, R. Foreign Body Inhalation in the Adult Population: Experience of 25,998 Bronchoscopies and Systematic Review of the Literature. *Respir. Care* **2015**, *60*, 1438–1448. [\[CrossRef\]](#) [\[PubMed\]](#)
6. Ramos, M.; Botana-Rial, M.; García-Fontán, E.; Fernández-Villar, A.; Torreira, M. Update in the extraction of airway foreign bodies in adults. *J. Thorac. Dis.* **2016**, *8*, 3452–3456. [\[CrossRef\]](#) [\[PubMed\]](#)
7. Athierah, M.; Geng, J.T.; Farah, D.Z.; Nik, R.N.H. Migratory Fish Bone Presented with Extensive Surgical Subcutaneous Emphysema: A Case Report. *J. Emerg. Med.* **2021**, *61*, e4–e6. [\[CrossRef\]](#)
8. Voss, J.O.; Maier, C.; Wüster, J.; Beck-Broichsitter, B.; Ebker, T.; Vater, J.; Dommerich, S.; Raguse, J.D.; Böning, G.; Thieme, N. Imaging foreign bodies in head and neck trauma: A pictorial review. *Insights Imaging* **2021**, *12*, 20. [\[CrossRef\]](#)
9. Del Cura, J.L.; Aza, I.; Zabala, R.M.; Sarabia, M.; Korta, I. US-guided Localization and Removal of Soft-Tissue Foreign Bodies. *RadioGraphics* **2020**, *40*, 1188–1195. [\[CrossRef\]](#)
10. Callegari, L.; Leonardi, A.; Bini, A.; Sabato, C.; Nicotera, P.; Spano', E.; Mariani, D.; Genovese, E.A.; Fugazzola, C. Ultrasound-guided removal of foreign bodies: Personal experience. *Eur. Radiol.* **2009**, *19*, 1273–1279. [\[CrossRef\]](#)
11. Hariga, I.; Khamassi, K.; Zribi, S.; Amor, M.B.; Gamra, O.B.; Mbarek, C.; Khedim, A.E. Management of foreign bodies in the aerodigestive tract. *Indian J. Otolaryngol. Head Neck Surg.* **2014**, *66* (Suppl. 1), 220–224. [\[CrossRef\]](#) [\[PubMed\]](#)
12. Bolatkale, M.; Can, Ç.; Sarihan, A.; Acara, A.C. The removal of shrapnel from deep tissue with a magnet: A novel approach. *Am. J. Emerg. Med.* **2017**, *35*, 194.e5–194.e6. [\[CrossRef\]](#)
13. Gurevich, Y.; Sahn, B.; Weinstein, T. Foreign body ingestion in pediatric patients. *Curr. Opin. Pediatr.* **2018**, *30*, 677–682. [\[CrossRef\]](#) [\[PubMed\]](#)
14. Chen, Y.H.; Shomorony, A.; Drusin, M.A.; Pearlman, A.N. Consultations for Foreign Bodies in Aerodigestive Tract: Assessment of Diagnostic Modalities. *Laryngoscope* **2023**, *133*, 1361–1366. [\[CrossRef\]](#) [\[PubMed\]](#)
15. Yang, C.Y.; Yang, C.C. Subjective neck pain or foreign body sensation and the true location of foreign bodies in the pharynx. *Acta Otolaryngol.* **2015**, *135*, 177–180. [\[CrossRef\]](#) [\[PubMed\]](#)
16. Ho, N.H.; Chang, F.C.; Wang, Y.F. Clinical Approaches to Migrating Ingested Foreign Bodies in the Neck. *Ear Nose Throat J.* **2022**, *101*, 181–185. [\[CrossRef\]](#) [\[PubMed\]](#)
17. Kerschner, J.E.; Beste, D.J.; Conley, S.F.; Kenna, M.A.; Lee, D. Mediastinitis associated with foreign body erosion of the esophagus in children. *Int. J. Pediatr. Otorhinolaryngol.* **2001**, *59*, 89–97. [\[CrossRef\]](#)
18. Campbell, E.A.; Wilbert, C.D. Foreign Body Imaging. In *StatPearls [Internet]*; StatPearls Publishing: Treasure Island, FL, USA, 2023.
19. Garg, N.; Lee, R.N.; Pekmezaris, R.; Gupta, S. An Assessment of Management Strategies for Adult Patients with Foreign-Body Sensation in the Neck. *J. Emerg. Trauma Shock* **2021**, *14*, 28–32. [\[CrossRef\]](#)
20. Orlinsky, M.; Knittel, P.; Feit, T.; Chan, L.; Mandavia, D. The comparative accuracy of radiolucent foreign body detection using ultrasonography. *Am. J. Emerg. Med.* **2000**, *18*, 401–403. [\[CrossRef\]](#)
21. Valizadeh, S.; Pouraliakbar, H.; Kiani, L.; Safi, Y.; Alibakhshi, L. Evaluation of Visibility of Foreign Bodies in the Maxillofacial Region: Comparison of Computed Tomography, Cone Beam Computed Tomography, Ultrasound and Magnetic Resonance Imaging. *Iran. J. Radiol.* **2016**, *13*, e37265. [\[CrossRef\]](#)
22. Peterson, J.J.; Bancroft, L.W.; Kransdorf, M.J. Wooden foreign bodies: Imaging appearance. *AJR Am. J. Roentgenol.* **2002**, *178*, 557–562. [\[CrossRef\]](#) [\[PubMed\]](#)
23. Palmer, J.B.; Rudin, N.J.; Lara, G.; Crompton, A.W. Coordination of mastication and swallowing. *Dysphagia* **1992**, *7*, 187–200. [\[CrossRef\]](#) [\[PubMed\]](#)
24. Dua, K.S.; Ren, J.; Bardan, E.; Xie, P.; Shaker, R. Coordination of deglutitive glottal function and pharyngeal bolus transit during normal eating. *Gastroenterology* **1997**, *112*, 73–83. [\[CrossRef\]](#) [\[PubMed\]](#)
25. Khoo, M.J.W.; Ooi, A.S.H. Management of postreconstructive head and neck salivary fistulae: A review of current practices. *J. Plast. Reconstr. Aesthet. Surg.* **2021**, *74*, 2120–2132. [\[CrossRef\]](#)
26. Wu, E.; Huang, L.; Zhou, Y.; Zhu, X. Migratory Fish Bone in the Thyroid Gland: Case Report and Literature Review. *Case Rep. Med.* **2018**, *2018*, 7345723. [\[CrossRef\]](#)
27. Lupo, J.E.; Leuin, S.C.; Kelley, P.E. Anterior laryngofissure approach to an airway foreign body after migration into the paraglottic space. *Laryngoscope* **2011**, *121*, 2159–2161. [\[CrossRef\]](#)

28. Wong, H.T.; Tham, S.Y.; Elangkumaran, K.; Ng, W.; Sia, K.J. Lateral thyroid cartilage thyrotomy approach to an embedded paraglottic fishbone. *Ann. R. Coll. Surg. Engl.* **2017**, *99*, e1–e2. [[CrossRef](#)]
29. Alkhudher, S.; AlObaid, F.; Shafi, S. Thyroid Cartilage Window Approach to Extract a Foreign Body after Migration into the Paraglottic Space. *Case Rep. Otolaryngol.* **2018**, *2018*, 3590580. [[CrossRef](#)]
30. Megwalu, U.C. Migration of an ingested fish bone into the paraglottic space. *J. Laryngol. Otol.* **2016**, *130*, 973–974. [[CrossRef](#)]
31. Lee, J.W.; Randall, D.R.; Kuhn, M.A. Intraoperative ultrasound-guided retrieval of an extraluminal pharyngoesophageal foreign body. *Ear Nose Throat J.* **2018**, *97*, 202–207. [[CrossRef](#)]
32. Baba, S.; Takizawa, K.; Yamada, C.; Monobe, H. A submucosal esophageal fish bone foreign body surgically removed using intraoperative ultrasonography. *Am. J. Otolaryngol.* **2014**, *35*, 268–270. [[CrossRef](#)] [[PubMed](#)]
33. Sinha, R.; Jana, U.; Ghatak, S.; Biswas, G.; Saha, J.; Sen, I. Use of fluoroscopic guidance to remove a migrating esophageal foreign body. *Ear Nose Throat J.* **2015**, *94*, E30–E33. [[CrossRef](#)] [[PubMed](#)]
34. Delibas, V.; Muharremoglu, M.R.; Bal, K.K.; Alagoz, S. A rare foreign body migration: From head to neck. *Braz. J. Otorhinolaryngol.* **2022**, *88* (Suppl. 4), S223–S225. [[CrossRef](#)] [[PubMed](#)]
35. AlBilasi, T.M.; AlDhawi, L.F.; AlOlaywi, A.N.; Al Mutairy, A.S.; AlGhamdi, F.R.; Alamry, S.S.; AlZhrani, H.A. Fluoroscopy-Guided Metallic Foreign Body Removal: A Report of Three Cases and Literature Review. *Cureus* **2023**, *15*, e40462. [[CrossRef](#)]
36. Wu, X.; Wang, Y.; Sun, W.; Zhu, X. Case report: Image guidance retrieval of a foreign body in retropharyngeal space. *Front. Surg.* **2022**, *9*, 949964. [[CrossRef](#)]
37. Stoica, M.; Săftoiu, A.; Gheonea, D.I.; Dumitrescu, D.; Surlin, V. Pyogenic liver abscess caused by accidental ingestion of a wooden toothpick: Role of preoperative imaging. *J. Gastrointest. Liver Dis.* **2007**, *16*, 221–222.

Disclaimer/Publisher’s Note: The statements, opinions and data contained in all publications are solely those of the individual author(s) and contributor(s) and not of MDPI and/or the editor(s). MDPI and/or the editor(s) disclaim responsibility for any injury to people or property resulting from any ideas, methods, instructions or products referred to in the content.