

Interventional and surgical management of abdominal compartment syndrome in severe acute pancreatitis

Žilvinas Dambrauskas^{1,2}, Audrius Paršeliūnas², Almantas Maleckas², Antanas Gulbinas^{1,2},
Giedrius Barauskas², Juozas Pundzius²

¹Institute for Biomedical Research, Kaunas University of Medicine,

²Department of Surgery, Kaunas University of Medicine, Lithuania

Key words: acute pancreatitis; abdominal compartment syndrome; organ dysfunction; surgery.

Summary. *Background and objective.* Management of the abdominal compartment syndrome during severe acute pancreatitis by the open abdomen method is associated with considerable morbidity and resource utilization. Thus, the aim of this study was to evaluate the safety and efficacy of the ultrasound-guided percutaneous interventions and/or minimally invasive surgery in the treatment of abdominal compartment syndrome.

Material and methods. Forty-four patients with severe acute pancreatitis were enrolled into a prospective study and treated according to the standard management protocol. Interventional and/or surgical management of abdominal compartment syndrome was employed in 6 (13.6%) cases. In the context of this study, we assessed the feasibility and effectiveness of subcutaneous fasciotomy of the anterior m. rectus abdominis sheath, as well as the role of ultrasound-guided drainage of intra-abdominal and peripancreatic fluid collections in the management of abdominal compartment syndrome.

Results. Subcutaneous fasciotomy of the anterior m. rectus sheath and ultrasound-guided drainage of intra-abdominal and peripancreatic fluid collections seem to be safe (minor risk of bleeding or infection, closed abdomen, and easy care for the patient) and effective (resulted in a sustained decrease of intra-abdominal pressure to 13–16 mm Hg and regression of organ failures after intervention). Subcutaneous anterior m. rectus fasciotomy may appear to be beneficial in case of refractory abdominal compartment syndrome avoiding morbidity associated with the open abdomen technique.

Conclusions. Both the subcutaneous fasciotomy and ultrasound-guided drainage of intra-abdominal and/or peripancreatic fluid collections seem to be safe and effective alternatives in the management of abdominal compartment syndrome; however, prospective studies are needed to further evaluate their clinical role.

Introduction

Acute pancreatitis remains a disease with a hardly predictable clinical course and significant morbidity and mortality (1–3). Recently, the elevated intra-abdominal pressure (IAP) following the onset of acute pancreatitis (AP) has gained growing attention. It was shown that intra-abdominal hypertension (IAH) is associated with higher mortality and morbidity rates, and prolonged stay at an intensive care unit (ICU) in comparison to other patients with normal IAP (4–10). IAH has been recognized as a cause of organ dysfunction in critically ill patients, including those suffering from severe acute pancreatitis (SAP) (11–16).

The mechanisms involved in the development of abdominal compartment syndrome (ACS) include

extensive inflammatory process in the retroperitoneum, visceral edema, increased capillary permeability, hypoalbuminemia, and volume overload. ACS is defined as an increase of IAP more than 20 mm Hg in association with the occurrence of a new organ failure (4, 5, 17, 18). A previously reported incidence of ACS among patients with SAP ranges from 23 to 56%. It has been shown that early recognition and treatment of IAH and ACS result in a significant improvement in patient survival and decreased morbidity (4, 8, 10, 16, 19).

Open decompression laparotomy is an established modality in severe ACS, but the ensuing open abdomen is associated with severe morbidity and subsequent extensive abdominal wall reconstruction, unless primary fascial closure is achieved. A

Correspondence to Ž. Dambrauskas, Department of Surgery, Kaunas University of Medicine, Eivenių 2, 50009 Kaunas, Lithuania. E-mail: zilvinas.dambrauskas@gmail.com

Adresas susirašinėti: Ž. Dambrauskas, KMU Chirurgijos klinika, Eivenių 2, 50009 Kaunas
El. paštas: zilvinas.dambrauskas@gmail.com

feasibility study using a porcine model of ACS demonstrated that subcutaneous endoscopic abdominal fasciotomy appears to lower intra-abdominal pressure (IAP) and increase mesenteric blood flow. Effective treatment of ACS by subcutaneous anterior *m. rectus* fasciotomy in patient with SAP was also demonstrated by Leppaniemi et al. (20–22). In addition to the benefits of avoiding the open abdomen, leaving the skin mostly intact, and avoiding entering the peritoneal cavity, patients with ACS and severe pancreatitis could potentially benefit from sustained decompression effect. Another alternative is to employ image-guided percutaneous drainage in cases when ACS is produced by the accumulation of free fluid in the peritoneal cavity. This article describes for the first time the technique of subcutaneous anterior *m. rectus* fasciotomy and its effect on IAP in patients with SAP. The role of minimally invasive ultrasound-guided percutaneous drainage in management of ACS in SAP is also briefly discussed and illustrated.

Materials and methods

Measurement of IAP and clinical assessment of patients. The study was carried out at the Department of Surgery, Hospital of Kaunas University of Medicine, from May 2007 to February 2008. The Regional Ethics Committee approved the study (protocols No. BE-2-47 and P1-113/2005), and all patients provided written informed consent. Forty-four patients with AP were treated according to our standard management protocol and following the recent international guidelines during this period. Interventional and/or surgical management of ACS was employed in 6 (13.6%) cases when noninterventional management of ACS was not effective. One patient with diagnosed ACS died within the first hours after admission due to multiple organ failure (MOF) and shock without any interventional treatment. In the context of this study, we assessed the feasibility and effectiveness of a new decompression procedure to relieve the IAH – subcutaneous fasciotomy of the anterior *m. rectus abdominis* sheath. Although the “golden standard” procedure for the treatment of ACS is still decompression laparotomy, this procedure is associated with very high morbidity and mortality, followed by an extremely difficult postoperative care (11, 14, 19, 23–25). A search for new minimally invasive, safe, and simple procedures (alternatives for open surgery in management of ACS) has led to the development of new surgical techniques, including laparoscopic or open subcutaneous *linea alba* or *m. rectus abdominis* anterior sheath fasciotomy that still needs to be evaluated in a clinical setting.

We used a standard two-way 16-Fr Foley catheter inserted into the urinary bladder for IAP measure-

ment. The patient was placed in supine position. Twenty-five milliliters of sterile 0.9% saline were instilled, and the catheter was connected to a tube from the urine collection bag. The pubic symphysis was considered level 0, and IAP was measured in cm H₂O and then recalculated in mm Hg. IAP was measured every 24 hours during the period of three days after admission in all patients. For patients who developed IAH (IAP of more than 12 mm Hg), the conservative treatment (according to the recommendations of international experts on IAH and ACS) was initiated, and IAP was monitored every 12 hours until the normal IAP was reached and sustained at least for 24 hours. IAP was monitored every 4–6 hours in patients who developed IAH of 18 mm Hg or more until IAP normalized or ACS developed. ACS was defined as an increase of IAP more than 20 mm Hg, which is associated with deterioration or occurrence of organ failure (17, 23).

On the first day of admission, the severity of AP and presence of organ dysfunction were assessed utilizing 3 different multifactorial prognostic systems: Glasgow-Imrie score, Acute Physiology and Chronic Health Evaluation II (APACHE-II) score, and Multiorgan Dysfunction Score (MODS). Later, the severity of disease and clinical status were repeatedly reassessed using the same prognostic tools every 7 days, or when the clinical condition deteriorated and/or after interventional treatment of ACS.

Surgical technique of anterior *m. rectus* fasciotomy. Surgical interventions were performed under general anesthesia and complete muscle relaxation. IAP was measured on the table in each patient, confirming the preoperative values of IAP. Two transverse skin incisions 2–2.5 cm in length were placed in the midclavicular line on each side in the subcostal region. Another two transverse skin incisions 2–2.5 cm in length were placed 30–35 cm caudally from the costal margin (at the level of the umbilicus) and on the lateral margin of the *rectus abdominis* muscle. The subcutaneous tissue was incised; a tunnel at the lateral margin of the *rectus abdominis* muscle was bluntly dissected on both sides from the costal margin down to the pubic region. The anterior sheath of the abdominal fascia covering *rectus abdominis* muscle was divided vertically at the lateral edge of the muscle. The incision was carried out with scissors under finger control (Fig. 1). Fasciotomy extended from about 1 cm below the costal margin cranially to about 1–2 cm above the symphysis caudally. The width of the fascial diastasis measured at the incision level was 4–5 cm on both sides (approximately 8–10 cm in total). Hemostasis was achieved using bipolar forceps. The skin wounds were closed with interrupted monofilament sutures. The average operation time was 30 (SD, 7) minutes.

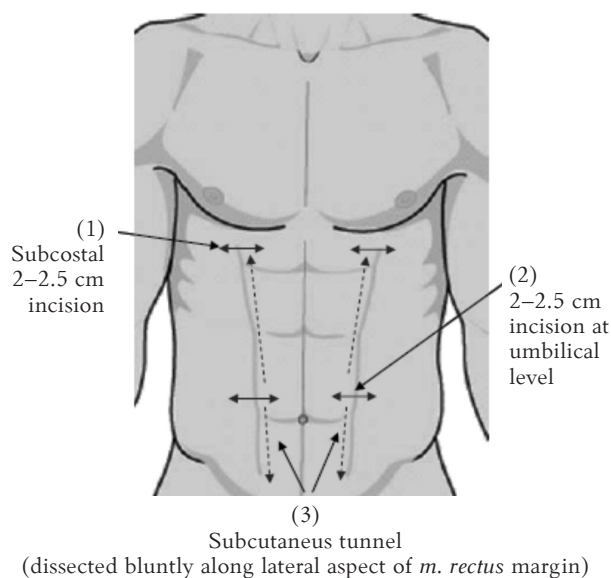


Fig. 1. Surgical technique of the anterior *m. rectus abdominis* fasciotomy

Two transverse 2–2.5 cm skin incisions in length were placed in the midclavicular line on each side in the subcostal region (1). Another two transverse 2–2.5 cm skin incisions in length were placed 30–35 cm caudally from the costal margin (at the level of the umbilicus) and on the lateral margin of the *rectus abdominis* muscle (2). The subcutaneous tissue was incised; a tunnel at the lateral margin of the *rectus abdominis* muscle was bluntly dissected on both sides from the costal margin down to the pubic region (3). The anterior sheath of the abdominal fascia covering *rectus abdominis* muscle was divided vertically at the lateral edge of the muscle with scissors. Fasciotomy extended from about 1 cm below the costal margin cranially to about 1–2 cm above the symphysis caudally. Hemostasis was achieved using bipolar forceps. The skin wounds were closed with interrupted monofilament sutures.

Ultrasound-guided drainage techniques. Minimally invasive ultrasound-guided drainage of the peritoneal cavity was performed under local anesthesia with 2% lidocaine employing the Seldinger technique. We used percutaneous nephrostomy drainage sets with 8–11 Ch catheters (Nephrofix®, B. Braun Melsungen AG, Germany) for the drainage of the peritoneal cavity and/or retroperitoneal fluid collections associated with the elevated IAP.

Statistical analysis. Statistical analysis was performed using SPSS® for Windows release 16.0 (SPSS, Chicago, Illinois, USA). The data are presented as mean (SD). For comparison between groups, Wilcoxon signed rank test was employed. Results with $P < 0.05$ were considered statistically significant.

First experience of interventional management of abdominal compartment syndrome

Use of ultrasound-guided drainage of acute fluid collections. Three patients presented with severe alcohol-induced acute pancreatitis on the second or

third days after the onset of disease (mean IAP on admission to hospital, 19.5 mm Hg). The patients were treated according to our standard management protocol. Clinical data representing the health status of patients before and after interventional treatment of IAH are presented in Table. Starting from the first day of hospital stay, monitoring of the urinary output and IAP was established on a regular basis. Contrast-enhanced computed tomography (CECT) performed on the fourth–sixth hospital admission day demonstrated a pancreatic necrosis volume of >50% in all cases. The diagnosis of ACS was established based on the recorded IAH of more than 21 mm Hg and development of new organ failure (cardiovascular, renal, and respiratory dysfunction) on the third–fourth day of hospital stay. Ultrasound examination revealed extensive pancreatic and peripancreatic tissue edema, and large collections of free fluid in the abdomen. Ultrasound-guided needle aspiration or drainage of free fluid (approximately 600–1500 mL) from the abdominal cavity was performed. This resulted in the decrease of IAP to 13–16 mm Hg and regression of organ failures. Monitoring of the IAP via the bladder catheter showed steady grade 2 hypertension in the course of the next week. As the overall condition worsened and IAP increased up to 22–25 mm Hg on the 11th–15th day of hospital stay, an ultrasound-guided drainage of fluid collection in lesser sac or free abdominal cavity was performed repeatedly. This procedure resulted in a temporary improvement of patient's condition and decrease of IAP to 12–16 mm Hg. Fig. 2 depicts the strategy of interventional management of intraperitoneal fluid collections associated with development of ACS in the early phase of AP. On the 20th–23rd day of hospital stay, the patients were diagnosed to have ACS based on presence of newly developing organ failures, demand for more aggressive ventilation parameters, and IAP of 22–25 mm Hg. Ultrasound-guided fine-needle aspiration (FNA) proved the presence of peripancreatic infection in all 3 cases. Laparotomy, débridement of necrotizing tissues, and drainage of remaining retroperitoneal and intraperitoneal fluid collections were performed within 24 hours from diagnosis of ACS. A closure of the abdominal cavity resulted in grade 1 IAH (IAP of 12–14 mm Hg) for the next few days. General condition of two patients gradually improved following the surgery, and they were discharged from hospital on the 48th and 98th day from the admission. Despite the aggressive treatment, septic shock and progression of MOF resulted in death of the third patient.

Use of subcutaneous anterior rectus abdominis muscle fasciotomy. Two male patients with severe alcohol-induced acute pancreatitis were admitted to the ICU on the first and third day after onset of pain because of evolving respiratory and renal failure, se-

Table. Clinical data before and after interventional treatment of intra-abdominal hypertension

Clinical data	Before treatment	After treatment
<i>Group of ultrasound-guided drainage:</i>		
Age, years	–	55.5 (10.1)
BMI, kg/m ²	–	31.6 (3.5)
APACHE II, score	10.0 (2.6)	8.3 (1.6)
Glasgow-Imrie, score	5.3 (0.6)	5.0 (0.3)
MODS, score	3.3 (0.6)	2.3 (1.3)
IAP, mm Hg	22.6 (2.4)	12.6 (0.7)
<i>Group of subcutaneous anterior rectus abdominis muscle fasciotomy:</i>		
Age, years	–	49.5 (15.0)
BMI, kg/m ²	–	34.6 (8.0)
APACHE II, score	12.3 (1.5)	10.6 (1.6)
Glasgow-Imrie, score	5.5 (0.8)	5.3 (1.6)
MODS, score	6.0 (1.4)	5.3 (0.6)
IAP, mm Hg	25.0 (4.0)	16.3 (1.3)

Data are given as mean (SD).

BMI, body mass index; APACHE II, Acute Physiology and Chronic Health Evaluation II; MODS, Multiorgan Dysfunction Score; IAP, intra-abdominal pressure.

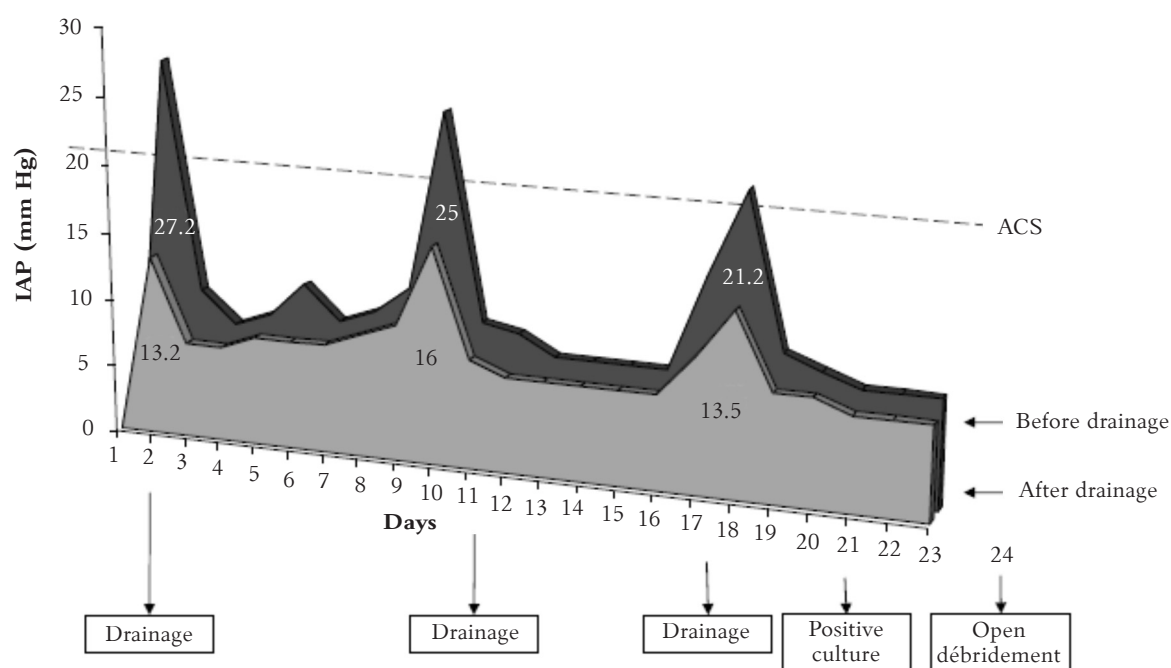


Fig. 2. Repeated ultrasound-guided drainage in management of abdominal compartment syndrome (ACS) in early phase of severe acute pancreatitis

Management of ACS by means of ultrasound-guided drainage of acute intraabdominal fluid collections in the early phase of acute pancreatitis is effective, safe, and associated with minimal morbidity. It results in sustained normalization of intra-abdominal pressure (IAP) in the period of several days, allows for the early diagnosis of infected pancreatic necrosis, and for optimal timing of the surgical débridement.

vere hypovolemia (mean IAP on admission, 22 mm Hg). Clinical data representing the health status of patients before and after interventional treatment of IAH are presented in Table. CECT performed after admission demonstrated an extensive retroperitoneal edema and possible pancreatic necrosis of >50% without presence of any acute fluid collections in the abdomen. The diagnosis of ACS was established

based on the recorded IAH, and progression of multiple organ failure within the first hours of the disease. In both cases, subcutaneous fasciotomy of the anterior *m. rectus abdominis* sheath was performed to relieve IAH. Surgery was performed within 8 hours after admission and resulted in an immediate decrease of IAP to 15–16 mm Hg, which remained at this level for the next 24–48 hours. A decrease

in IAH was also associated with improvement of general condition, improved ventilation parameters, increased urinary output, and decreased dosage of vasopressors. Despite the effective control of IAH in both cases, MOF, shock, and systemic inflammatory response syndrome (SIRS) persisted, and patients died on the second and seventh day after surgery.

A 36-year-old male with severe alcohol-induced acute pancreatitis was admitted to the ICU on the first day after the onset of pain because of evolving respiratory and renal failure and severe hypovolemia (BMI, 26 kg/m²; APACHE II, 12 points; Glasgow-Imrie, 4 points; MODS, 5 points; and IAP, 28 mm Hg on admission). The diagnosis of ACS was established. CECT demonstrated an extensive retroperitoneal edema, 50% pancreatic necrosis, and no acute fluid collections. Subcutaneous anterior rectus muscle fasciotomy relieved the IAH. Surgery was performed within 8 hours after admission resulting in a decrease of IAP from 30 to 16 mm Hg. Grade 2 IAH was sustained for the next 24 hours. Within the next 72 hours, the patient's condition improved significantly; cardiovascular and metabolic symptoms subsided. As the IAP continued to normalize, the patient had an uneventful recovery within 28 days from the onset of the disease.

Discussion

Our study confirmed the earlier published observations that SAP is a risk factor for development of IAH and ACS. The incidence of IAH and ACS in our study was similar to that observed in other studies and, as expected, was associated with a higher incidence of MOF and higher mortality rates.

An early diagnosis and proper management of ACS is crucial (8, 9, 16, 26). Clinical assessment is of little value in selecting patients that are likely to suffer from ACS, while the measurement and monitoring of IAP via urinary bladder catheter is a simple procedure, which requires virtually no technical skills and fewer resources (17, 23, 27). However, the management of the ACS is an extremely complex task. Conservative management, including appropriate analgesia, sedation, evacuation of intraluminal content (nasogastric, rectal decompression, prokinetic agents), appropriate body positioning provide only temporary relief as the evolving visceral, peripancreatic, and retroperitoneal tissue edema and inflammation result in the relapse of IAH and ACS within hours or days. Furthermore, it is hardly possible to maintain a negative fluid balance in patients with SAP, presenting with SIRS, shock, impaired renal and visceral perfusion, and evolving organ insufficiency (17, 23, 28). Nevertheless, we recommend utilizing all the noninvasive modalities to preserve the adequate blood supply and func-

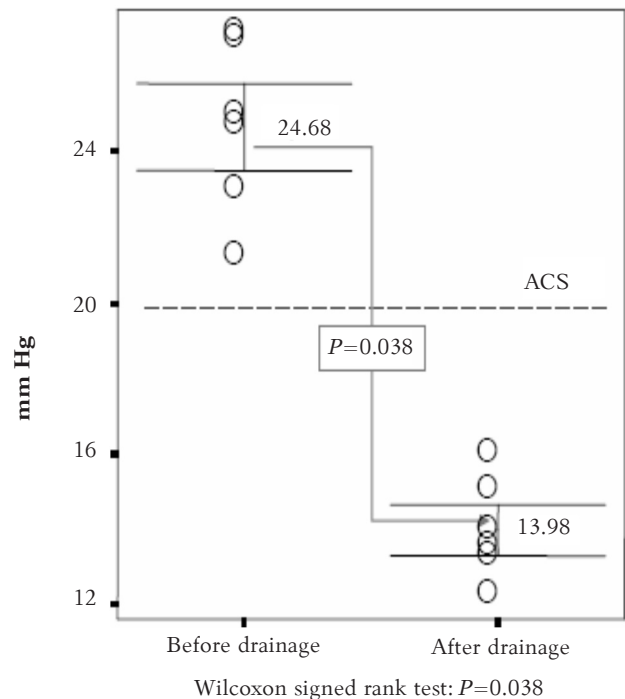


Fig. 3. Effects of ultrasound-guided drainage in management of abdominal compartment syndrome (ACS)

Ultrasound-guided drainage of acute intraabdominal fluid collections proved to be effective in controlling the intra-abdominal hypertension and decreased intra-abdominal pressure down to theoretically safe margins.

tion of vitally important systems, thus postponing or avoiding the interventional management of ACS in some patients. Minimally invasive management of ACS by means of ultrasound-guided drainage of acute intraabdominal fluid collections proved to be effective and safe (Fig. 3). Although, it provided only a temporary relief in some cases, it was not associated with any significant morbidity. Besides, percutaneous ultrasound-guided FNA and drainage allowed for the early diagnosis of infected pancreatic necrosis and for optimal timing of the surgical débridement. In the reported series, the subcutaneous anterior *m. rectus* fasciotomy was a surgical procedure of choice for the management of ACS during the first days of the disease when conservative management failed and there were no substantial acute fluid collections. The procedure is safe (minor risk of bleeding or infection, closed abdomen, easy care for the patient) and effective (immediately relieves IAP down to a theoretically safe level and helps to maintain it for days). We have not observed any negative clinically significant effect of this procedure. Two of our patients died within the first week in spite of decreased intra-abdominal pressure to grade 1–2. Another patient, however, benefited from the early subcutaneous fasciotomy, as this procedure was associated with the normalization of IAP and ame-

loration of respiratory and renal failure. The effectiveness of the above procedure seems to be similar to that of decompression laparotomy ("open abdomen") and carries similar mortality rates (reported range is 50–75%) but with lower morbidity in those who are likely to survive. There is still no evidence to recommend subcutaneous anterior *rectus abdominis* muscle fasciotomy as a definite management option in SAP. Larger prospective studies analyzing the value of subcutaneous anterior *m. rectus* fasciotomy in the management of refractory ACS early in the course of AP are needed.

Conclusions

Early diagnosis and management of abdominal compartment syndrome has a potential to prevent or ameliorate organ failure. Image-guided drainage is a procedure of choice when abdominal compartment syndrome develops due to acute fluid collections. Subcutaneous anterior *m. rectus* fasciotomy may appear beneficial in case of refractory abdominal compartment syndrome avoiding morbidity associated with the open abdomen technique; however, prospective studies are needed to further evaluate its clinical role.

Sergančių sunkiu ūminiu pankreatitu intervencinis ir chirurginis abdominalinės ertmės sindromo gydymas

Žilvinas Dambrauskas^{1, 2}, Audrius Paršeliūnas², Almantas Maleckas², Antanas Gulbinas^{1, 2}, Giedrius Barauskas², Juozas Pundzius²

¹Kauno medicinos universiteto Biomedicinių tyrimų institutas, ²Kauno medicinos universiteto Chirurgijos klinika

Raktažodžiai: ūminis pankreatitas, abdominalinės ertmės sindromas, minimaliai invazinė chirurgija.

Santrauka. *Tyrimo tikslas.* Sergant sunkiu ūminiu pankreatitu, abdominalinės ertmės sindromas, pasireiškia gana dažnai ir yra susijęs su sisteminiu uždegiminio atsako sindromu bei dideliu pacientų mirštamumu. Abdominalinio sindromo gydymas, atliekant laparotomiją ir paliekant „atvirą“ pilvo ertmę, nėra optimalus chirurginio gydymo būdas, nes ši intervencija susijusi su dideliu pooperacinių komplikacijų dažniu, sudėtinga paciento priežiūra pooperaciniu laikotarpiu. Šio tyrimo tikslas – įvertinti perkutaninio skysčio sankaupų drenažo, kontroliuojant ultragarsu, ir minimaliai invazinių chirurgijos metodų saugumą ir efektyvumą, pasireiškus abdominalinės ertmės sindromui.

Tyrimo medžiaga ir metodai. Į perspektyvų tyrimą įtraukti 44 pacientai, sergantys sunkiu ūminiu pankreatitu, iš kurių 6 (13,6 proc.) pacientams atliktos minimaliai invazinės intervencijos arba operacijos gydant abdominalinės ertmės sindromą. Tyrimo metu įvertintos techninės galimybės atlikti abipusę poodinę pilvo tiesių raumenų makšties priekinio lapelio fasciotomiją, panaudojant minimaliai invazinę chirurginę metodiką, jos efektyvumas ir saugumas. Taip pat įvertinta skysčio sankaupų pilvaplėvės ertmėje ir užpilvaplėviniame tarpe drenažo, kontroliuojant ultragarsu, reikšmė gydant abdominalinės ertmės sindromą ūminio pankreatito metu.

Rezultatai. Tiek abipusę poodinę pilvo tiesių raumenų makšties priekinio lapelio fasciotomiją, tiek perkutaninis peripankreatinių skysčio sankaupų drenažas, kontroliuojant ultragarsu, yra saugios (nedidelė kraujavimo ir infekcinių komplikacijų rizika, uždara pilvaplėvės ertmė, nesudėtinga paciento priežiūra) ir efektyvios abdominalinės ertmės sindromo gydymo alternatyvos (intraabdominalinis spaudimas sumažėja iki 13–16 mmHg, regresuoja dauginio organų nepakankamumo reiškiniai).

Išvados. Poodinė pilvo tiesiojo raumens makšties priekinio lapelio fasciotomija ir perkutaninis skysčio sankaupų drenažas, kontroliuojant ultragarsu, yra saugios ir efektyvios abdominalinės ertmės sindromo gydymo alternatyvos, tačiau reikia daugiau perspektyvinių tyrimų siekiant įvertinti šių minimaliai invazinių chirurginių intervencijų klinikinę reikšmę.

References

- Gravante G, Garcea G, Ong SL, Metcalfe MS, Berry DP, Lloyd DM, et al. Prediction of mortality in acute pancreatitis: a systematic review of the published evidence. *Pancreatology* 2009;9:601–14.
- Muddana V, Whitcomb DC, Papachristou GI. Current management and novel insights in acute pancreatitis. *Expert Rev Gastroenterol Hepatol* 2009;3:435–44.
- Dambrauskas Z, Giese N, Gulbinas A, Giese T, Berberat PO, Pundzius J, et al. Different profiles of cytokine expression during mild and severe acute pancreatitis. *World J Gastroenterol* 2010;16:1845–53.
- Al Bahrani AZ, Abid GH, Holt A, McCloy RF, Benson J, Eddleston J, et al. Clinical relevance of intra-abdominal hypertension in patients with severe acute pancreatitis. *Pancreas* 2008;36:39–43.
- Chen H, Li F, Sun JB, Jia JG. Abdominal compartment syndrome in patients with severe acute pancreatitis in early stage. *World J Gastroenterol* 2008;14:3541–8.
- Dambrauskas Z, Parseliunas A, Gulbinas A, Pundzius J, Barauskas G. Early recognition of abdominal compartment

- syndrome in patients with acute pancreatitis. *World J Gastroenterol* 2009;15:717-21.
7. De Waele JJ, Hoste E, Blot SI, Decruyenaere J, Colardyn F. Intra-abdominal hypertension in patients with severe acute pancreatitis. *Crit Care* 2005;9:R452-7.
 8. Leppaniemi A, Johansson K, De Waele JJ. Abdominal compartment syndrome and acute pancreatitis. *Acta Clin Belg Suppl* 2007;131-5.
 9. Rosas JM, Soto SN, Aracil JS, Cladera PR, Borlan RH, Sanchez AV, et al. Intra-abdominal pressure as a marker of severity in acute pancreatitis. *Surgery* 2007;141:173-8.
 10. Zhang WF, Ni YL, Cai L, Li T, Fang XL, Zhang YT. Intra-abdominal pressure monitoring in predicting outcome of patients with severe acute pancreatitis. *Hepatobiliary Pancreat Dis Int* 2007;6:420-3.
 11. Balogh Z, McKinley BA, Cocanour CS, Kozar RA, Holcomb JB, Ware DN, et al. Secondary abdominal compartment syndrome is an elusive early complication of traumatic shock resuscitation. *Am J Surg* 2002;184:538-43.
 12. Malbrain ML, Chiumello D, Pelosi P, Wilmer A, Brienza N, Malcangi V, et al. Prevalence of intra-abdominal hypertension in critically ill patients: a multicentre epidemiological study. *Intensive Care Med* 2004;30:822-9.
 13. Malbrain ML, Chiumello D, Pelosi P, Bihari D, Innes R, Ranieri VM, et al. Incidence and prognosis of intraabdominal hypertension in a mixed population of critically ill patients: a multiple-center epidemiological study. *Crit Care Med* 2005;33:315-22.
 14. Carlotti AP, Carvalho WB. Abdominal compartment syndrome: a review. *Pediatr Crit Care Med* 2009;10:115-20.
 15. Šerpytis M, Ivaškevičius J. Intraabdominalinė hipertenzija ir dauginis organų disfunkcijos sindromas. (Intra-abdominal hypertension and multiple organ dysfunction syndrome.) *Medicina (Kaunas)* 2005;41:903-9.
 16. Cheatham ML, Safcsak K. Is the evolving management of intra-abdominal hypertension and abdominal compartment syndrome improving survival? *Crit Care Med* 2010;38:402-7.
 17. Malbrain ML, Cheatham ML, Kirkpatrick A, Sugrue M, Parr M, De Waele J, et al. Results from the International Conference of Experts on Intra-abdominal Hypertension and Abdominal Compartment Syndrome. I. Definitions. *Intensive Care Med* 2006;32:1722-32.
 18. Zhang XP, Ye Q, Jiang XG, Ma ML, Zhu FB, Zhang RP, et al. Preparation method of an ideal model of multiple organ injury of rat with severe acute pancreatitis. *World J Gastroenterol* 2007;13:4566-73.
 19. De Waele JJ, Cheatham ML, Malbrain ML, Kirkpatrick AW, Sugrue M, Balogh Z, et al. Recommendations for research from the International Conference of Experts on Intra-abdominal Hypertension and Abdominal Compartment Syndrome. *Acta Clin Belg* 2009;64:203-9.
 20. Leppaniemi AK, Hienonen PA, Siren JE, Kuitunen AH, Lindstrom OK, Kemppainen EA. Treatment of abdominal compartment syndrome with subcutaneous anterior abdominal fasciotomy in severe acute pancreatitis. *World J Surg* 2006;30:1922-4.
 21. Dakin GF, Nahouraii R, Gentileschi P, Kini S, Gagner M. Subcutaneous endoscopic fasciotomy in a porcine model of abdominal compartment syndrome: a feasibility study. *J Laparoendosc Adv Surg Tech A* 2004;14:339-44.
 22. Duchesne JC, Howell MP, Eriksen C, Wahl GM, Rennie KV, Hastings PE, et al. Linea alba fasciotomy: a novel alternative in trauma patients with secondary abdominal compartment syndrome. *Am Surg* 2010;76:312-6.
 23. Cheatham ML, Malbrain ML, Kirkpatrick A, Sugrue M, Parr M, De Waele J, et al. Results from the International Conference of Experts on Intra-abdominal Hypertension and Abdominal Compartment Syndrome. II. Recommendations. *Intensive Care Med* 2007;33:951-62.
 24. Cheatham ML, Fowler J, Pappas P. Subcutaneous linea alba fasciotomy: a less morbid treatment for abdominal compartment syndrome. *Am Surg* 2008;74:746-9.
 25. Malbrain ML, De laet IE, De Waele JJ. IAH/ACS: the rationale for surveillance. *World J Surg* 2009;33:1110-5.
 26. Buter A, Imrie CW, Carter CR, Evans S, McKay CJ. Dynamic nature of early organ dysfunction determines outcome in acute pancreatitis. *Br J Surg* 2002;89:298-302.
 27. Kirkpatrick AW, Brenneman FD, McLean RF, Rapanos T, Boulanger BR. Is clinical examination an accurate indicator of raised intra-abdominal pressure in critically injured patients? *Can J Surg* 2000;43:207-11.
 28. Wilmer A. ICU management of severe acute pancreatitis. *Eur J Intern Med* 2004;15:274-80.

Received 2 February 2009, accepted 6 April 2010
Straipsnis gautas 2009 02 02, priimtas 2010 04 06