

Supplementary Materials

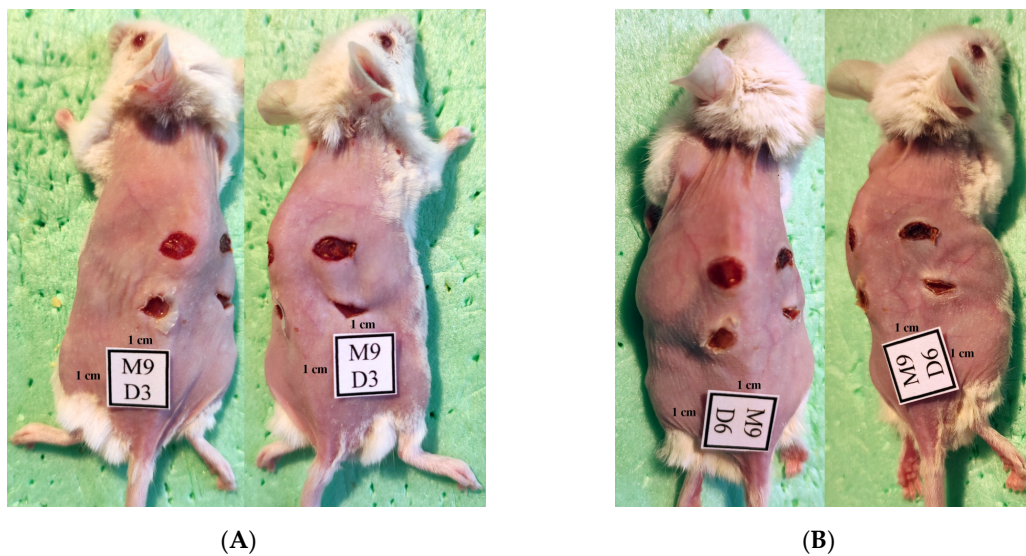


Figure S1. Digital imaging of the wound areas after D3 (A) and D6 (B) treatment.