

Supplementary Materials: Peroxisome Proliferator-Activated Receptor γ Expression is Inversely Associated with Macroscopic Vascular Invasion in Human Hepatocellular Carcinoma

Hui-Tzu Hsu, Ming-Ta Sung, Chih-Chun Lee, Yin-Ju Kuo, Chin-Wen Chi, Hsin-Chen Lee and Cheng-Yuan Hsia

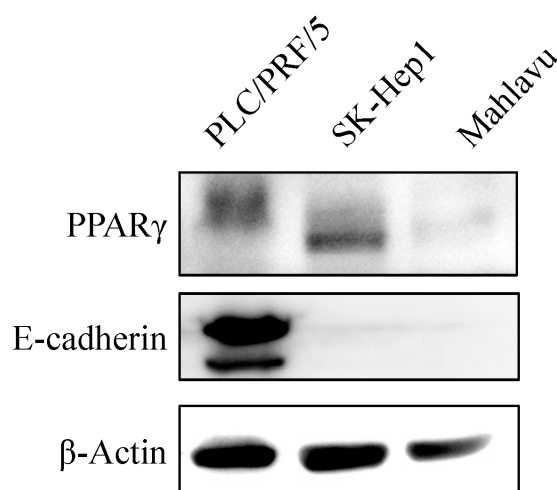


Figure S1. Endogenous peroxisome proliferator-activated receptor γ (PPAR γ) and E-cadherin expression in different hepatocellular carcinoma (HCC) cell lines. Western blot was used to detect endogenous PPAR γ and E-cadherin expression in PLC/PRF/5, SK-Hep1, and Mahlavu HCC cell lines.

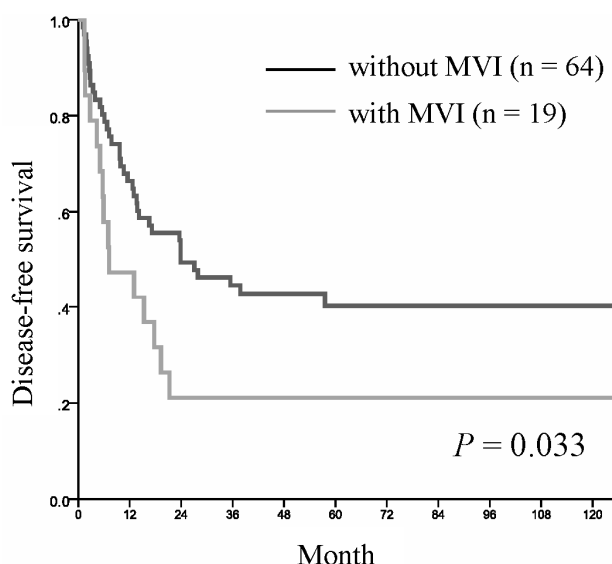


Figure S2. The 5-year disease-free survival (DFS) curves of patients underwent curative liver resection for HCC. Kaplan-Meier curves for DFS according to with ($n = 19$) or without ($n = 64$) macroscopic vascular invasion (MVI) in HCC patients.

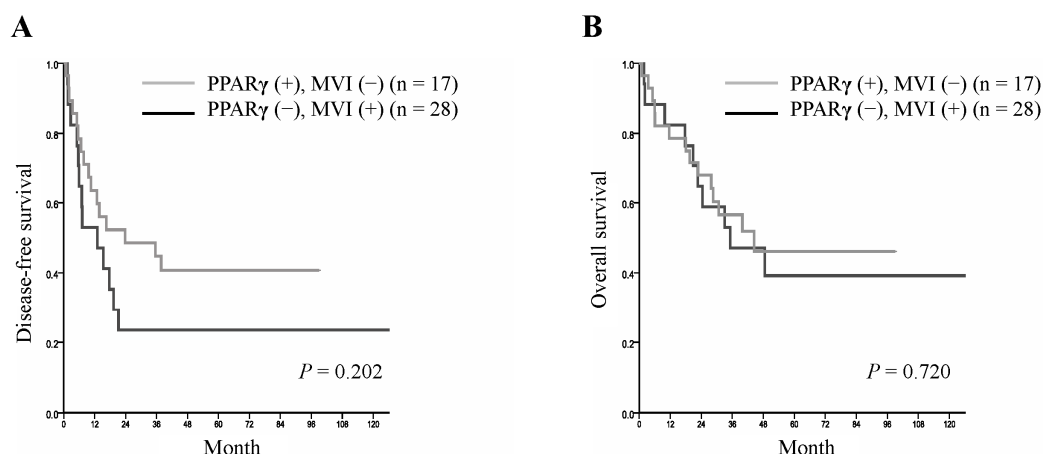


Figure S3. The 5-year disease-free survival (DFS) and overall survival (OS) analyses of HCC patients with or without MVI according to PPAR γ expression. **(A)** Kaplan–Meier curves for DFS according to patients with high PPAR γ expression and without macroscopic vascular invasion (MVI) ($n = 17$) and patients with low PPAR γ expression and with MVI ($n = 28$); **(B)** Kaplan–Meier curves for OS according to patients with high PPAR γ expression and without MVI ($n = 17$) and patients with low PPAR γ expression and with MVI ($n = 28$).

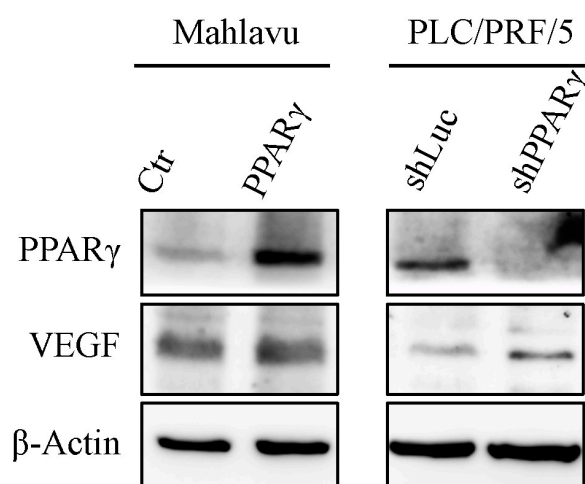


Figure S4. Vascular endothelial growth factor (VEGF) expression in PPAR γ -overexpressed and PPAR γ knockdown HCC cells. Western blot was used to examine VEGF expression in Mahlavu-ctr, Mahlavu-PPAR γ , PLC/PRF/5-shLuc, and PLC/PRF/5-shPPAR γ cells.